



Edited since  
1922

P O L I S H G Y N E C O L O G Y

# GINEKOLOGIA POLSKA

no **8**/vol **91**/2020

ORGAN POLSKIEGO TOWARZYSTWA GINEKOLOGÓW I POŁOŻNIKÓW  
THE OFFICIAL JOURNAL OF THE POLISH SOCIETY OF GYNECOLOGISTS AND OBSTETRICIANS

IF: **0.941**, MNiSW: **40**

## ORIGINAL PAPERS

TLR family gene expression in relation to the HIF1 $\alpha$  and the VEGFR pathway activation in endometrial cancer

Katarzyna M. Wojcik-Krowiranda, Ewa Forma, Andrzej Bienkiewicz, Lukasz Cwonda, Joanna Wronska-Stefaniak, Magdalena Brys

**439**

Ultrasound guided percutaneous radiofrequency thermal ablation of symptomatic uterine fibroids — results from a single center and 52 weeks of follow up

Gökhan Yüce, Aybuke Tayarar, Hüseyin Levent Keskin, Birgül Genç, Murat Canyigit

**447**

Challenges on the morbidly obese endometrial cancer surgery: Laparotomy or laparoscopy, lymphadenectomy or no lymphadenectomy?

İbrahim Ferhat Urunsak, Ghanim Khatib, Mehmet Ali Vardar, Ahmet Baris Guzel, Umrans Kucukgoz-Gulec, Sevtap Seyfettinoğlu

**453**

The association between aberrant right subclavian artery and trisomy 21 in a tertiary center in Turkey

Mete Sucu, Mehmet Ozsurmelil, Erol Arslan, Cansun Demir, Cüneyt Evrücke

**460**

The association of the amniotic fluid index (AFI) with perinatal fetal and maternal outcomes in pregnancies complicated by preterm premature rupture of membranes (PPROM)

Taner Günay, Gamze Erdem, Reyhan Ayaz Bilir, Meryem Hocaoglu, Ozkan Ozdamar, Abdulkadir Turgut

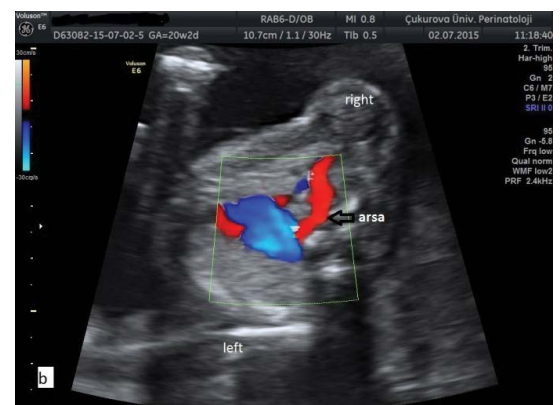**465**

## REVIEW PAPER

Ophthalmological problems in pregnancy — a review

Anna Rzeszotarska, Justyna Szczapa-Jagustyn, Jaroslaw Kociecki

**473**



ISSN 0017-0011

# III FORUM GINEKOLOGII I PERINATOLOGII PRAKTYCZNEJ

## STANDARDY POSTĘPOWANIA W POŁOŻNICTWIE I GINEKOLOGII

Przewodniczący Komitetu Naukowego:  
prof. dr hab. n. med. Piotr Sieroszewski



Łódź, 14–16 stycznia 2021 roku, Hotel DoubleTree by Hilton




Zapraszamy serdecznie na naszego Facebooka!  
[www.facebook.com/FGiPP](http://www.facebook.com/FGiPP)

Szczegóły oraz rejestracja na stronie internetowej:

 [www.forumginekologii.viamedica.pl](http://www.forumginekologii.viamedica.pl)

Kontakt w sprawie uczestnictwa:

 [forumginekologii@viamedica.pl](mailto:forumginekologii@viamedica.pl)

 tel.: (58) 320 94 94

PATRONAT



PARTNER



PATRONAT MEDIALNY



ORGANIZATOR



Konferencja jest skierowana do wszystkich osób zainteresowanych tematyką. Sesje satelitarne firm farmaceutycznych, sesje firm farmaceutycznych oraz wystawy firm farmaceutycznych są skierowane tylko do osób uprawnionych do wystawiania recept lub osób prowadzących obrót produktami leczniczymi — podstawa prawna: Ustawa z dnia 6 września 2001 r. Prawo farmaceutyczne (Dz. U. z 2017 r. poz. 2211, z późn. zm.).



P O L I S H G Y N E C O L O G Y

# GINEKOLOGIA POLSKA

ORGAN POLSKIEGO TOWARZYSTWA GINEKOLOGÓW I POŁOŻNIKÓW

THE OFFICIAL JOURNAL OF THE POLISH SOCIETY OF GYNECOLOGISTS AND OBSTETRICIANS ISSN 0017-0011

## EDITOR-IN-CHIEF

Rafał Stojko (Katowice, Poland)

## VICE EDITOR-IN-CHIEF

Agnieszka Droszdol-Cop (Katowice, Poland)

## SECTION EDITORS

### GYNECOLOGY

Michał Pomorski (Wrocław, Poland)

### BASIC SCIENCE SECTION

Paweł Basta (Kraków, Poland)

### PERINATOLOGY

Wojciech Cnota (Katowice, Poland)

## PUBLISHER EDITOR

Karolina Klimek (Gdańsk, Poland)

## EDITORIAL ADVISORY BOARD

Grzegorz H. Bręborowicz (Poznań, Poland)

Zana Bumbuliene (Vilnius, Lithuania)

Gian Carlo di Renzo (Perugia, Italy)

Krzysztof Drews (Poznań, Poland)

Dan Farine (Ontario, Canada)

Sonia Grover (Melbourne, Australia)

Moshe Hod (Tel-Aviv, Israel)

Grzegorz Jakiel (Warszawa, Poland)

Jacques Jani (Brussels, Belgium)

Agata Karowicz-Bilińska (Łódź, Poland)

Jan Kotarski (Lublin, Poland)

Kypros Nicolaides (London, United Kingdom)

Zuzana Niznanska (Bratislava, Slovakia)

Przemysław Oszukowski (Łódź, Poland)

Tomasz Paszkowski (Lublin, Poland)

Ritsuko K. Pooh (Osaka, Japan)

Krzysztof Preis (Gdańsk, Poland)

Joseph G. Schenker (Jerusalem, Israel)

Jim G. Thornton (Nottingham, United Kingdom)

Miroslaw Wielgoś (Warszawa, Poland)

Sławomir Wołczyński (Białystok, Poland)

Paul Wood (Cambridge, United Kingdom)

Mariusz Zimmer (Wrocław, Poland)

Paolo Zola (Turin, Italy)

**Ginekologia Polska** is published monthly, twelve volumes a year, by VM Media sp. z o.o. VM Group sp.k.,

73 Świętokrzyska St, 80-180 Gdańsk, Poland, phone: (+48 58) 320 94 94, fax: (+48 58) 320 94 60,

e-mail: redakcja@viamedica.pl, marketing@viamedica.pl, <http://www.viamedica.pl>

**Editorial office address:** Woman's Health Institute, School of Health Sciences, Medical University of Silesia in Katowice, 12 Medyków St, 40-752 Katowice, e-mail: [ginpol@viamedica.pl](mailto:ginpol@viamedica.pl)

**Indexed in:** CrossRef, DOAJ, Index Copernicus, Ministry of Science and Higher Education (40), POL-Index, Polish Medical Bibliography, PubMed, Science Citation Index Expanded (0.941), Scimago Journal Rank, Scopus, Ulrich's Periodicals Directory

**Advertising.** For details on media opportunities within this journal please contact the advertising sales department, 73 Świętokrzyska St, 80-180 Gdańsk, Poland, phone: (+48 58) 320 94 94, e-mail: [marketing@viamedica.pl](mailto:marketing@viamedica.pl)

**Subscription.** Printed institutional subscription — 12 issues for 300 EUR. More details at: [https://journals.viamedica.pl/ginekologia\\_polska/user/subscriptions](https://journals.viamedica.pl/ginekologia_polska/user/subscriptions)

The Editors accept no responsibility for the advertisement contents.

Manuscripts should be submitted using online submission system only.

All rights reserved, including translation into foreign languages. No part of this periodical, either text or illustration, may be used in any form whatsoever. It is particularly forbidden for any part of this material to be copied or translated into a mechanical or electronic language and also to be recorded in whatever form, stored in any kind of retrieval system or transmitted, whether in an electronic or mechanical form or with the aid of photocopying, microfilm, recording, scanning or in any other form, without the prior written permission of the publisher. The rights of the publisher are protected by national copyright laws and by international conventions, and their violation will be punishable by penal sanctions.

Editorial policies and author guidelines are published on journal website: [www.journals.viamedica.pl/ginekologia\\_polska](http://www.journals.viamedica.pl/ginekologia_polska)

Legal note: [www.journals.viamedica.pl/ginekologia\\_polska/about/legalNote](http://www.journals.viamedica.pl/ginekologia_polska/about/legalNote)



© Via Medica 2020



19-0202.008.001

# RAK PIERSI 2020

## Aktualne wytyczne postępowania diagnostyczno–terapeutycznego PTOK

Przewodniczący Komitetu Naukowego:  
prof. dr hab. n. med. Piotr Wysocki  
prof. dr hab. n. med. Maciej Krzakowski



VIRTUAL MEETING

**7.10.2020 r.**



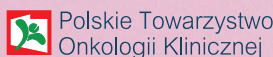
VIRTUAL MEETING

**14.10.2020 r.**

Szczegółowe informacje  
i rejestracja na stronie internetowej:

[www.rakpiersiptok.viamedica.pl](http://www.rakpiersiptok.viamedica.pl)

PATRONAT



ORGANIZATOR



PATRONAT MEDIALNY



PARTNER



*Virtual Meeting* jest skierowany tylko do osób uprawnionych do wystawiania recept lub osób prowadzących obrót produktami leczniczymi — podstawa prawna: Ustawa z dnia 6 września 2001 r. Prawo farmaceutyczne (t. j. Dz.U. z 2019 r. poz. 499).



19-0491.001.011



# GINEKOLOGIA POLSKA

ORGAN POLSKIEGO TOWARZYSTWA GINEKOLOGÓW I POŁOŻNIKÓW  
THE OFFICIAL JOURNAL OF THE POLISH SOCIETY OF GYNECOLOGISTS AND OBSTETRICIANS

## CONTENTS

### ORIGINAL PAPERS GYNECOLOGY

**TLR family gene expression in relation to the HIF1 $\alpha$  and the VEGFR pathway activation in endometrial cancer**  
Katarzyna M. Wojcik-Krowiranda, Ewa Forma, Andrzej Bienkiewicz,  
Lukasz Cwonda, Joanna Wronska-Stefaniak, Magdalena Brys ..... 439

**Ultrasound guided percutaneous radiofrequency thermal ablation of symptomatic uterine fibroids — results from a single center and 52 weeks of follow up**  
Gökhan Yüce, Aybuke Tayarar, Hüseyin Levent Keskin, Birgül Genç, Murat Canyigit ..... 447

**Challenges on the morbidly obese endometrial cancer surgery: Laparotomy or laparoscopy, lymphadenectomy or no lymphadenectomy?**  
İbrahim Ferhat Urunsak, Ghanim Khatib, Mehmet Ali Vardar, Ahmet Baris Guzel,  
Umran Kucukgoz-Gulec, Sevtaç Seyfettinoğlu ..... 453

### ORIGINAL PAPERS OBSTETRICS

**The association between aberrant right subclavian artery and trisomy 21 in a tertiary center in Turkey**  
Mete Sucu, Mehmet Ozsurmelil, Erol Arslan, Cansun Demir, Cüneyt Evrücke ..... 460

**The association of the amniotic fluid index (AFI) with perinatal fetal and maternal outcomes in pregnancies complicated by preterm premature rupture of membranes (PPROM)**  
Taner Günay, Gamze Erdem, Reyhan Ayaz Bilir, Meryem Hocaoglu, Ozkan Ozdamar, Abdulkadir Turgut ..... 465

### REVIEW PAPER OBSTETRICS

**Ophthalmological problems in pregnancy — a review**  
Anna Rzeszotarska, Justyna Szczapa-Jagustyn, Jarosław Kociecki ..... 473

### CLINICAL VIGNETTES

**Interstitial ectopic pregnancy following ipsilateral salpingectomy**  
Dariusz Piecha, Dagmara Pluta, Patrycja Pas, Joanna Plonka, Karolina Kowalczyk ..... 478

<b>Performance of portable handheld ultrasound system in fetal therapy</b>	
Anna Szczepkowska, Michal Lipa, Przemyslaw Kosinski, Mirosław Wielgos .....	480

## **RECOMMENDATIONS**

### **Recommendations of the Group of Experts of the Polish Society of Gynecologists and Obstetricians regarding abnormal uterine bleeding in adolescents**

Agnieszka Droszdzol-Cop, Violetta Skrzypulec-Plinta, Lidia Hinrle, Anna Fuchs, Iwona Joanna Czech, Grazyna Jarzabek-Bielecka .....	482
---	-----

### **Recommendations of the Expert Group of the Polish Society of Gynecologists and Obstetricians regarding gynecological examination and treatment of a minor during the SARS-CoV-2 pandemic**

Agnieszka Droszdzol-Cop, Anna Fuchs, Agnieszka Dulcka, Violetta Skrzypulec-Plinta .....	488
---	-----

### **Practice guidelines of the Polish Society of Gynecologists and Obstetricians — Ultrasound Section for ultrasound screening in uncomplicated pregnancy — 2020**

Dariusz Borowski, Marek Pietryga, Pawel Basta, Wojciech Cnota, Bartosz Czuba, Mariusz Dubiel, Tomasz Fuchs, Hubert Huras, Rafal Iciek, Renata Jaczynska, Piotr Kaczmarek, Przemyslaw Kosinski, Sebastian Kwiatkowski, Agnieszka Nocun, Michal Pomorski, Mariola Ropacka-Lesiak, Magda Rybak-Krzyszowska, Piotr Sieroszewski, Piotr Wegrzyn, Marcin Wiechec, Mirosław Wielgos, Mariusz Zimmer .....	490
---	-----

# TLR family gene expression in relation to the HIF1 $\alpha$ and the VEGFR pathway activation in endometrial cancer

Katarzyna M. Wojcik-Krowiranda<sup>1</sup> , Ewa Forma<sup>2</sup> , Andrzej Bienkiewicz<sup>1</sup> , Lukasz Cwonda<sup>1</sup> ,  
Joanna Wronska-Stefaniak<sup>1</sup> , Magdalena Brys<sup>2</sup> 

<sup>1</sup>Clinical Department of Gynecologic Oncology, Medical University of Lodz, Poland

<sup>2</sup>Department of Biology, University of Lodz, Poland

## ABSTRACT

**Introduction:** Malignant neoplasm of the endometrium is the most common malignant neoplasm of the female reproductive system. Toll Like Receptors (TLR) play a significant role in innate and late-immunity against infections or damaged tissues. TLRs are also involved in the development of tumors in their natural microenvironment. TLRs play an important role in angiogenesis, necessary for survival and growth of the tumor. Hypoxia playing a critical role in angiogenesis, carcinogenesis, tumor progression and distant metastasis is primarily mediated through hypoxia inducible factors (HIFs). Vascular endothelial growth factor family proteins (VEGF) are also strongly involved in tumor angiogenesis and their action is strongly associated with TLR receptors.

**Objectives:** The aim of the study was to correlate the expression of selected TLRs and VEGFR's as well as HIF1 $\alpha$  with clinicopathological data of endometrial cancer patients.

**Material and methods:** 123 neoplastic endometrial samples were included in the study. 51 samples of healthy endometrium served as control. The expression of TLR1, TLR2, TLR3, TLR4, VEGFR1 and VEGFR2, VEGF-A and HIF1 $\alpha$  was examined after RNA isolation at the mRNA level by Real Time-PCR.

**Results:** We have noted a significant correlation between the expression of selected TLR and VEGFR's and clinical stage as well as pathological grading of endometrial cancer.

**Conclusions:** Received correlations confirm a significant contribution of some TLR expression and the receptor for VEGF in the pathogenesis of epithelial endometrial cancer.

**Key words:** endometrial cancer; TLR family; VEGF; VEGFR2; VEGFR1; HIF1- $\alpha$

Ginekologia Polska 2020; 91, 8: 439–446

## INTRODUCTION

Endometrial carcinoma is the most common malignant neoplasm of the female reproductive system worldwide. The increasing number of cases is related to the increasing number of women with endometrial cancer risk factors, both in Poland and in other developed countries.

Mechanisms regulating the carcinogenesis as well as the cell death process are not fully understood.

The solid tumor growth and its metastatic ability depends mainly on the angiogenesis. Thus, the process of tumor vessels growing is a promising therapeutic target. In recent years, important progress in molecular targeted therapy, including antiangiogenic therapy has been observed. The issue limiting the efficacy of this kind of therapy is the drug resistance. Therefore, further efforts to better understand and eliminate this resistance are required.

In solid tumors the area of low oxygen tension, significantly hypoxic when compared to the healthy tissue are observed. The solid tumor formation is accompanied by local hypoxia, which is often considered to be an independent prognostic factor in many malignancies [1]. Hypoxia-inducible factor-1 (HIF-1) induced in the low oxygen tumor region is known to be an important transcription factor, mediating the cellular activity in the low oxygen environment. Since the mid-eighties, research on their potential participation in the regulation of the cancer process is ongoing.

Toll-like receptors (TLRs) are type I transmembrane receptors that are involved in the recognition and transmission of pathogens to the immune system. They also play an important role in tissue homeostasis. TLRs are a transmitter of information about damaged tissues, which may play a role in the phenomenon of cancer. TLRs are

### Corresponding author:

Katarzyna Wojcik-Krowiranda  
Clinical Department of Gynecologic Oncology, Medical University of Lodz, 62 Pabianicka St, 93–513 Lodz, Poland  
Phone: (+48) 426895512; fax: (+48) 426895952  
e-mail: katarzyna.wojcik-krowiranda@umed.lodz.pl

a family of particles that recognize the structure of ligands derived from microorganisms or damaged host cells. Their name is related to their similarity to the protein coded by the Toll gene identified in *Drosophila* [2]. Binding of ligand and TLR plays a key role in innate and late immunity [3, 4]. The TLR family consists of at least 13 types [5]. Eleven of these (TLR1 to TLR11) have so far been identified in humans. They are located on the surface or in the cytoplasm of immune cells and recognize various molecules and molecular products (DAMP and PAMP). PAMPs are molecular products derived from pathogens. DAMPs are endogenous molecules released from damaged or dying cells. Both DAMP-dependent and PAMP-dependent immune responses via TLR signals are known [6]. TLRs are also involved in the development of tumors in their natural microenvironment. The tumor microenvironment, including cancer cells, normal cells subjected to the “stressogenic” factor, stromal tissue and extracellular matrix, have recently been recognized as the main factor in the progression and metastasis of cancer [7]. Lowering the level of anti-cancer antibodies is the cause of decreased activity of infiltrating immune cells, resulting in cancer progression, angiogenesis and metastasis [8, 9]. Recent studies show that activated TLRs on tumor cells can suppress the anti-tumor effect and functions of infiltrating immune cells, thus altering the inflammatory response in a way that promotes tumor growth [10]. Epithelial cells of the female reproductive system can undergo neoplastic transformation due to continuous TLR stimulation by PAMP. Four types of TLR (TLR2-5) were expressed in ovarian cancer cell lines [11]. Activation of TLR4 promotes the survival of ovarian cancer cells by inducing the expression of antiapoptotic proteins [12]. It was also shown that TLR5 and TLR9 may contribute to the development of cervical cancer [13, 14]. It seems that TLRs play an important role in angiogenesis necessary for survival and growth of the tumor. The main factor is vascular endothelial growth factor (VEGF) — involved in tumor angiogenesis and associated with TLR signals. Vascular endothelial growth factor (VEGF-A) is a key molecule involved in the process of angiogenesis. [15]. Over-expression of VEGF in tumor cells enhances tumor growth and metastasis in several malignancies, including endometrial cancer. The structure of new vessels, induced by VEGF, is different from the one of normal vessels. Their different permeability leads to high interstitial pressure and further hypoxia, which stimulates additional VEGF production [16]. Solid tumors due to the characteristic hypoxia, which is a stress factor leading to the emergence and release of DAMP [17]. These ligands activate TLR signals and contribute to molecular abnormalities in the tumor microenvironment. However, under tumor conditions, the cells die through non-apoptotic

pathways, mainly necrosis. DAMPs released from damaged or dying cells are recognized by TLR on immune cells; subsequent disturbances of the signal recognized by TLR lead to the progression of cancer [18].

The few data available in the literature refer to the potential contribution of individual TLRs to tumorigenesis in endometrial cancer.

## MATERIAL AND METHODS

**A total of 123 women with uterine endometrial endometrioid cancer were enrolled to this study. All patients included in the present study gave their written informed consent.** Post-operative tissues were subjected to routine histopathological examination in which the histological type of the tumor, the clinical stage of the tumor according to FIGO, the degree of cellular differentiation (grading), tumor size, lymph node status, involvement of surrounding tissues — ovaries, fallopian tubes, cervix, parametria — were assessed. The control group consisted of 51 samples of healthy endometrium taken from surgically removed uteri for non-oncological reasons. **Immediately after uterus resection, approx. 0.2 g cancer tissue samples, (from visible part of the tumor), removed from the uterus,** were placed in RNeasy lysis buffer (Qiagen, USA) for overnight incubation. Samples were subsequently stored at  $-80^{\circ}\text{C}$  until RNA extraction. Clinico-pathological and demographic data of patients are presented in Table 1.

### Methods

#### *RNA extraction and cDNA synthesis*

Total RNA was isolated from frozen samples of tissue using EXTRACTME Total RNA Kit (Blirt, Poland) according to manufacturer’s protocol. Quantity and quality of the isolated RNA were assessed spectrophotometrically. First strand cDNAs were obtained by reverse transcription of 2  $\mu\text{g}$  of total RNA using High Capacity cDNA Revers Transcription Kit (Life Technology, USA) following the manufacturer’s protocol.

#### *Quantitative real time PCR analysis*

The relative expression levels of *TLR1*, *TLR2*, *TLR3*, *TLR4* and *VEGFR1* were analyzed by real time PCR using the TaqMan® Gene Expression Assays (Life Technology, USA) according to manufacturer’s instruction. Quantitative data were normalized to *HPRT1* used as reference gene. The assays numbers for studied genes were as follows Hs00413978\_m1 — *TLR1*, Hs02621280\_s1 — *TLR2*, Hs01551078\_m1 — *TLR3*, Hs00152939\_m1 — *TLR4*, Hs01052961\_m1 — *VEGFR1* and Hs02800695\_m1 (reference gene).

Each PCR reaction was performed in duplicate and included 1  $\mu\text{l}$  of cDNA, 3.5  $\mu\text{l}$  water, 5  $\mu\text{l}$  of 2x TaqMan® Universal PCR MasterMix (Life Technology, USA) and 0.5  $\mu\text{l}$  of TaqMan®



**Table 1. Demographic and clinical-pathological characteristics of the study group**

	study group n (%)	control group n (%)
group size	n = 123	n = 51
age, the average age	68.50 $\pm$ 10.32	
< 50 years	7 (5.69)	
$\geq$ 50 years	116 (94.31)	
clinical-pathological characteristics pT		
pT1-pT2	112 (91.0)	
pT3-pT4	11 (9.0)	
pN		
pN0	98 (79.67)	
pN1-pN3	19 (15.44)	
no data	6 (4.89)	
G		
G1	12 (9.75)	
G2	84 (68.29)	
G3	17 (13.82)	
no data	10 (8.14)	
FIGO		
I-II	101 (82.1)	
III-IV	21 (17.07)	
no data	1 (0.83)	
myometrium infiltration		
< 1/2	62 (50.04)	
> 1/2	58 (47.15)	
no data	3 (2.81)	

Gene Expression Assays consisted of a pair unlabeled PCR primer and a TaqMan<sup>®</sup> probe with FAM<sup>™</sup> dye label on the 5' end and MGB nonfluorescent quencher on the 3' end. The following PCR program was used: 95°C for 10 min, 40 cycles of 95°C for 15 s, 1 min annealing and extension at 60°C. PCR reactions were carried out using the Mastercycler ep realplex (Eppendorf, Germany).

The equation  $2^{-\Delta Ct}$  was applied to calculate the expression of studied genes, where  $\Delta Ct = Ct$  of the target gene –  $Ct$  the reference gene (*HPRT1*). Results are expressed as a number of target gene mRNA copies per 1000 copies of *HPRT1* mRNA.

The relative expression levels of VEGFR2, VEGF and HIF-1 $\alpha$  were analyzed by real time PCR using SYBR Green reagent (Applied Biosystems, USA) according to Luczak et al., [1] and Amirchaghmaghi et al., (2015).

### Statistical analysis

Statistical analysis was performed using PQStat version 1.6.4 (PQStat Software, Poland). Differences of mRNA expression among groups were analyzed by non-parametric

test (Mann-Whitney *U* test and Kruskal-Wallis test with *post hoc* multiple comparisons). Co-expression of genes was analyzed using the Spearman test. A value of  $p < 0.05$  was considered statistically significance.

## RESULTS

The expression of TLR1, TLR2, TLR3, TLR4, VEGFR1 VEGFR2, VEGF-A and HIF-1 $\alpha$  at the mRNA level were correlated to clinical and pathological features.

### 1. Tumor size (pT)

#### a) TLR1 gene

The lowest values of the TLR1 gene were recorded in the T3-T4 endometrial cancer group. This difference was statistically significant when compared to the control ( $p < 0.002$ ) (Fig. 1).

#### b) TLR2 gene

There were no statistically significant differences between the examined groups.

#### c) TLR3 gene

There were highly significant differences between the examined groups. Both T1-T2 and T3-T4 groups revealed significantly lower expression of TLR3 ( $p < 0.0001$ ) when compared to the control group (Fig. 1).

#### d) TLR4 gene

There were no statistically significant differences between TLR4 gene expression in the examined groups.

#### e) VEGFR1 gene

The VEGFR1 gene expression in the control group was significantly lower than in the group of patients with small (T1-2) and large (T3-4) tumors ( $p < 0.003$  and  $p < 0.0001$ , respectively). VEGFR1 expression for T1- T2 group did not differ from the T3-T4 group (Fig. 1).

#### f) VEGFR2 gene

The VEGFR2 gene expression in the control group was significantly higher than in the group of patients with small (T1-2) and large (T3-4) tumors ( $p < 0.0001$  and  $p < 0.0001$ , respectively). VEGFR2 expression for T1- T2 group did not differ from the T3-T4 group (Fig. 1).

#### g) VEGF-A gene

There were no statistically significant differences between the examined groups.

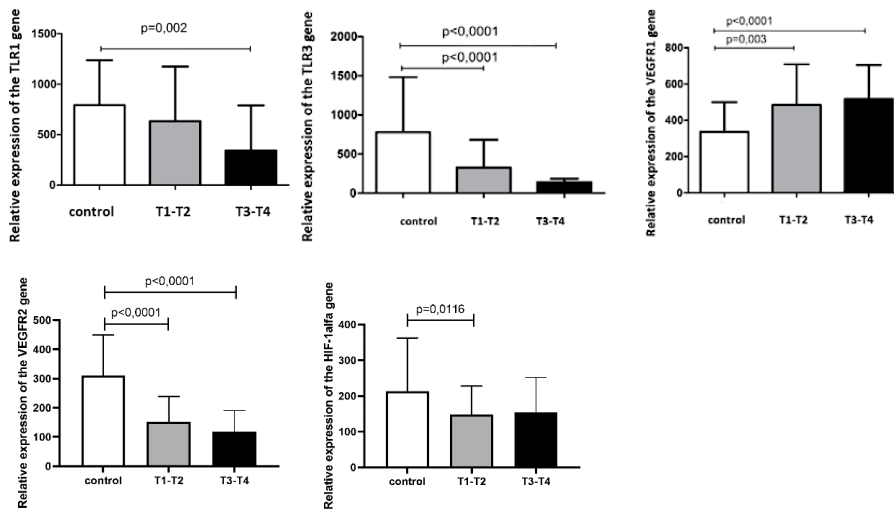
#### h) HIF1 $\alpha$

The significantly lower expression of HIF1 $\alpha$  was observed only in a T1-T2 group when compared to the control (Fig. 1).

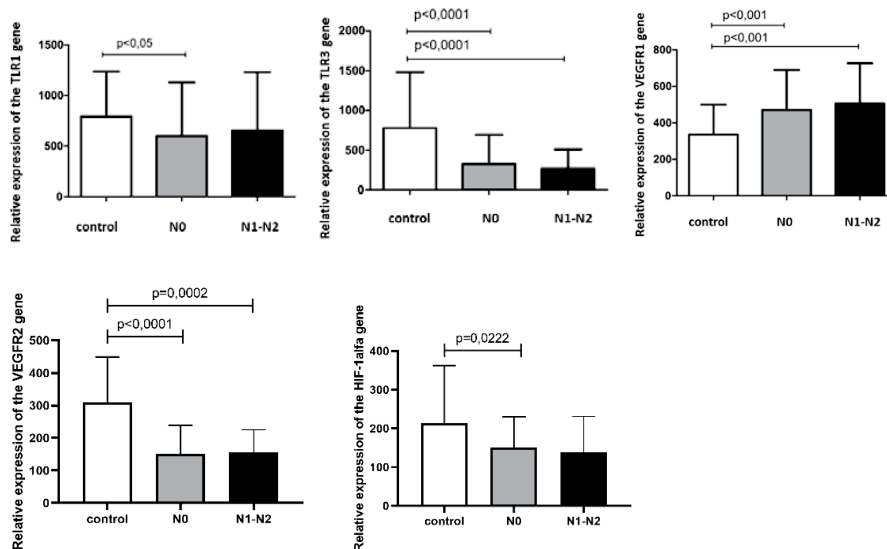
### 2. Lymph node status (pN)

#### a) TLR1 gene

The highest TLR1 expression was found in the control group. They differed significantly from the lowest values found in the group of patients with endometrial cancer without regional lymph node involvement ( $p < 0.05$ ). There were no other significant differences in TLR1 expression between the examined groups (Fig. 2).



**Figure 1.** Expression of the TLR, VEGFR and HIF-1alfa genes depending on the size of the tumor



**Figure 2.** Expression of the TLR, VEGFR and HIF-1alfa genes depending on the state of regional lymph nodes

b) TLR2 gene

The expression of the TLR2 gene did not differ statistically between the control group and the group of patients with endometrial cancer regardless of nodal status.

c) TLR3 gene

TLR3 gene expression was significantly lower (at the same level of significance —  $p < 0.0001$ ) in both endometrial cancer groups, *i.e.* regardless of the lymph node status, when compared to the control group (Fig. 2).

d) TLR4 gene

There were no statistically significant differences between TLR4 gene expression in the examined groups compared to the control group.

e) VEGFR1 gene

The VEGFR1 gene expression was significantly higher ( $p < 0.0001$ ) in the group of women with cancer regardless of the lymph node status, when compared to the control (Fig. 2).

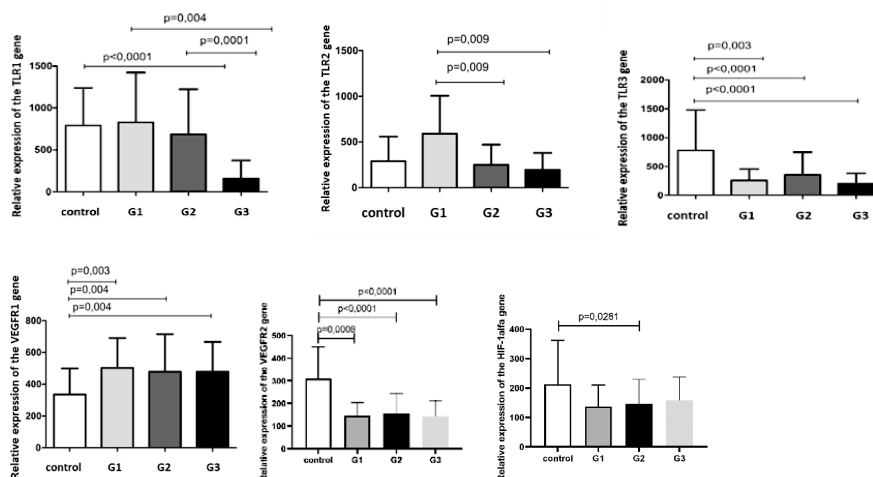
f) VEGFR2 gene

The VEGFR2 gene expression in the control group was significantly higher ( $p < 0.0001-0.0002$ ) than in the cancer groups regardless of the lymph node status, when compared to the control (Fig. 2).

g) VEGF-A gene

There were no statistically significant differences between the examined groups.

h) HIF1α



**Figure 3.** Expression of the TLR, VEGFR and HIF-1 $\alpha$  genes depending on the grade of malignancy of the tumor

The significantly lower ( $p < 0.022$ ) expression of HIF1 $\alpha$  was observed only in a N0 group, when compared to the control (Fig. 2).

### 3. Tumor differentiation (G)

#### a) TLR1 gene

The lowest values of TLR1 gene expression were recorded in low-grade tumors (G3). This difference showed a high statistical significance ( $p < 0.0001$ ) when related to G1, G2 and control group. TLR1 expression in groups G2 and G1 did not differ significantly from the control (Fig. 3).

#### b) TLR2 gene

The highest TLR2 gene expression values were observed in G1 tumors. Significant differences were found between well differentiated tumors (G1) in comparison to G2 and G3 tumors. However, no statistically significant differences were found between the studied groups and the control (Fig. 3).

#### c) TLR3 gene

TLR3 gene expression is lower in all examined cancer groups regardless of the degree of tumor differentiation (G) when compared to the control. For all G groups, those relations were highly ( $p < 0.003$ ,  $p < 0.0001$ ) different (Fig. 3).

#### d) TLR4 gene

Expression of the TLR4 gene did not differ statistically between the examined cancer groups when compared to the control.

#### e) VEGFR1 gene

VEGFR1 gene expression was significantly higher in all examined cancer groups, regardless of the tumor differentiation (G) when compared to the control group. For all G degrees, these relations were characterized by high statistical significance ( $p < 0.003$ ,  $p < 0.004$ ) (Fig. 3).

#### f) VEGFR2 gene

VEGFR2 gene expression was significantly lower in all examined cancer groups, regardless of the tumor dif-

ferentiation (G) when compared to the control group. For all G degrees, these relations were characterized by high statistical significance ( $p < 0.0001$ ,  $p < 0.0001$  and  $p < 0.0008$ ) (Fig. 3).

#### g) VEGF-A gene

There were no statistically significant differences between the examined groups.

#### h) HIF1 $\alpha$

The significantly lower expression of HIF1 $\alpha$  was observed only in G2 group when compared to the control (Fig. 3).

### 4. FIGO stage of endometrial cancer

#### a) TLR1 gene

There were no statistically significant differences in TLR1 gene expression related to FIGO stage between the examined groups and the control.

#### b) TLR2 gene

There were no statistically significant differences in the expression of the TLR2 gene between the examined groups and the control.

#### c) TLR3 gene

In the examined groups of patients with endometrial cancer, the expression of the TLR3 gene was significantly lower, regardless of the FIGO stage, when compared to the control group ( $p < 0.0001$ ) (Fig. 4).

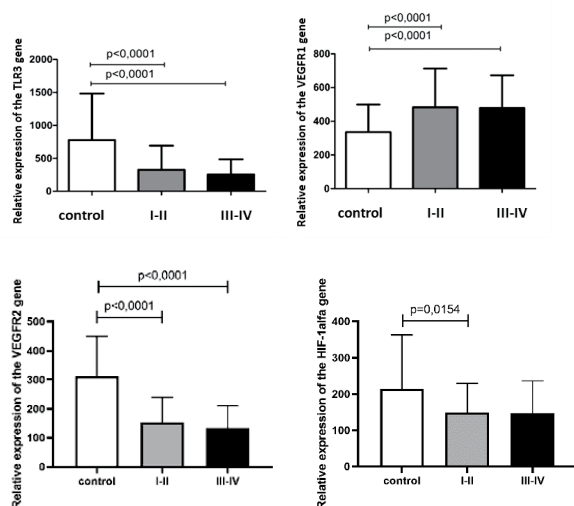
#### d) TLR4 gene

There were no statistically significant differences in TLR4 gene expression between the examined groups and the control.

#### e) VEGFR1 gene

VEGFR1 gene expression was significantly higher ( $p < 0.0001$ ) in the examined groups when compared to the control group, regardless of the FIGO stage (Fig. 4).

#### f) VEGFR2 gene



**Figure 4.** Expression of the TLR, VEGFR and HIF-1alfa genes depending on the FIGO stage

In the examined groups of patients with endometrial cancer, the expression of the VEGFR2 gene was significantly lower, regardless of the FIGO stage, when compared to the control ( $p < 0.0001$ ) (Fig. 4).

g) VEGF-A gene

There were no statistically significant differences between the examined groups.

h) HIF1 $\alpha$

The significantly lower ( $p < 0.0154$ ) expression of HIF1 $\alpha$  was observed only in FIGO I-II group when compared to the control (Fig. 4).

## DISCUSSION

TLRs are a link that combines non-specific with specific immunity. Their role in the pathogenesis of malignant tumors is not fully understood. In the available literature, there are few data about the TRL receptor compound, with mechanisms related to cancer and the spread of tumors in the human body. It is known that the expression of certain types of TLRs is different in cancers of the ovary, cervix, large intestine, breast and others [10]. There are also some data on participation of the TLRs in physiological processes in the endometrium, as well as in endometrial hypertrophy and some post-partum pathologies [19]. Hypoxia playing a critical role in angiogenesis, carcinogenesis, tumor progression and distant metastasis is primarily mediated through hypoxia inducible factors (HIFs) [20]. In the available literature, however, there are few reports analyzing the potential importance of TLRs in the pathogenesis of endometrial cancer and its relation to specific hypoxia markers.

In our study, we correlated the expression of selected TLRs with angiogenic and hypoxia factors in relation to the clinico-pathological data.

Expression of TLR3 was significantly lower, regardless of the size of the tumor, represented in the pathomorphological classification as a T feature, in relation to the control. In turn, TLR1 receptor expression only in advanced (T3-T4) tumors, similarly as TLR3, was significantly reduced. These data are partly correlated with the report by Allhorn et al. [21], who evaluated the expression of TLR3 and TLR4 in various conditions of the endometrium and revealed, among others, that TLR3 and TLR4 expression is significantly reduced in low-differentiated endometrial tumors. However, authors did not refer those results to the clinico-pathological data of the disease. In contrast to the above results, we did not demonstrate the important role of the TRL4 receptor in the pathogenesis of endometrial cancer.

In turn, according to expectations and data from the literature [16, 22], the expression of VEGFR1 was significantly increased in cancer tissue, when compared to the control, irrespective of their size, grading, nodal status and FIGO stage. In contrast, the VEGFR2 expression was significantly decreased in the endometrial cancer samples in the tumor size independent manner.

The relations between transcriptome and proteome is not a clear and direct issue. The protein and mRNA cellular content might be influenced by many factors. One can suppose, the mRNA expression may be regulated by the negative feedback control mechanism. The protein to protein interactions may stabilize some proteins. This can be induced by protein's physiological turnover disruption.

Protein half-life increases due to its stabilisation what is induced when components involved in normal protein's turnover are disrupted or through protein to protein interactions. This phenomenon may occur when downregulation of mRNA and simultaneous protein upregulation are observed.

Akin to VEGFR1, VEGFR2 expression was related to the presence of malignancy regardless of tumor differentiation, nodal status and FIGO stage. This observation indirectly confirms the important role of VEGF receptors in the development of endometrial cancer.

In our study we were unable to demonstrate correlation between VEGF-A protein and clinico pathological data of examined tissues.

The presence of metastases in the lymph nodes did not influence on TLR3 expression. Significantly lower TLR3 expression was observed in cancerous tumors irrespective to the lymph node status.

Tumor malignancy (G) is one of the most important, independent prognostic factors in endometrial cancer. We have demonstrated the highly significant correlation between cell differentiation and some TLRs, VEGFR1, VEGFR2 expression. Like in other clinic-pathologic factors, the expression of VEGFR1 and VEGFR2 were opposite when related to the tumor malignancy.

In undifferentiated tumors (G3), TLR3 expression was significantly lower than in the control group. It was also decreased in comparison to more differentiated tumors (G2 and G1), but this difference was not statistically significant. Similar results were obtained by Allhorn et al. [21]. Although the results given in the cited work were based on the analysis of only 16 cases of endometrial cancer, similarly to our results, the authors observed significantly lower TLR3 expression in all degrees of cellular differentiation. Different results on TLR4 expression in endometrial cancer tissue were presented by Allhorn et al. In our study, the expression of this receptor in tumor tissues did not differ from the control group, while Allhorn observed a relationship between TLR4 expression and tumor differentiation, like that found in TLR3 results.

Similarly, VEGF1 and VEGFR2 receptors expression were different in neoplastic tumors irrespective to the regional nodal involvement. This highly significant correlation, negative for VEGFR1 and positive for VEGFR2 seems to support the hypothesis of their direct involvement in cancerogenesis [23]. Similar results were obtained by [24] and [25].

Gene expression for VEGFR1 appears to be inversely related to TLR3 expression. Similar to the available data [18], in all malignant endometrial tumors, it was significantly higher than in the control group. Analogous relations were observed by Giatromanolaki A et al. [26] who demonstrated that VEGFR expression is one of significant independent prognostic factors in epithelial endometrial tumors. In contrast, gene expression of VEGFR2 appeared to be directly related to TLR3 expression. The explanation of those differences needs further studies.

Surprisingly, Hypoxia Inducible Factor-1 $\alpha$  (HIF-1 $\alpha$ ) supposed to play a key role in hypooxygenation of cancer tissue was not overexpressed in endometrial cancer tissue in more advanced, undifferentiated tumors.

We have not found a highly significant correlation between lymph node involvement and the expression of HIF1 $\alpha$  - the typical hypoxia marker. Those results stay in contrast to those published by Tawadros et al. [27] who observed a significant association between HIF1 $\alpha$  expression and lymph node involvement in endometrial cancer. The explanation of our observation needs further studies

The FIGO stage at the time of diagnosis is an important prognostic factor in endometrial tumors, apart from the degree of cancer differentiation. Studies on the relationship between the expression of selected TLR's and VEGFR receptors and the clinical stage of the disease allowed us to demonstrate statistically significant relations. FIGO III and IV stage tumors are associated with significantly lower TLR3 expression, high VEGFR1 expression and low VEGFR2 expression. Similar relationships were not stated for TLR1, TLR2 and TLR4. The HIF1 $\alpha$  expression in relation to the FIGO stage did not present a statistically different relation.

The relations observed in our study might confirm the hypothesis indicating a significant role of VEGF through selected TLRs in the pathogenesis of endometrioid endometrial malignancies. Selected TLRs may influence the proliferation of a tumor by inducing a response that causes the process of inhibiting tumor progression. In this process, the receptor for epidermal growth factor (VEGFR) appears to be an important factor. The possibility of pharmacological intervention in the immune response to the pathogenic molecular factors that trigger this response may be a promising alternative to the treatment of endometrial malignant tumors. However, this hypothesis requires further research.

#### **Conflict of interest**

The authors declared no potential conflict of interest with respect to the research, authorship, and/or publication of this article.

#### **Ethical approval**

We declare that all experiments were performed in accordance with the current law of Poland. The investigations were approved by the Bioethical Commission of Medical University of Lodz (RNN/16/16/KE).

#### **REFERENCES**

1. Łuczak MW, Roszak A, Pawlik P, et al. Increased expression of HIF-1 $\alpha$  and its implication in the hypoxia pathway in primary advanced uterine cervical carcinoma. *Oncol Rep.* 2011; 26(5): 1259–1264, doi: [10.3892/or.2011.1397](https://doi.org/10.3892/or.2011.1397), indexed in Pubmed: [21887475](https://pubmed.ncbi.nlm.nih.gov/21887475/).
2. Yu Li, Wang L, Chen S. Endogenous toll-like receptor ligands and their biological significance. *J Cell Mol Med.* 2010; 14(11): 2592–2603, doi: [10.1111/j.1582-4934.2010.01127.x](https://doi.org/10.1111/j.1582-4934.2010.01127.x), indexed in Pubmed: [20629986](https://pubmed.ncbi.nlm.nih.gov/20629986/).
3. Clarke DL, Davis NHE, Majithiya JB, et al. Development of a mouse model mimicking key aspects of a viral asthma exacerbation. *Clin Sci (Lond).* 2014; 126(8): 567–580, doi: [10.1042/CS20130149](https://doi.org/10.1042/CS20130149), indexed in Pubmed: [24152048](https://pubmed.ncbi.nlm.nih.gov/24152048/).
4. Nadeem A, Siddiqui N, Al-Harbi NO, et al. TLR-7 agonist attenuates airway reactivity and inflammation through Nrf2-mediated antioxidant protection in a murine model of allergic asthma. *Int J Biochem Cell Biol.* 2016; 73: 53–62, doi: [10.1016/j.biocel.2016.02.004](https://doi.org/10.1016/j.biocel.2016.02.004), indexed in Pubmed: [26851512](https://pubmed.ncbi.nlm.nih.gov/26851512/).
5. Netea MG, Van Der Graaf CAA, Vonk AG, et al. The role of toll-like receptor (TLR) 2 and TLR4 in the host defense against disseminated candidiasis. *J Infect Dis.* 2002; 185(10): 1483–1489, doi: [10.1086/340511](https://doi.org/10.1086/340511), indexed in Pubmed: [11992285](https://pubmed.ncbi.nlm.nih.gov/11992285/).
6. van der Heijden IM, Wilbrink B, Tchetverikov I, et al. Presence of bacterial DNA and bacterial peptidoglycans in joints of patients with rheumatoid arthritis and other arthritides. *Arthritis Rheum.* 2000; 43(3): 593–598, doi: [10.1002/1529-0131\(200003\)43:3<593::AID-ANR16>3.0.CO;2-1](https://doi.org/10.1002/1529-0131(200003)43:3<593::AID-ANR16>3.0.CO;2-1), indexed in Pubmed: [10728753](https://pubmed.ncbi.nlm.nih.gov/10728753/).
7. Whiteside TL. The tumor microenvironment and its role in promoting tumor growth. *Oncogene.* 2008; 27(45): 5904–5912, doi: [10.1038/onc.2008.271](https://doi.org/10.1038/onc.2008.271), indexed in Pubmed: [18836471](https://pubmed.ncbi.nlm.nih.gov/18836471/).
8. Li H, Han Y, Guo Q, et al. Cancer-expanded myeloid-derived suppressor cells induce anergy of NK cells through membrane-bound TGF- $\beta$ 1. *J Immunol.* 2009; 182(1): 240–249, doi: [10.4049/jimmunol.182.1.240](https://doi.org/10.4049/jimmunol.182.1.240), indexed in Pubmed: [19109155](https://pubmed.ncbi.nlm.nih.gov/19109155/).
9. Strauss L, Bergmann C, Whiteside TL. Human circulating CD4+CD25highFoxp3+ regulatory T cells kill autologous CD8+ but not CD4+ responder cells by Fas-mediated apoptosis. *J Immunol.* 2009; 182(3): 1469–1480, doi: [10.4049/jimmunol.182.3.1469](https://doi.org/10.4049/jimmunol.182.3.1469), indexed in Pubmed: [19155494](https://pubmed.ncbi.nlm.nih.gov/19155494/).

10. Yusuke S, Yasufumi G, Norihiko N, et al. H.: Cancer Cells Expressing Toll-like Receptors and the Tumor Microenvironment. *Cancer Microenvironment*. 2009; 2(Suppl 1): 205–214.
11. Zhou M, McFarland-Mancini MM, Funk HM, et al. Toll-like receptor expression in normal ovary and ovarian tumors. *Cancer Immunol Immunother*. 2009; 58(9): 1375–1385, doi: [10.1007/s00262-008-0650-y](https://doi.org/10.1007/s00262-008-0650-y), indexed in Pubmed: [19184006](https://pubmed.ncbi.nlm.nih.gov/19184006/).
12. Dan HC, Sun M, Kaneko S, et al. Role of X-linked inhibitor of apoptosis protein in chemoresistance in ovarian cancer: possible involvement of the phosphoinositide-3 kinase/Akt pathway. *Drug Resist Updat*. 2002; 5(3-4): 131–146, doi: [10.1016/s1368-7646\(02\)00003-1](https://doi.org/10.1016/s1368-7646(02)00003-1), indexed in Pubmed: [12237081](https://pubmed.ncbi.nlm.nih.gov/12237081/).
13. Kim WY, Lee JW, Choi JJ, et al. Increased expression of Toll-like receptor 5 during progression of cervical neoplasia. *Int J Gynecol Cancer*. 2008; 18(2): 300–305, doi: [10.1111/j.1525-1438.2007.01008.x](https://doi.org/10.1111/j.1525-1438.2007.01008.x), indexed in Pubmed: [17587322](https://pubmed.ncbi.nlm.nih.gov/17587322/).
14. Lee JW, Choi JJ, Seo ES, et al. Increased toll-like receptor 9 expression in cervical neoplasia. *Mol Carcinog*. 2007; 46(11): 941–947, doi: [10.1002/mc.20325](https://doi.org/10.1002/mc.20325), indexed in Pubmed: [17440926](https://pubmed.ncbi.nlm.nih.gov/17440926/).
15. Xu X, Yan Y, Xun Q, et al. Combined silencing of VEGF-A and angiopoietin-2, a more effective way to inhibit the Ishikawa endometrial cancer cell line. *Onco Targets Ther*. 2019; 12: 1215–1223, doi: [10.2147/OTT.S194064](https://doi.org/10.2147/OTT.S194064), indexed in Pubmed: [30863089](https://pubmed.ncbi.nlm.nih.gov/30863089/).
16. Carmeliet P. VEGF as a key mediator of angiogenesis in cancer. *Oncology*. 2005; 69 Suppl 3: 4–10, doi: [10.1159/000088478](https://doi.org/10.1159/000088478), indexed in Pubmed: [16301830](https://pubmed.ncbi.nlm.nih.gov/16301830/).
17. Li H, Han Y, Guo Q, et al. Cancer-expanded myeloid-derived suppressor cells induce anergy of NK cells through membrane-bound TGF-beta 1. *J Immunol*. 2009; 182(1): 240–249, doi: [10.4049/jimmunol.182.1.240](https://doi.org/10.4049/jimmunol.182.1.240), indexed in Pubmed: [19109155](https://pubmed.ncbi.nlm.nih.gov/19109155/).
18. Lotze MT, Zeh HJ, Rubartelli A, et al. The grateful dead: damage-associated molecular pattern molecules and reduction/oxidation regulate immunity. *Immunol Rev*. 2007; 220: 60–81, doi: [10.1111/j.1600-065X.2007.00579.x](https://doi.org/10.1111/j.1600-065X.2007.00579.x), indexed in Pubmed: [17979840](https://pubmed.ncbi.nlm.nih.gov/17979840/).
19. Martins TM, Muniz CS, Andrade VB, et al. Changes in endometrial transcription of TLR2, TLR4, and CD14 during the first-week postpartum in dairy cows with retained placenta. *Theriogenology*. 2016; 85(7): 1282–1288, doi: [10.1016/j.theriogenology.2015.12.013](https://doi.org/10.1016/j.theriogenology.2015.12.013), indexed in Pubmed: [26777563](https://pubmed.ncbi.nlm.nih.gov/26777563/).
20. Tian Q, Xue Y, Zheng W, et al. Overexpression of hypoxia-inducible factor 1 $\alpha$  induces migration and invasion through Notch signaling. *Int J Oncol*. 2015; 47(2): 728–738, doi: [10.3892/ijo.2015.3056](https://doi.org/10.3892/ijo.2015.3056), indexed in Pubmed: [26094772](https://pubmed.ncbi.nlm.nih.gov/26094772/).
21. Allhorn S, Böing C, Koch AA, et al. TLR3 and TLR4 expression in healthy and diseased human endometrium. *Reprod Biol Endocrinol*. 2008; 6: 40, doi: [10.1186/1477-7827-6-40](https://doi.org/10.1186/1477-7827-6-40), indexed in Pubmed: [18775079](https://pubmed.ncbi.nlm.nih.gov/18775079/).
22. Grimmig T, Moench R, Kreckel J, et al. Toll Like Receptor 2, 4, and 9 Signaling Promotes Autoregulative Tumor Cell Growth and VEGF/PDGF Expression in Human Pancreatic Cancer. *Int J Mol Sci*. 2016; 17(12), doi: [10.3390/ijms17122060](https://doi.org/10.3390/ijms17122060), indexed in Pubmed: [27941651](https://pubmed.ncbi.nlm.nih.gov/27941651/).
23. Gu CJ, Xie F, Zhang B, et al. High Glucose Promotes Epithelial-Mesenchymal Transition of Uterus Endometrial Cancer Cells by Increasing ER/GLUT4-Mediated VEGF Secretion. *Cell Physiol Biochem*. 2018; 50(2): 706–720, doi: [10.1159/000494237](https://doi.org/10.1159/000494237), indexed in Pubmed: [30308493](https://pubmed.ncbi.nlm.nih.gov/30308493/).
24. Mahecha AM, Wang H. The influence of vascular endothelial growth factor-A and matrix metalloproteinase-2 and -9 in angiogenesis, metastasis, and prognosis of endometrial cancer. *Onco Targets Ther*. 2017; 10: 4617–4624, doi: [10.2147/OTT.S132558](https://doi.org/10.2147/OTT.S132558), indexed in Pubmed: [29033580](https://pubmed.ncbi.nlm.nih.gov/29033580/).
25. Wang J, Taylor A, Showell R, et al. Expression profiling and significance of VEGF-A, VEGFR2, VEGFR3 and related proteins in endometrial carcinoma. *Cytokine*. 2014; 68(2): 94–100, doi: [10.1016/j.cyto.2014.04.005](https://doi.org/10.1016/j.cyto.2014.04.005), indexed in Pubmed: [24845798](https://pubmed.ncbi.nlm.nih.gov/24845798/).
26. Giatromanolaki A, Sivridis E, Brekken R, et al. The angiogenic ?vascular endothelial growth factor/flk-1(KDR) receptor? pathway in patients with endometrial carcinoma. *Cancer*. 2001; 92(10): 2569–2577, doi: [10.1002/1097-0142\(20011115\)92:10<2569::aid-cnrcr1609>3.0.co;2-3](https://doi.org/10.1002/1097-0142(20011115)92:10<2569::aid-cnrcr1609>3.0.co;2-3).
27. Tawadros AI, Khalafalla MM. Expression of programmed death-ligand 1 and hypoxia-inducible factor-1 $\alpha$  proteins in endometrial carcinoma. *J Cancer Res Ther*. 2018; 14(Supplement): S1063–S1069, doi: [10.4103/0973-1482.202891](https://doi.org/10.4103/0973-1482.202891), indexed in Pubmed: [30539847](https://pubmed.ncbi.nlm.nih.gov/30539847/).

# Ultrasound guided percutaneous radiofrequency thermal ablation of symptomatic uterine fibroids — results from a single center and 52 weeks of follow up

Gökhan Yüce<sup>1</sup>, Aybuke Tayarar<sup>2</sup>, Hüseyin Levent Keskin<sup>2</sup>, Birgül Genç<sup>3</sup>, Murat Canyigit<sup>1</sup>

<sup>1</sup>Ankara City Hospital, Interventional Radiology Department, Turkey

<sup>2</sup>Ankara Yıldırım Beyazıt University, Gynecology and Obstetrics Department, Turkey

<sup>3</sup>Ankara City Hospital, Endocrinology Department, Turkey

## ABSTRACT

**Objectives:** Uterine fibroids are one of the most common female disorder of the reproductive age and may cause abnormal uterine bleeding (UAB), pain or infertility. Our aim was to evaluate the safety and efficacy of percutaneous radio frequency ablation (RFA) in reducing clinical symptoms, fibroid volume and improving laboratory parameters.

**Material and methods:** Thirty-five symptomatic patients with 54 uterine fibroids were enrolled. Preintervention evaluation was made for each participant and included ultrasonography to assess the volume, largest diameter and location of the fibroid and Visual Analogue Scale (VAS) for quantifying the degree of menstrual pain. The magnitude of menstrual bleeding was scored for each patient by using pictogram. Preprocedural laboratory assessment included hemoglobin and hematocrit. Treatment efficacy was evaluated at 3, 6 and 12 months after the intervention with ultrasound (US) measurements, symptom scores and laboratory parameters.

**Results:** Pretreatment mean Hb was significantly lower than those at 3, 6 and 12 month post treatment visits ( $p < 0.001$ ). The pretreatment median volume was significantly higher than the median volumes measured at 3, 6 and 12 months after RFA ( $p < 0.001$ ). Visual Analogue Score (VAS) for pain was significantly lower than baseline values at 6 and 12 month visits ( $p < 0.01$ ). Pretreatment bleeding scores and the number of patients in the predefined severe bleeding category were significantly decreased.

**Conclusions:** US guided RF ablation of uterine fibroids is relatively safe and effective procedure. It can be applied to the fibroids with varying localizations and sizes. It reduces the fibroid volume and obviate a need for more invasive treatment.

**Key words:** uterine fibroids; percutaneous; radiofrequency ablation

Ginekologia Polska 2020; 91, 8: 447–452

## INTRODUCTION

Uterine fibroids are the most common benign tumors of the female reproductive system and have a significant effect on quality of life, economy and reproduction. Its prevalence was reported as 70% in Caucasian woman and 80% in Afro-Americans [1]. They constitute a big proportion of hysterectomy indications. In one report the annual cost of the disease and its obstetric complications was reported as \$5.89 billion–\$34.37 billion [2].

Uterine fibroids are classified in regard to their location in the uterus as intramural (completely or mostly localized within the myometrium), submucosal (projecting into the endometrial cavity and may be pedunculated), or sub serosal (projecting outward from the serosal surface of uterus

and may be pedunculated) [3]. They may be asymptomatic and discovered during routine examination [4]. Nevertheless, almost half of the individuals admit with clinical symptoms such as abnormal uterine bleeding (AUB), menstrual or intermenstrual pain, discomfort in pelvis region, infertility and consequent reduced quality of life [5, 6]. Diagnosis is usually made by ultrasound (US) which enables vaginal exploration and is very accurate and available except large fundal fibroids [7].

Recent treatment options are medical, surgical or minimally invasive techniques. Surgery is associated with complications and can cause significant morbidity [8]. Moreover, it is undesirable to women who are planning future pregnancies. Myomectomy is a less invasive surgical procedure and is

### Corresponding author:

Gokhan Yuçe,  
 Ankara City Hospital, Ankara City Hospital, Interventional Radiology Department, 06800 Ankara, Turkey  
 phone: +905425187733  
 e-mail: burcakugurlu@gmail.com

still associated with perioperative challenges such as bleeding control, adhesions, rare cases of uterine rupture and possible need for conversion of surgery to hysterectomy.

As the technology develops, less invasive interventional techniques have become more popular, which allow the selective destruction of the fibroids. Those are endovascular uterine artery embolization (UAE), high intensity focused ultrasound (HIFU) and radiofrequency ablation (RFA) [6, 9, 10]. Uterine artery embolization (UAE) isn't target selective and isn't recommended if pregnancy is desired. In addition to that, recurrent fibroid may develop and 20% of patients may require subsequent surgery [10].

RFA is an available option as a treatment modality for fibroids and can be performed via percutaneous or transvaginal route. In this technique, energy is released directly within the fibroid via electrodes without giving damage to the adjacent tissues. RFA reduces the volume of the fibroid and relieves associated symptoms [11, 12].

### Objectives

In this study, we aimed to evaluate the safety and efficacy of percutaneous RFA in relieving clinical symptoms, laboratory parameters and size of the fibroids in 52 weeks of the follow up period.

### MATERIAL AND METHODS

In this prospective study, 35 patients with symptomatic uterine fibroids who admitted to our tertiary center's Gynecology and Obstetrics clinics between November 2017 and October 2018 and required treatment were enrolled. Our local ethics committee approved the study protocol in accordance with principles of the Declaration of Helsinki. The patients recruited in the study were informed about the alternative treatment options including arterial embolization and surgery and the possible advantages and risks of RFA before obtaining the written informed consent. None of them had a comorbidity which could be a contraindication for the intervention, sedation or local anesthesia. The patients who were younger than 18 years of age, had active genitourinary infection, history of coagulation abnormality, present pregnancy/lactation or planning pregnancy were excluded.

Before the procedure all patients were assessed by the same gynecologist and radiologist. The gynecologist performed Visual Analogue Scale (VAS) in order to quantify the pain. The patient was requested to choose a score between 0–10 for dysmenorrhea (0 represented no pain and 10 was maximum pain). The magnitude of menstrual bleeding was also classified for each patient as amenorrhea, mild, moderate or severe bleeding. Pictorial Blood Loss Assessment Chart (PBAC) was used for that purpose and score 0 was defined as amenorrhea, score 0–50 as mild bleeding, score

50–100 as moderate bleeding and score > 100 as severe bleeding. Pretreatment evaluation included conventional transabdominal US and transvaginal ultrasound US (Logiq E9, GE Healthcare, Milwaukee, WI), equipped with a 3–5 MHz convex probe and a 1–6 MHz transvaginal probe. Data derived from pretreatment ultrasonography assessment of the fibroids was composed of the number, location (fundal, anterior, posterior, right side, left side, right horn, left horn), situation (subserosal, intramural or submucosal), the largest diameter and volume (volume =  $0.5233 \times \text{Anteroposterior} \times \text{Transverse} \times \text{Longitudinal Dimension}$ ). The measurements were repeated 3, 6 and 12 months after RFA. Preprocedural hemoglobin (Hb) and hematocrit (Htc) were recorded at baseline and reevaluated at 3, 6 and 12 months after RFA.

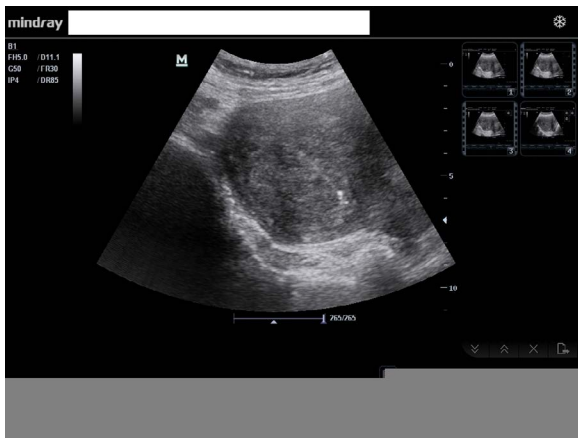
The RFA procedure was conducted in the interventional radiology department under intravenous (iv) sedation with 1–3 mg of midazolam, 25–50 mcg of fentanyl or 50–120 mg of propofol. During the RFA, patients were in supine position and monitored by means of electrocardiogram (ECG), blood pressure and pulse. Broad-spectrum antibiotic prophylaxis was given an hour before the procedure. A uterine manipulator was applied to allow fixation only in those patients whose fibroids were difficult to puncture due to either their rigid structure or challenging locations. Percutaneous RF was performed after the fibroid had been punctured under abdominal US monitoring by using a coaxial system with a 35 to 40 mm long umbrella-shaped needle-electrode (Med sphere, RF3000 system, Shanghai, China) (Fig. 1). One or more thermal ablations were performed depending on the size of the fibroid. Maximum intensity was 100 W during the ablation. The ultrasonographic appearance of the same fibroid before, during and after RFA were demonstrated on Figure 1 a–d.

After RFA, the patient was advised to take paracetamol for one or two days if needed and continue to the antibiotic treatment for one week. All complications that could be

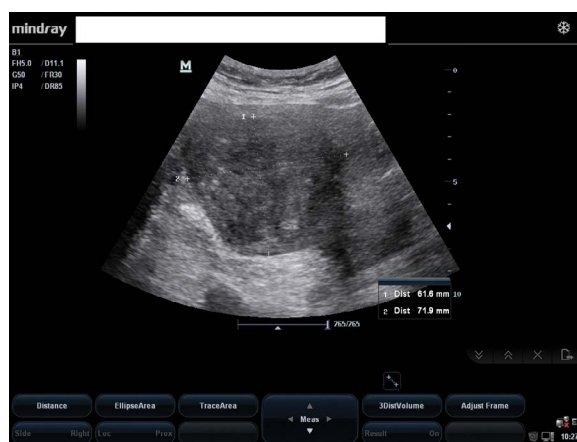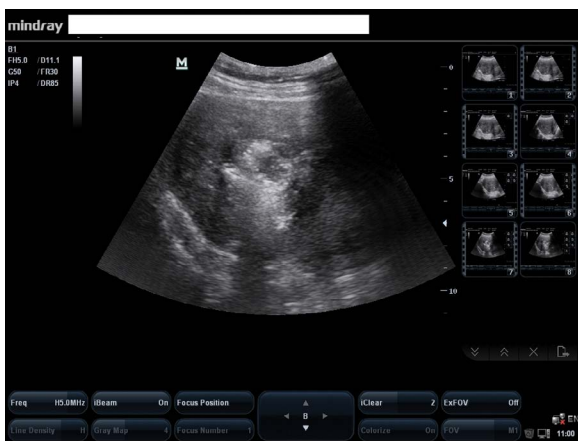


Figure 1a. Ultrasonographic image of the uterine fibroid before RFA

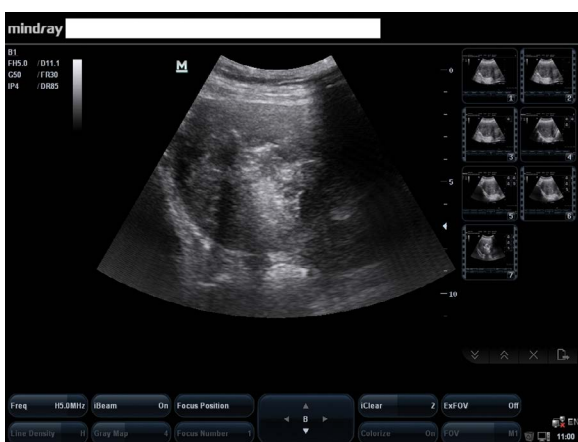




**Figure 1b.** RF needle placement within the fibroid during RFA



**Figure 1c.** Myolysis during RFA



**Figure 1d.** Ultrasonographic image of the fibroid after RF

associated with RFA were recorded right after and at the first visit 1 week after the intervention. Patients were called for control visits at 3, 6 and 12 months after RFA and US examination, symptom scores and laboratory parameters

**Table 1.** Baseline characteristics of 35 patients with 54 fibroids underwent RF ablation

Mean age (years)	35.36 ± 7.362
Nulligravida (number of patients)	5
Solitary fibroid (number of patients)	24
More than 1 fibroid (number of patients)	11
Type of fibroid intramural/subserosal (number)	(46/8)
Location of the fibroids (≠ of fibroids)	
Anterior	16
Posterior	8
Fundus	22
Right Horn	8

RF — radio frequency

were reassessed. Successful treatment was clinically considered when observing a reduction in symptoms 6 months after RFA. Successful treatment was also defined when the achieved fibroid necrosis at 6 months after treatment was larger than 50%.

### Statistics

The Statistical Package for the Social Sciences, version 25 (SPSS Inc., Chicago, IL, USA) was used for the statistical analysis. Descriptive statistics are presented as means ± standard deviation (SD) and medians (minimum–maximum) for continuous variables and as percentages (%) for categorical variables. The nonparametric Kolmogorov-Smirnov test was used to compare samples with the reference probability distribution, whereas the homogeneity of the variances assessed using the Levene test. The nonparametric Friedman test was used in order to compare initial and last measured volume and longest axis of the nodules before and after intervention.  $P < 0.05$  was accepted as statistically significant.

### RESULTS

Thirty-five symptomatic patients with 54 uterine fibroids who were unresponsive to medical therapy or didn't decide to undergo surgery and gave consent for RF treatment were enrolled in the study. The mean age was  $35.36 \pm 7.362$  (min–max; 25–47). Five patients were nulligravida, 17 had 2 gestations whereas the remaining had history of  $\geq 3$  previous gestations. Twenty-four patients had one fibroid whereas remaining eleven had multiple fibroids. The location of the fibroids was anterior in 16, posterior in 8, fundus in 22 and 8 in the right horn. Regarding the type of the fibroid, 46 were intramural whereas 8 were subserosal. The baseline characteristics of the patients were demonstrated on Table 1. The number of ablations performed for each patient was 2.7 (changing between 1–5 based on size). There wasn't any intervention related severe complication

**Table 2. Demonstration and comparison of pre and post ablation Hb, longest diameter, volume, pain and bleeding scores of the patients**

	Pre-ablation	Post RF 3 months	Post RF 6 months	Post RF 12 months	p*
Hb g/dL mean $\pm$ SD	11.56 $\pm$ 1.65	12.5 $\pm$ 1.42	13.17 $\pm$ 1.33	13.37 $\pm$ 4.47	p < 0.001
Longest diameter mm median (min–max)	72 (44–124)	56 (36–112)	52 (26–106)	53 (18–120)	p < 0.001
Volume mL median (min–max)	85 (17–519)	64 (13–330)	50 (3.4–372)	57(2.2–518)	p < 0.001
Mean Menstrual Pain VAS	7.95 $\pm$ 1.35	6.32 $\pm$ 1.25	4.74 $\pm$ 1.32	4.47 $\pm$ 1.12	p < 0.001
Bleeding severity (number of patients/%)					
Amenorrhoea	0 (0%)	0	0	0	p < 0.001
Mild	5 (14.3%)	9 (25.7%)	11 (31.5%)	15 (42.8%)	
Moderate	9 (25.7%)	15 (42.8%)	14 (40%)	14 (40%)	
Severe	21 (60%)	11 (31.5%)	10 (28.5)	6 (8.2%)	

reported after the procedure. The most prevalent complication was abdominal pain occurred in all except 2 patients which was mild to moderate and responsive to paracetamol treatment. Mild erythema and skin reaction at the entry site of the needle was observed in 19 patients and resolved in few days spontaneously without any need for topical treatments. Four patients reported urinary tract infection symptoms despite prophylactic antibiotics and were prescribed oral ciprofloxacin. None of the patients experienced leukocytosis, fever, nausea, fatigue or malaise after the procedure. Mild vaginal bleeding occurred in 12 patients that resolved in maximum 6 days. The mean time needed for whole procedure was approximately 45 minutes. Uterine manipulator was required only in five cases. All patients were discharged within the day of ablation and none of them required rehospitalization afterwards. During the 52 weeks of follow-up, none of the patients needed a subsequent surgery or another minimally invasive procedure. All patients attended the visits at 3, 6 and 12 months after RFA. The pretreatment mean Hb was 11.56  $\pm$  1.65 whereas posttreatment mean Hb at 3, 6 and 12 months were 12.5  $\pm$  1.42, 13.17  $\pm$  1.3 and 13.37  $\pm$  1.25, respectively. Posttreatment mean Hb values were significantly higher than pretreatment mean Hb (p < 0.01) whereas there wasn't any significant difference between the posttreatment Hb levels at 3, 6 and 12 months (Tab. 2). The pretreatment median longest diameter was significantly higher than posttreatment longest diameters (p = 0.003, p < 0.001 and p < 0.001, respectively) (Tab. 2). There wasn't any statistically significant difference between the posttreatment median longest diameters. When intramural and submucosal fibroids were compared, there wasn't any statistically significant difference between the baseline mean longest diameters whereas posttreatment longest diameters were significantly smaller for intramural fibroids (p < 0.001) at 3, 6 and 12 months after RFA. The pretreatment median volume of the fibroids was significantly higher than posttreatment median volumes at 3, 6 and 12 months after RFA (p = 0.007, p < 0.01 and p < 0.01, respectively) (Tab. 2). The median percentage of volume reduction compared

to baseline was 36.8% (3–72) at 3 months whereas it was 50% (2–92) and 46.8% (1–95) at 6 and 12 months after RFA, respectively. When intramural and submucosal fibroids were compared, post treatment mean volumes at 3, 6 and 12 months after RFA were significantly smaller and percentage of volume reduction was significantly higher for intramural fibroids (p < 0.001 and p = 0.024, respectively). Pretreatment mean VAS for menstrual pain was 7.95  $\pm$  1.35 and it was significantly higher than mean VAS (p < 0.01) at post-treatment 6 and 12 months (Tab. 2). Regarding bleeding severity, the number of patients who were experiencing severe menstrual bleeding was significantly reduced in the post treatment follow up (Tab. 2).

## DISCUSSION

Uterine fibroids are the most common benign pelvic tumors. Previous studies have shown that 35% of premenopausal women had a previous diagnosis of fibroid tumors and 51% of undiagnosed premenopausal women had ultrasound evidence of fibroid tumors [1]. The location of the tumor, volume and adjacent organs may alter the clinical symptoms. Current treatment modalities for uterine fibroids are surgery or radiological interventions which include UAE or RFA. A hysterectomy can completely cure the uterine fibroids but is considered too radical by most of the patients and fertility is a concern. A myomectomy is less radical, but it can be associated with increased intraoperative bleeding, postoperative infection, pelvic adhesions and omission of tumors, which limits its usage. UAE is a frequently used technique which reduces length of hospital stay and pain compared to the operation and patients rapidly return to the daily usual activities. However, UAE has the risk of re-intervention, and lower pregnancy and live birth rates [13].

RF ablation is used in the treatment of uterine fibroids and has several advantages such as low cost and obviating need for hospitalization. Only one applicator is necessary for a single patient and RF generators are widely available in the interventional radiology units for ablation of wide variety of tumors. Radiofrequency ablation can be performed via

several routes such as during laparoscopy, percutaneous or transvaginal. In the laparoscopic approach general anesthesia is required which lengthens the hospital stay [14]. However transabdominal percutaneous RF can be applied under sedation and allows rapid recovery and early restoration of the daily activities. In a previous report, percutaneous RF ablation with ultrasound guidance was found to be feasible in symptomatic patients with fibroids 4–6 cm in diameter [6]. In another study women with symptomatic single or multiple fibroids underwent percutaneous RF and followed for six months. RFA was successful regarding to decreasing fibroid volume, relieving symptoms and increasing quality of life [11]. Those two previously mentioned studies were conducted with limited number of patients (9 and 11) and follow up interval was short. In another study with women with large subserosal or intramural fibroids (> 5 cm), the combined treatment with RF following UAE improved symptom severity scores significantly and mean volume reduction was 56.5% [15]. In our study, the number of patients included was relatively higher than the previous reports and the size and number of the fibroids were varying in a larger range (4.4–12 cm). In previous reports, it was postulated that RFA was more effective in volume reduction in intramural fibroids compared to submucosal ones [6]. In accordance with those data, the post treatment mean longest diameter and volume of the fibroids were smaller in intramural fibroids compared to submucosal ones and volumetric response to RFA was better in intramural fibroids in our study. However, the number of patients with submucosal polyps was small and not enough to draw a definitive conclusion. RFA was found to be safe with mild to moderate complications including abdominal pain and skin erythema on the entry site of the needle or urinary tract infection easily managed with oral antibiotics and mild vaginal bleeding. RFA significantly reduced the fibroid size and volume and none of the patients required subsequent treatments in one year of follow up. The fibroid size and volume were significantly lower than basal measurements but there wasn't any significant difference between post RF 3, 6 and 12 month measurements. The volume reduction was most prominent on the 6<sup>th</sup> month visit and median percentage of reduction was 50% (min–max; 2–92). This reduction is slightly inferior to that shown by Bergamini et al. (77%) and Ghezzi et al. [16, 17] (68.8%) which may be related with the larger sizes of the fibroids in our study compared to previous ones and usage of US as the only imaging modality rather than more precise and less subjective ones such as MRI. There are studies in the literature using different imaging modalities such as contrast enhanced US or MRI [18, 19]. An MRI is particularly useful to define the exact location of fibroids, being highly accurate in problematic cases, such as large (> 375 mL), fundal or multiple (> 4) fibroids [20]. In the present study,

menstrual bleeding score decreased significantly. According to self-assessment scores made before and after ablation, the number of patients who were experiencing severe menstrual bleeding decreased significantly. That result was also reflected as increased Hb and Htc levels in the post ablation follow ups. VAS for menstrual pain was also reduced which would increase the quality of life.

In our study, the fibroids were in various locations and some were difficult to reach and manipulate. Since the radiologist was experienced and skilled, those challenging locations didn't constitute an obstacle for RFA. In order to gain experience, it is advised to choose initial cases with one to three fundal myoma [21].

The limitation of our study was the limited number of patients. We need further studies with larger number of patients and with longer follow up to ensure that the volume reduction effect is durable and recurrent symptoms don't reoccur by time. There is also need for further studies to provide information about the possible effects on endometrium or future gestations.

In conclusion, US guided percutaneous RFA of uterine fibroids is relatively safe and effective procedure. It can be applied to the fibroids with varying localizations and sizes. It effectively reduces volume and obviate a need for more invasive treatment. Besides size reduction, it also ameliorates the symptoms such as pain and heavy bleeding which are reducing the quality of life.

#### **Conflict of interest**

The authors of this article confirm that there is no conflict of interest between authors.

#### **Acknowledgements**

All of us have made a substantial contribution to the information submitted and have read the final manuscript. We have no direct or indirect commercial, financial incentive associated with publishing this article. Each of us acknowledges that he or she participated sufficiently in the work to take public responsibility for its content. We thank the staff of interventional radiology department for assisting us during ablation procedures and help as recording all needed data

#### **REFERENCES**

1. Baird DD, Dunson DB, Hill MC, et al. High cumulative incidence of uterine leiomyoma in black and white women: ultrasound evidence. *Am J Obstet Gynecol.* 2003; 188(1): 100–107, doi: [10.1067/mob.2003.99](https://doi.org/10.1067/mob.2003.99), indexed in Pubmed: [12548202](https://pubmed.ncbi.nlm.nih.gov/12548202/).
2. Cardozo ER, Clark AD, Banks NK, et al. The estimated annual cost of uterine leiomyomata in the United States. *Am J Obstet Gynecol.* 2012; 206(3): 211.e1–211.e9, doi: [10.1016/j.jag.2011.12.002](https://doi.org/10.1016/j.jag.2011.12.002), indexed in Pubmed: [22244472](https://pubmed.ncbi.nlm.nih.gov/22244472/).
3. Ilerardi AM, Savasi V, Angileri SA, et al. Percutaneous High Frequency Microwave Ablation of Uterine Fibroids: Systematic Review. *Biomed Res Int.* 2018; 2018: 2360107, doi: [10.1155/2018/2360107](https://doi.org/10.1155/2018/2360107), indexed in Pubmed: [29511672](https://pubmed.ncbi.nlm.nih.gov/29511672/).

4. Kim CH, Kim SR, Lee HA, et al. Transvaginal ultrasound-guided radiofrequency myolysis for uterine myomas. *Hum Reprod.* 2011; 26(3): 559–563, doi: [10.1093/humrep/deq366](https://doi.org/10.1093/humrep/deq366), indexed in Pubmed: [21216788](https://pubmed.ncbi.nlm.nih.gov/21216788/).
5. Bulun SE. Uterine fibroids. *N Engl J Med.* 2013; 369(14): 1344–1355, doi: [10.1056/NEJMra1209993](https://doi.org/10.1056/NEJMra1209993), indexed in Pubmed: [24088094](https://pubmed.ncbi.nlm.nih.gov/24088094/).
6. Jones S, O'Donovan P, Toub D. Radiofrequency ablation for treatment of symptomatic uterine fibroids. *Obstet Gynecol Int.* 2012; 2012: 194839, doi: [10.1155/2012/194839](https://doi.org/10.1155/2012/194839), indexed in Pubmed: [21961009](https://pubmed.ncbi.nlm.nih.gov/21961009/).
7. Woźniak A, Woźniak S. Ultrasonography of uterine leiomyomas. *Prz Menopauzalny.* 2017; 16(4): 113–117, doi: [10.5114/pm.2017.72754](https://doi.org/10.5114/pm.2017.72754), indexed in Pubmed: [29483851](https://pubmed.ncbi.nlm.nih.gov/29483851/).
8. Guarnaccia MM, Rein MS. Traditional surgical approaches to uterine fibroids: abdominal myomectomy and hysterectomy. *Clin Obstet Gynecol.* 2001; 44(2): 385–400, doi: [10.1097/00003081-200106000-00024](https://doi.org/10.1097/00003081-200106000-00024), indexed in Pubmed: [11345000](https://pubmed.ncbi.nlm.nih.gov/11345000/).
9. Recaldini C, Carrafiello G, Laganà D, et al. Percutaneous sonographically guided radiofrequency ablation of medium-sized fibroids: feasibility study. *AJR Am J Roentgenol.* 2007; 189(6): 1303–1306, doi: [10.2214/AJR.07.2184](https://doi.org/10.2214/AJR.07.2184), indexed in Pubmed: [18029862](https://pubmed.ncbi.nlm.nih.gov/18029862/).
10. Kroon B, Johnson N, Chapman M, et al. Australasian CREI Consensus Expert Panel on Trial evidence (ACCEPT) group. Fibroids in infertility—consensus statement from ACCEPT (Australasian CREI Consensus Expert Panel on Trial evidence). *Aust N Z J Obstet Gynaecol.* 2011; 51(4): 289–295, doi: [10.1111/j.1479-828X.2011.01300.x](https://doi.org/10.1111/j.1479-828X.2011.01300.x), indexed in Pubmed: [21806566](https://pubmed.ncbi.nlm.nih.gov/21806566/).
11. Carrafiello G, Recaldini C, Fontana F, et al. Ultrasound-guided radiofrequency thermal ablation of uterine fibroids: medium-term follow-up. *Cardiovasc Intervent Radiol.* 2010; 33(1): 113–119, doi: [10.1007/s00270-009-9707-3](https://doi.org/10.1007/s00270-009-9707-3), indexed in Pubmed: [19777299](https://pubmed.ncbi.nlm.nih.gov/19777299/).
12. Lee BB, Yu SP. Radiofrequency Ablation of Uterine Fibroids: a Review. *Curr Obstet Gynecol Rep.* 2016; 5(4): 318–324, doi: [10.1007/s13669-016-0183-x](https://doi.org/10.1007/s13669-016-0183-x), indexed in Pubmed: [27917310](https://pubmed.ncbi.nlm.nih.gov/27917310/).
13. Ludwig PE, Huff TJ, Shanahan MM, et al. Pregnancy success and outcomes after uterine fibroid embolization: updated review of published literature. *Br J Radiol.* 2020; 93(1105): 20190551, doi: [10.1259/bjr.20190551](https://doi.org/10.1259/bjr.20190551), indexed in Pubmed: [31573326](https://pubmed.ncbi.nlm.nih.gov/31573326/).
14. Garza Leal JG, Hernandez Leon I, Castillo Saenz L, et al. Laparoscopic ultrasound-guided radiofrequency volumetric thermal ablation of symptomatic uterine leiomyomas: feasibility study using the Halt 2000 Ablation System. *J Minim Invasive Gynecol.* 2011; 18(3): 364–371, doi: [10.1016/j.jmig.2011.02.006](https://doi.org/10.1016/j.jmig.2011.02.006), indexed in Pubmed: [21545960](https://pubmed.ncbi.nlm.nih.gov/21545960/).
15. Kim HS, Tsai J, Jacobs MA, et al. Percutaneous image-guided radiofrequency thermal ablation for large symptomatic uterine leiomyomata after uterine artery embolization: a feasibility and safety study. *J Vasc Interv Radiol.* 2007; 18(1 Pt 1): 41–48, doi: [10.1016/j.jvir.2006.10.010](https://doi.org/10.1016/j.jvir.2006.10.010), indexed in Pubmed: [17296703](https://pubmed.ncbi.nlm.nih.gov/17296703/).
16. Bergamini V, Ghezzi F, Cromi A, et al. Laparoscopic radiofrequency thermal ablation: a new approach to symptomatic uterine myomas. *Am J Obstet Gynecol.* 2005; 192(3): 768–773, doi: [10.1016/j.ajog.2004.10.591](https://doi.org/10.1016/j.ajog.2004.10.591), indexed in Pubmed: [15746670](https://pubmed.ncbi.nlm.nih.gov/15746670/).
17. Ghezzi F, Cromi A, Bergamini V, et al. Midterm outcome of radiofrequency thermal ablation for symptomatic uterine myomas. *Surg Endosc.* 2007; 21(11): 2081–2085, doi: [10.1007/s00464-007-9307-8](https://doi.org/10.1007/s00464-007-9307-8), indexed in Pubmed: [17514400](https://pubmed.ncbi.nlm.nih.gov/17514400/).
18. Zhang J, Feng L, Zhang B, et al. Ultrasound-guided percutaneous microwave ablation for symptomatic uterine fibroid treatment—a clinical study. *Int J Hyperthermia.* 2011; 27(5): 510–516, doi: [10.3109/02656736.2011.562872](https://doi.org/10.3109/02656736.2011.562872), indexed in Pubmed: [21756048](https://pubmed.ncbi.nlm.nih.gov/21756048/).
19. Chudnoff SG, Berman JM, Levine DJ, et al. Outpatient procedure for the treatment and relief of symptomatic uterine myomas. *Obstet Gynecol.* 2013; 121(5): 1075–1082, doi: [10.1097/AOG.0b013e31828b7962](https://doi.org/10.1097/AOG.0b013e31828b7962), indexed in Pubmed: [23635746](https://pubmed.ncbi.nlm.nih.gov/23635746/).
20. Levens ED, Wesley R, Premkumar A, et al. Magnetic resonance imaging and transvaginal ultrasound for determining fibroid burden: implications for research and clinical care. *Am J Obstet Gynecol.* 2009; 200(5): 537.e1–537.e7, doi: [10.1016/j.ajog.2008.12.037](https://doi.org/10.1016/j.ajog.2008.12.037), indexed in Pubmed: [19268886](https://pubmed.ncbi.nlm.nih.gov/19268886/).
21. Turtulici G, Orlandi D, Dedone G, et al. Ultrasound-guided transvaginal radiofrequency ablation of uterine fibroids assisted by virtual needle tracking system: a preliminary study. *Int J Hyperthermia.* 2019; 35(1): 97–104, doi: [10.1080/02656736.2018.1479778](https://doi.org/10.1080/02656736.2018.1479778), indexed in Pubmed: [30012030](https://pubmed.ncbi.nlm.nih.gov/30012030/).

# Challenges on the morbidly obese endometrial cancer surgery: Laparotomy or laparoscopy, lymphadenectomy or no lymphadenectomy?

İbrahim Ferhat Urunsak<sup>1</sup>, Ghanim Khatib<sup>1</sup>, Mehmet Ali Vardar<sup>1</sup>,  
Ahmet Baris Guzel<sup>1</sup>, Umran Kucukgoz-Gulec<sup>1</sup>, Sevtap Seyfettinoğlu<sup>1</sup>

Çukurova University Medical Faculty, Obstetrics and Gynecology Department, Adana, Turkey

## ABSTRACT

**Objectives:** A considerable proportion of endometrial cancer patients are morbidly obese. Management of these cases is a serious dilemma. The aim of this study was to investigate the relevance of laparoscopic route and omission of lymphadenectomy as morbidity-reducing strategies in this special population.

**Material and methods:** Endometrial cancer patients' archival records were retrospectively reviewed and cases with body mass index  $\geq 40$  kg/m<sup>2</sup> were selected. A comparative evaluation of their characteristics and survival rates were performed. Firstly, according to the surgical approach; laparoscopy or laparotomy, and then regarding to performing lymphadenectomy or not.

**Results:** There were 146 patients enrolled in this study. Whereas, significantly higher postoperative complications and longer hospital stays were determined in the laparotomy compared to laparoscopy groups. Five years disease-free and overall survival were not significantly different (83.6% vs 70.7%,  $p = 0.184$  and 83.9% vs 86.6%,  $p = 0.571$ , respectively). On the other hand, operation length, postoperative hospitalization time, both intraoperative and postoperative complications were significantly lower in the non-lymphadenectomy compared to the lymphadenectomy groups. However, five-years disease-free and overall survival were not significantly different (77.3% vs 81.3%,  $p = 0.586$  and 87.5% vs 78%,  $p = 0.479$ , respectively).

**Conclusions:** Laparoscopic approach and omission of lymphadenectomy are worthy policies in the morbidly obese endometrial cancer patients.

**Key words:** laparoscopic surgery; lymphadenectomy; morbid obesity; endometrial cancer; oncologic outcomes

Ginekologia Polska 2020; 91, 8: 453–459

## INTRODUCTION

Obesity and particularly morbid obesity is a widening issue around the world. The World Health Organization (WHO) had identified morbid obesity as patients with body mass index more than 40 kg/m<sup>2</sup> [1]. The robust association between obesity and endometrial cancer risk has been emphasized in many studies [2–4]. It was reported that morbidly obese patients have nine times increased risk for endometrial cancer comparing to the normal-weight population [3]. Furthermore, 19% to 36% of the endometrial cancer patients were reported to be morbidly obese [5]. Inadequate activity and obesity-linked medical comorbidities in the morbidly obese endometrial cancer patients were supposed to have contributed in their management complexity [5]. Actually, not just the surgery of the morbidly obese endometrial

cancer cases, but dealing with all of their health procedures including examination, evaluation with imaging methods, per-operative and postoperative morbidity and complications, is a serious predicament.

Surgery representing in total hysterectomy and bilateral salpingo-oophorectomy (TH-BSO) with or without lymphadenectomy  $\pm$  omentectomy is the cornerstone of the endometrial cancer treatment [6]. Surgery can be performed via laparotomy, robotic assisted or conventional laparoscopy. Since minimal invasive surgery has been proven effective in improving the perioperative and postoperative outcomes without compromising survival, it was incorporated in the surgical management of endometrial cancer throughout the last two decades [7]. Besides, laparoscopic surgery had been validated for the long-term outcomes of low risk as

Corresponding author:

Ghanim Khatib

Çukurova University Medical Faculty, Obstetrics and Gynecology Department, Adana, Turkey  
e-mail: ghanim.khatib@gmail.com

well as high-risk endometrial cancer cases in many studies [8]. However, morbidly obese patients are a colossal obstacle for all surgical approaches.

While a lymphadenectomy is beneficial for more precise adjuvant treatment triage by obtaining thorough stage designation and prognosis prediction of the EC patients, there is no consensus regarding its therapeutic benefit [9]. In addition, extent (pelvic or pelvic-paraaortic — until the inferior mesenteric artery or up to the left renal vein), manner and technique (full dissection or sampling, based on frozen section or sentinel node) of the lymphadenectomy are controversial, also [9, 10]. Hitherto, therapeutic impact of the lymphadenectomy in the EC was shown only by retrospective studies and was not confirmed by the randomized prospective studies [9–11].

Medically, morbidly obese EC patients are a high risk special population along all their treatment phases. Therefore, morbidity-reducing strategies are essential in these cases. However, such strategies should not harm the long-term oncological outcomes of these patients. In this study we investigated whether choosing the laparoscopic route and omission of the lymphadenectomy are or not appropriate policies in the morbidly obese EC patients.

## MATERIAL AND METHODS

The archival records and pathological reports of the endometrial cancer cases, who were operated and followed up in Çukurova University Gynecologic Oncology Center between January 2008 and December 2018, were reviewed, retrospectively. Patients with body mass index  $\geq 40$  kg/m<sup>2</sup> were selected for this study. Body mass index [weight (kg)/height (m<sup>2</sup>)] was calculated and classified according to the WHO guidelines. Demographic, clinical, surgical, pathological and follow-up data concerning to these patients were obtained. Comparative evaluations of the patients' characteristics and survival rates were performed, firstly according to the surgical approach; laparoscopy or laparotomy, and then whether or not to perform a lymphadenectomy. Compared variables included age, body mass index (BMI), comorbidities, surgical approach, surgical procedure, operation time, perioperative and postoperative complications, hospitalization time, histological type, stage, grade, myometrial invasion (MI), retroperitoneal lymph node involvement, lymphovascular invasion (LVI), adjuvant treatments and follow-up data. A routinely informed consent was taken from all participants. An approval for this study was obtained from the local committee.

In general, surgery was performed laparoscopically or by laparotomy based on the patient's choice. The main surgical procedures were total hysterectomy-bilateral salpingo-oophorectomy with or without pelvic and para-aortic lymphadenectomy. While, all cases underwent TH-BSO, the

decision of performing a lymphadenectomy and its extent (pelvic or pelvic and paraaortic) was taken upon the case's medical performance, the surgical facility and intraoperative frozen section result. The frozen section was performed in all cases and it was the main router for the lymphadenectomy decision. Hence, a lymphadenectomy was not considered for patients with, stage 1a, FIGO grade 1–2, < 2 cm endometrioid tumors (low-risk factors). In the presence of any of the following circumstances: endometrioid adenocarcinoma grade 3, tumor diameter > 2 cm,  $\geq 50\%$  myometrial invasion, stage > 1a or non-endometrioid histologies, a lymphadenectomy was performed in medically and surgically eligible cases. In the case of FIGO grade 1–2 endometrioid adenocarcinoma with < 50% MI and > 2 cm tumor, only a pelvic lymphadenectomy was carried out. An omentectomy was administered to patients with non-endometrioid histology and in case of omental involvement. Pelvic lymphadenectomy was defined as removing bilaterally the lymph nodes located from the circumflex iliac vein to the iliac bifurcation along the external iliac vessels, the nodes along the internal iliac vessels, and within the interiliac distance and the obturator fossa. In addition to the lymph nodes described above as pelvic lymphadenectomy, resection of the lymph nodes located from the bifurcations of the common iliac vessels up to the left renal vein including; presacral, caval, aortocaval, periaortic, left paraaortic (below and above the inferior mesenteric artery), and right paracaval fields, was identified as pelvic and paraaortic lymphadenectomy.

All specimens were assessed by expert gynecologic pathologists. Comorbidities were accepted as any concomitant chronic disease. International Federation of Gynecology and Obstetrics FIGO 2009 staging guideline for endometrial cancer was utilized. Stages of cases operated before 2009 were rearranged accordingly. Grade was also identified according to 1988 FIGO grading system. Adjuvant therapies (brachytherapy, external beam radiotherapy and/or chemotherapy) were considered for patients with  $\geq$  intermediate risk factors. The period between date of the histopathologic diagnosis and recurrence was identified as disease-free survival. Overall survival was defined as time between date of histopathologic diagnosis and date of death from any cause.

Data were analyzed using SPSS software version 23.0 (IBM, Armonk, NY, USA). Descriptive analyses were presented as mean  $\pm$  standard deviation, number and percentage. Normally distributed continuous variables were analyzed using student t-test. Categorical data were analyzed using Chi-square test or Fisher's exact test. Survival analysis were realized with Kaplan–Meier method and the differences in the survival curves were calculated through the log-rank test. P value was considered significant at the level < 0.05.

## RESULTS

During the study period, 146 patients were determined to be eligible for recruitment to this study. Two different comparisons were performed to the study population: Firstly, according to the surgical route and then in regard to applying a lymphadenectomy or not. There were 65 cases in the laparotomy (LT) and 81 in the laparoscopy (LS) groups. Comparison between patients concerning their surgical approach is summarized in Table 1. Patients' mean age was  $58.94 \pm 11.4$  and  $58.18 \pm 8.9$  in the LT and LS groups, respectively ( $p = 0.652$ ). The average BMI of the LT group ( $44.37 \pm 4.8$ ) was significantly lower comparing to the LS group ( $46.13 \pm 5.3$ ) ( $p = 0.042$ ). Significant proportion of both groups had comorbidities, 60.3% of the LT and 67.9% of the LS group ( $p = 0.345$ ). While, a lymphadenectomy

was performed in 26 (40%) (pelvic and paraaortic: 18, only pelvic: 8) cases of the LT group, it was only carried out in 14 (17.3%) (pelvic and paraaortic: 8, only pelvic: 6) cases of the LS group ( $p = 0.007$ ). There were no significant differences between groups with respect to the operation time (LT:  $96.0 \pm 32.6$ , LS:  $89.5 \pm 41.1$ ,  $p = 0.303$ ). Whereas, no significant differences between LT and LS groups were noted regarding to the intraoperative complications ( $p = 0.915$ ), there were significantly higher postoperative complications in the LT group comparing to the LS group (15.9% vs 1.2%, respectively,  $p = 0.002$ ). Wound infection was the most encountered postoperative complication among the LT patients. The mean of postoperative hospital stay was significantly longer in the LT group ( $5.42 \pm 3.3$ ) comparing to the LS group ( $3.07 \pm 1.0$ ) ( $p < 0.001$ ). Most of the patients

**Table 1.** Comparison between patients concerning to their surgical approach

Variables (mean $\pm$ SD)	Laparotomy	Laparoscopy	p	
Age [years]	$58.94 \pm 11.4$	$58.18 \pm 8.9$	0.652	
Body Mass Index [kg/m <sup>2</sup> ]	$44.37 \pm 4.8$	$46.13 \pm 5.3$	0.042	
Operation time [minute]	$96.0 \pm 32.6$	$89.5 \pm 41.1$	0.303	
Postoperative hospitalization time [day]	$5.42 \pm 3.3$	$3.07 \pm 1.0$	< 0.001	
	N (%)	N (%)		
Comorbidities	No	25 (39.7)	26 (32.1)	0.345
	Yes	38 (60.3)	55 (67.9)	
Intraoperative complications	No	63 (97.0)	78 (96.3)	0.915
	Yes	2 (3.0)	2 (3.7)	
Postoperative complications	No	53 (84.1)	80 (98.8)	0.002
	Yes	10 (15.9)	1 (1.2)	
LND	No	39 (60.0)	67 (82.7)	0.007
	Pelvic	8 (12.3)	6 (7.4)	
	Pelvic + Paraaortic	18 (27.7)	8 (9.9)	
Histopathology	Endometrioid	50 (76.9)	69 (85.2)	0.201
	Non-endometrioid	15 (23.1)	12 (14.8)	
Grade	1	27 (48.2)	52 (65.8)	0.118
	2	25 (44.6)	24 (30.4)	
	3	4 (7.1)	3 (3.8)	
Stage	Uterus confined (stage 1–2)	51 (78.5)	76 (93.8)	0.006
	Extrauterine spread (stage 3–4)	14 (21.5)	5 (6.2)	
MI	< 50	39 (60.9)	52 (70.3)	0.249
	$\geq 50$	25 (39.1)	22 (29.7)	
LVSI	No	33 (51.6)	61 (76.3)	0.004
	Yes	31 (48.4)	19 (23.8)	
LN involvement	Negative	56 (88.9)	68 (98.6)	0.020
	Positive	7 (11.1)	1 (1.4)	
Adjuvant treatments	No	31 (48.4)	57 (71.3)	0.005
	Yes	33 (51.6)	23 (28.8)	

LT — laparotomy; LS — laparoscopy; SD — Standard deviation; LND — lymph node dissection; MI — myometrial invasion; LVSI — lymphovascular space invasion

in both groups had endometrioid histology (76.9% of the LT and 85.2% of the LS,  $p = 0.201$ ). Grade distribution was similar between groups ( $p = 0.118$ ). Rate of advanced stage (3–4) disease was 21.5% and 6.2% in the LT and LS groups, respectively ( $p = 0.006$ ). MI was  $\geq 1/2$  in 25 (39.1%) and 22 (29.7%) cases in the LT and LS groups respectively, without significant differences ( $p = 0.249$ ). LVSI was observed in 48.4% of the LT group and 23.8% of the LS group ( $p = 0.004$ ). Lymph node (LN) was involved in 7 (11.1%) cases of the LT group and 1 case (1.4%) of the LS group ( $p = 0.020$ ). Adjuvant treatments were administered to 33 (51.6%) and 23 (28.8%) patients of the LT and LS groups, respectively ( $p = 0.005$ ).

Comparison between patients with respect to adding lymphadenectomy or not to the surgical procedure is summarized in Table 2. The mean age of the non-lymphadenectomy and lymphadenectomy groups were  $57.88 \pm 10.4$  and  $60.26 \pm 8.8$ , respectively without significant differences

( $p = 0.210$ ). Comorbidity rates were also identical between the groups (62.5% vs 70% respectively,  $p = 0.399$ ). The average BMI was  $45.87 \pm 5.3$  in the non-lymphadenectomy group and  $43.96 \pm 4.5$  in the lymphadenectomy group ( $p = 0.034$ ). While, laparotomy was the surgical method of 36.8% and 65% of the non-lymphadenectomy and lymphadenectomy groups, respectively, laparoscopy was the surgical route for the rest cases ( $p = 0.002$ ). The mean operation time was significantly lower in the non-lymphadenectomy group compared to the lymphadenectomy group ( $79.9 \pm 27.3$  vs  $125.1 \pm 41.3$ , respectively,  $p < 0.001$ ). Both intraoperative (2.8% vs 5%,  $p = 0.040$ ) and postoperative (2.8% vs 21%,  $p = 0.001$ ) complications were significantly lower in the non-lymphadenectomy group compared with the lymphadenectomy group. The average of postoperative hospitalization time was also significantly lower in the non-lymphadenectomy group compared to the lymphadenectomy

**Table 2.** Comparison between patients according to lymphadenectomy

Variables (mean $\pm$ SD)	No lymphadenectomy	Lymphadenectomy	p	
Age [years]	$57.88 \pm 10.4$	$60.26 \pm 8.8$	0.210	
Body Mass Index [kg/m <sup>2</sup> ]	$45.87 \pm 5.3$	$43.96 \pm 4.5$	0.034	
Operation time [minute]	$79.9 \pm 27.3$	$125.1 \pm 41.3$	< 0.001	
Postoperative hospitalization time [day]	$3.37 \pm 1.1$	$6.1 \pm 4.0$	< 0.001	
	N (%)	N (%)		
Comorbidities	No	39 (37.5)	12 (30.0)	0.399
	Yes	65 (62.5)	28 (70.0)	
Treatment	Laparotomy	39 (36.8)	26 (65.0)	0.002
	Laparoscopy	67 (63.2)	14 (35.0)	
Intraoperative complications	No	103 (97.2)	38 (95.0)	0.040
	Yes	3 (2.8)	2 (5.0)	
Postoperative complications	No	103 (97.2)	30 (79.0)	0.001
	Yes	3 (2.8)	8 (21.0)	
Histopathology	Endometrioid	88 (83.0)	31 (77.5)	0.444
	Non-endometrioid	18 (17.0)	9 (22.5)	
Grade	1	66 (65.3)	13 (38.2)	0.018
	2	30 (29.7)	19 (55.9)	
	3	5 (5.0)	2 (5.9)	
Stage	Uterus confined (stage 1–2)	97 (91.5)	30 (75.0)	0.008
	Extrauterine spread (stage 3–4)	9 (8.5)	10 (25.0)	
MI	< 50	72 (72.0)	19 (50.0)	0.015
	$\geq 50$	28 (28.0)	19 (50.0)	
LVSI	No	76 (73.1)	18 (45.0)	0.001
	Yes	28 (26.9)	22 (55.0)	
LN involvement	Negative		32 (82.1)	
	Positive		7 (17.9)	
Adjuvant treatments	No	73 (70.2)	15 (37.5)	< 0.001
	Yes	31 (29.8)	25 (62.5)	

SD — Standard deviation; MI — myometrial invasion; LVSI — lymphovascular space invasion; LN — lymph node



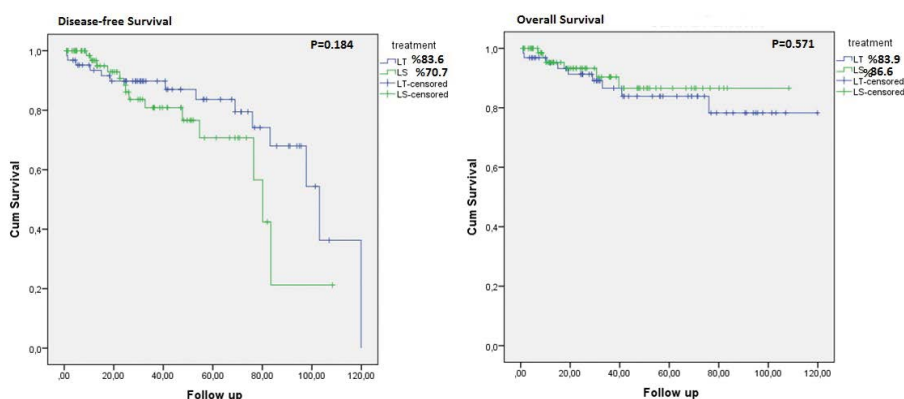


Figure 1. DFS and OS of the LS and LT groups

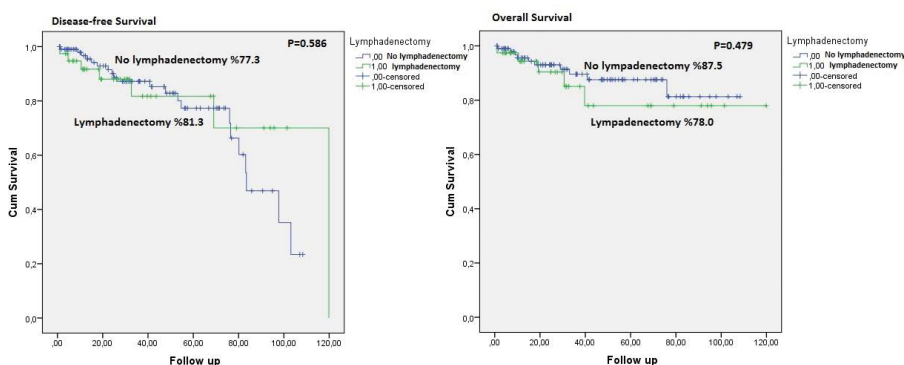


Figure 2. DFS and OS of the lymphadenectomy and non-lymphadenectomy groups

group ( $3.37 \pm 1.1$  vs  $6.1 \pm 4.0$ , respectively,  $p < 0.001$ ). Endometrioid type endometrial cancer consisted 83% of the non-lymphadenectomy patients and 77.5% of the lymphadenectomy group. With respect to the histopathological type, no significant differences were determined between groups ( $p = 0.444$ ). Whereas, the majority of cases in the non-lymphadenectomy group was grade 1 (65.3%) and significant proportion of the lymphadenectomy group was grade 2 (55.9%), both groups had similar rates of grade 3 cases (5% and 5.9%, respectively). Most of the cases in both groups were confined to the uterus, only 8.5% and 25% of the non-lymphadenectomy and lymphadenectomy groups, respectively, were determined to have extrauterine disease ( $p = 0.008$ ). Myometrium was invaded  $\geq 1/2$  in 28% and 50% of the non-lymphadenectomy and lymphadenectomy groups, respectively ( $p = 0.015$ ). The ratio of lymphovascular invasion was 26.9% in the patients who did not undergo a lymphadenectomy and 55% in patients who underwent lymphadenectomy ( $p = 0.001$ ). Among patients who underwent a lymphadenectomy, seven (17.9%) cases harbored positive LNs. Adjuvant treatments were applied in 31 (29.8%) and 25 (62.5%) patients of the non-lymphadenectomy and lymphadenectomy group, respectively ( $p < 0.001$ ).

The mean of the follow-up period was 51 months. Five-years disease-free survival (DFS) and overall survival (OS) rates of the LT and LS groups were 83.6% vs 70.7% ( $p = 0.184$ ), and 83.9% vs 86.6% ( $p = 0.571$ ), respectively (Fig. 1). Five-year DFS and OS rates of the non-lymphadenectomy and lymphadenectomy groups were 77.3% vs 81.3% ( $p = 0.586$ ), and 87.5% vs 78% ( $p = 0.479$ ), respectively (Fig. 2). A multivariate analysis was performed, and only age (HR: 1.105, 1.034–1.182) with histology (HR: 3.262, 1.017–10.463) for DFS and stage (HR: 7.182, 1.310–39.393) for OS were determined as independent prognostic factors (Tab. 3).

## DISCUSSION

The morbidly obese patients are known for their high risk for endometrial cancer. However, endometrial cancer tends to have low grade, early stage, endometrioid type and good prognosis, in this special population [2, 3, 12]. Nevertheless, treatment of these patients encompasses high risk of many morbidities such as; hemodynamic instability, tension pneumothorax, wound infection, healing, and thrombosis [13]. Hence, operating, postoperative management and dealing with possible complications of these cases are serious dilemmas. Furthermore, the increased healthcare

**Table 3. Multivariate analysis of the patients' DFS and OS**

Covariates	HR (95.0% CI)	
	DFS	OS
Age	1.105 (1.034–1.182)	1.045 (0.966–1.131)
Comorbidities	0.832 (0.306–2.258)	3.585 (0.524–24.513)
Surgical route	1.686 (0.692–4.111)	1.289 (0.326–5.102)
Stage	0.631 (0.070–5.726)	7.182 (1.310–39.393)
Grade	1.616 (0.681–3.837)	1.534 (0.497–4.735)
Histology	3.262 (1.017–10.463)	1.843 (0.416–8.156)
MI	1.889 (0.296–12.079)	1.607 (0.195–13.256)
LVSI	0.298 (0.080–1.103)	0.191 (0.030–1.202)
LN involvement	8.285 (0.704–97.467)	1.143 (0.400–3.262)
Adjuvant treatments	1.115 (0.175–7.097)	2.655 (0.309–22.792)

DFS — disease-free survival; OS — overall survival; HR — hazard ratio; CI — confidence interval; MI — myometrial invasion; LVS — lymphovascular space invasion; LN — lymph node dissection

utilization in these cases leads to high costs. Therefore, optimal treatment to minimize the morbidity of these patients is essential. Herein, two morbidity-reducing strategies for this population (laparoscopic surgery and omitting lymphadenectomy) were suggested and tested in this study. No significant difference was observed in term of both DFS and OS between LT and LS groups, in the current study. Similarly, both of DFS and OS did not significantly differ whether lymphadenectomy was performed or not.

Laparoscopic surgery is recommended as –level of evidence: I, strength of recommendation: A- for the management of low and intermediate risk endometrial cancer according to the European guidelines [14]. In addition, several studies have demonstrated the efficacy and oncological safety of laparoscopy in the high-risk endometrial cancer [8, 15]. Nevertheless, there are no randomized prospective trials nor sufficient researches on the oncological safety of the surgical approach for endometrial cancer that exclusively concentrates on the morbidly obese patients [16, 17]. Lower blood loss, less pain, lower postoperative complications, shorter hospital stay and recovery, and less cost are well-known advantages of laparoscopic surgery comparing to the laparotomy [6]. Cheng et al. [16] postoperative complications, length of hospital stay, blood loss and need of transfusion were significantly lower in the morbidly obese endometrial cancer patients who were treated with LS comparing to those with open surgery. Mendivil and colleagues, [13] also reported a shorter postoperative hospitalization period and less blood loss with minimally invasive surgery (MIS) relative to the open surgery in the morbidly obese endometrial cancer cases. Similarly, comparing to laparotomy MIS was linked to less intraoperative and postoperative complications including: blood transfusions, mechanical

ventilation, urinary and gastrointestinal injuries, wound infection, thromboembolism, and lymphedema for the morbidly obese endometrial cancer population in a comparative analysis by Chan et al. [18] Compatible with these results, LS was associated with significantly lower postoperative complications and shorter postoperative hospitalization time in the current study. Beside the advantages of the short-term surgical results, long-term oncologic outcomes were shown to be comparable between the LS and LT arms, in the present study.

The lymphadenectomy in endometrial cancer is beneficial for accurate staging, prognosis prediction and more precise adjuvant treatments selection [10]. However, its therapeutic utility remains controversial since it has never been proven by the prospective studies [9, 10]. Furthermore, a benefit of the lymphadenectomy in term of disease-free survival (HR: 1.23, 95% GA: 0.96–1.58) or overall survival (HR: 1.07, 95% GA: 0.81–1.43) was not reported in the last 2017 updated Cochrane review on the role of lymphadenectomy in endometrial cancer [9]. On the other hand, surgery related systemic morbidity (RR: 3.72, 95% GA: 1.04–13.27) and formation of lymphocyst/lymphedema (RR: 8.39, 95% GA: 4.06–17.33) were clearly increased in the lymphadenectomy patients comparing to the non-lymphadenectomy [9]. Even a lymphadenectomy in the morbidly obese endometrial cancer is an applicable procedure in high-volume qualified centers; it still harbors (particularly para-aortic part) serious surgical difficulties and morbidities [3, 17]. Therefore, simply we argued that if there is no survival benefit of lymphadenectomy procedures in this risky population, it is reasonable to neglect lymphadenectomies in these patients. In our study, patients who underwent a lymphadenectomy were compared with those who did not, and no significant difference was obtained between groups in terms of both DFS and OS. However, it should be noted that the insufficient number of intermediate/high risk or type two cases in our study had restricted us to perform a sub-analysis concerning these patients.

Through this investigation, laparoscopic surgery and omitting lymphadenectomy in the morbidly obese endometrial cancer were found effective as morbidity-reducing strategies without harming the survival outcome. In addition, remarkable reduction in the total cost could be achieved with these strategies, due to the decreased procedures and morbidities. However, this argument needs to be supported by a cost-effectiveness analysis, which was not performed in the current study. Withal, the retrospective nature and its potential biases were the main weaknesses of our study. On the contrary, restricting the study population to morbidly obese women (BMI of 40 kg/m<sup>2</sup> or more), operating and evaluation of all cases by the same team of gynecological oncologists and gynecological pathologists from single

academic center, and the long follow-up period were the main strengths.

In conclusion, parallel to our study results, laparoscopy should be preferred, and lymphadenectomy could be omitted in the morbidly obese endometrial cancer patients.

### Acknowledgement

Authors thank Dr. Reyhan Khatib for editing.

### REFERENCES

1. Managing and Preventing Obesity. 2015, doi: [10.1016/c2013-0-16456-2](https://doi.org/10.1016/c2013-0-16456-2).
2. Arem H, Irwin ML. Obesity and endometrial cancer survival: a systematic review. *Int J Obes (Lond)*. 2013; 37(5): 634–639, doi: [10.1038/ijo.2012.94](https://doi.org/10.1038/ijo.2012.94), indexed in Pubmed: [22710929](https://pubmed.ncbi.nlm.nih.gov/22710929/).
3. Pavelka JC, Ben-Shachar I, Fowler JM, et al. Morbid obesity and endometrial cancer: surgical, clinical, and pathologic outcomes in surgically managed patients. *Gynecol Oncol*. 2004; 95(3): 588–592, doi: [10.1016/j.ygyno.2004.07.047](https://doi.org/10.1016/j.ygyno.2004.07.047), indexed in Pubmed: [15581968](https://pubmed.ncbi.nlm.nih.gov/15581968/).
4. von Gruenigen VE, Tian C, Frasure H, et al. Treatment effects, disease recurrence, and survival in obese women with early endometrial carcinoma : a Gynecologic Oncology Group study. *Cancer*. 2006; 107(12): 2786–2791, doi: [10.1002/ncr.22351](https://doi.org/10.1002/ncr.22351), indexed in Pubmed: [17096437](https://pubmed.ncbi.nlm.nih.gov/17096437/).
5. Bouwman F, Smits A, Lopes A, et al. The impact of BMI on surgical complications and outcomes in endometrial cancer surgery—an institutional study and systematic review of the literature. *Gynecol Oncol*. 2015; 139(2): 369–376, doi: [10.1016/j.ygyno.2015.09.020](https://doi.org/10.1016/j.ygyno.2015.09.020), indexed in Pubmed: [26407479](https://pubmed.ncbi.nlm.nih.gov/26407479/).
6. Zullo F, Falbo A, Palomba S. Safety of laparoscopy vs laparotomy in the surgical staging of endometrial cancer: a systematic review and metaanalysis of randomized controlled trials. *Am J Obstet Gynecol*. 2012; 207(2): 94–100, doi: [10.1016/j.ajog.2012.01.010](https://doi.org/10.1016/j.ajog.2012.01.010), indexed in Pubmed: [22340944](https://pubmed.ncbi.nlm.nih.gov/22340944/).
7. Walker JL, Piedmonte MR, Spirtos NM, et al. Recurrence and survival after random assignment to laparoscopy versus laparotomy for comprehensive surgical staging of uterine cancer: Gynecologic Oncology Group LAP2 Study. *J Clin Oncol*. 2012; 30(7): 695–700, doi: [10.1200/JCO.2011.38.8645](https://doi.org/10.1200/JCO.2011.38.8645), indexed in Pubmed: [22291074](https://pubmed.ncbi.nlm.nih.gov/22291074/).
8. Vardar M, Gulec U, Guzel A, et al. Laparoscopic surgery for low, intermediate and high-risk endometrial cancer. *Journal of Gynecologic Oncology*. 2019; 30(2), doi: [10.3802/jgo.2019.30.e24](https://doi.org/10.3802/jgo.2019.30.e24).
9. Frost JA, Webster KE, Bryant A, et al. Lymphadenectomy for the management of endometrial cancer. *Cochrane Database Syst Rev*. 2015; 10(9): CD007585, doi: [10.1002/14651858.CD007585.pub3](https://doi.org/10.1002/14651858.CD007585.pub3), indexed in Pubmed: [26387863](https://pubmed.ncbi.nlm.nih.gov/26387863/).
10. Rungruang B, Olawaiye AB. Comprehensive surgical staging for endometrial cancer. *Rev Obstet Gynecol*. 2012; 5(1): 28–34, indexed in Pubmed: [22582124](https://pubmed.ncbi.nlm.nih.gov/22582124/).
11. Kumar S, Mariani A, Bakkum-Gamez JN, et al. Risk factors that mitigate the role of paraaortic lymphadenectomy in uterine endometrioid cancer. *Gynecol Oncol*. 2013; 130(3): 441–445, doi: [10.1016/j.ygyno.2013.05.035](https://doi.org/10.1016/j.ygyno.2013.05.035), indexed in Pubmed: [23747331](https://pubmed.ncbi.nlm.nih.gov/23747331/).
12. Gunderson CC, Java J, Moore KN, et al. The impact of obesity on surgical staging, complications, and survival with uterine cancer: a Gynecologic Oncology Group LAP2 ancillary data study. *Gynecol Oncol*. 2014; 133(1): 23–27, doi: [10.1016/j.ygyno.2014.01.041](https://doi.org/10.1016/j.ygyno.2014.01.041), indexed in Pubmed: [24680587](https://pubmed.ncbi.nlm.nih.gov/24680587/).
13. Mendivil AA, Rettenmaier MA, Abaid LN, et al. A comparison of open surgery, robotic-assisted surgery and conventional laparoscopic surgery in the treatment of morbidly obese endometrial cancer patients. *JSL*. 2015; 19(1): e2014.00001, doi: [10.4293/JSL.2014.00001](https://doi.org/10.4293/JSL.2014.00001), indexed in Pubmed: [25848196](https://pubmed.ncbi.nlm.nih.gov/25848196/).
14. Colombo N, Creutzberg C, Amant F, et al. ESMO-ESGO-ESTRO Endometrial Consensus Conference Working Group. ESMO-ESGO-ESTRO Consensus Conference on Endometrial Cancer: Diagnosis, Treatment and Follow-up. *Int J Gynecol Cancer*. 2016; 26(1): 2–30, doi: [10.1097/IGC.0000000000000609](https://doi.org/10.1097/IGC.0000000000000609), indexed in Pubmed: [26645990](https://pubmed.ncbi.nlm.nih.gov/26645990/).
15. Scaletta G, Dinoi G, Capozzi V, et al. Comparison of minimally invasive surgery with laparotomic approach in the treatment of high risk endometrial cancer: A systematic review. *European Journal of Surgical Oncology*. 2020; 46(5): 782–788, doi: [10.1016/j.ejso.2019.11.519](https://doi.org/10.1016/j.ejso.2019.11.519).
16. Cheng Z, He X, Zhao A, et al. Early endometrial carcinoma therapy in morbid obesity: A retrospective study comparing open and laparoscopic. *Int J Surg*. 2016; 30: 31–34, doi: [10.1016/j.ijso.2016.04.005](https://doi.org/10.1016/j.ijso.2016.04.005), indexed in Pubmed: [27102329](https://pubmed.ncbi.nlm.nih.gov/27102329/).
17. Fornalik H, Zore T, Fornalik N, et al. Can Teamwork and High-Volume Experience Overcome Challenges of Lymphadenectomy in Morbidly Obese Patients (Body Mass Index of 40 kg/m<sup>2</sup> or Greater) with Endometrial Cancer?: A Cohort Study of Robotics and Laparotomy and Review of Literature. *Int J Gynecol Cancer*. 2018; 28(5): 959–966, doi: [10.1097/IGC.0000000000001255](https://doi.org/10.1097/IGC.0000000000001255), indexed in Pubmed: [29621128](https://pubmed.ncbi.nlm.nih.gov/29621128/).
18. Chan JK, Gardner AB, Taylor K, et al. Robotic versus laparoscopic versus open surgery in morbidly obese endometrial cancer patients - a comparative analysis of total charges and complication rates. *Gynecol Oncol*. 2015; 139(2): 300–305, doi: [10.1016/j.ygyno.2015.09.006](https://doi.org/10.1016/j.ygyno.2015.09.006), indexed in Pubmed: [26363212](https://pubmed.ncbi.nlm.nih.gov/26363212/).

# The association between aberrant right subclavian artery and trisomy 21 in a tertiary center in Turkey

Mete Sucu<sup>id</sup>, Mehmet Ozsurmeli<sup>id</sup>, Erol Arslan<sup>id</sup>, Cansun Demir<sup>id</sup>, Cüneyt Evrûke<sup>id</sup>

Cukurova University; Faculty of Medicine; Department of Obstetrics and Gynecology, Adana, Turkey

## ABSTRACT

**Objectives:** We hoped to reveal the frequency of Aberrant Right Subclavian Artery (ARSA) and to find the relationship of isolated/non-isolated ARSA with chromosomal defects and other fetal congenital heart diseases (FCHD) in a heterogeneous population.

**Material and methods:** This was a retrospective cohort study conducted between December 2015 to September 2018. Women admitted for routine ultrasound examination or referred to our hospital for a suspected fetal anomaly were underwent detailed fetal anomaly ultrasonography scan and tested for the presence of ARSA.

**Results:** ARSA was detected in 27 patients and an isolated finding in 13 (48%) cases. Among 13 cases with isolated ARSA, trisomy 21 was diagnosed in 1 case. In the non-isolated group (n: 14, 52%), five cases presented with trisomy 21. There was no significant difference of trisomy 21 frequency between isolated and non-isolated groups (7.6% vs 35.7%,  $p = 0.08$ ). In 3 patients, FCHD was diagnosed and 2 of them had trisomy 21.

**Conclusions:** Our study shows that ARSA can be the only marker in trisomy 21. The examination of the subclavian artery must be a part of the fetal anomaly ultrasonography. Detecting an ARSA should increase the attentiveness of the sonographer to investigate for the other markers of trisomy 21. In the existence of other findings, invasive diagnostic procedures should be offered to the patients, whereas in cases that arsa is the only finding, other risk factors should be investigated to offer karyotyping or cell-free DNA analysis.

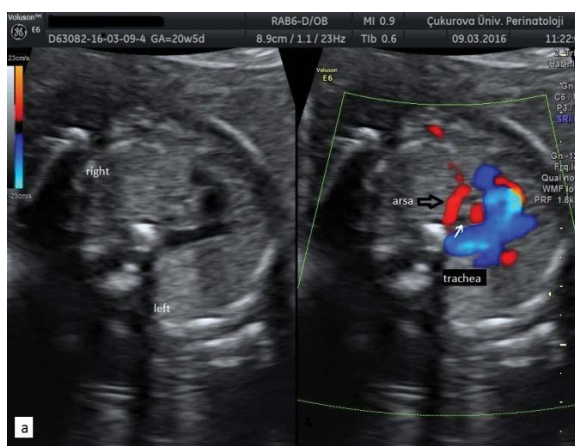
**Key words:** ARSA; trisomy 21; isolated; karyotyping; ultrasound

Ginekologia Polska 2020; 91, 8: 460–464

## INTRODUCTION

Aberrant right subclavian artery (ARSA) is the common seen abnormality or a variant of the aortic arch occurring in 0.5% to 1.4% of the normal adult population [1]. ARSA is featured by different origination of the right subclavian artery from descending aorta directly instead of the brachiocephalic trunk. Normally, the left aortic arch gives three branches, whereas with ARSA four vessels arise from the aortic arch; the right common carotid artery, the left common carotid artery, the left subclavian artery, and the ARSA, respectively [2, 3]. ARSA comes up from the distal portion of the aortic arch, and its route continues backwards the esophagus and the trachea and goes to the right shoulder (Fig. 1A and 1B).

Most of the adult patients with ARSA have no symptoms, and it is usually a benign pathology. However, in some cases, it can cause dysphagia and partial airway obstruction due to the compression esophagus and trachea [4].

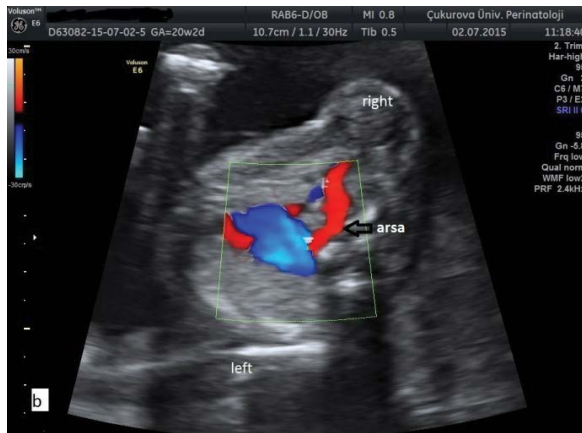

**Figure 1A.** Three-vessel trachea view showing aberrant right subclavian artery arising from the aorta and continuing behind the trachea

### Corresponding author:

Mete Sucu

Cukurova University; Faculty of Medicine; Department of Obstetrics and Gynecology, 01330 Saricam, Adana, Turkey  
phone: +90 322 3386060-3195-3196, fax: 90 322 3386527, mobile: +905056176538  
e-mail: metesucu@yahoo.com



**Figure 1B.** The vessel heads towards the right upper arm

It was reported that ARSA may be a marker for trisomy 21 such as absent nasal bone or thickened nuchal translucency [5–7]. Furthermore, the association between ARSA and 22q11 microdeletion syndrome has also been reported [8]. However, it is important to keep in mind that ARSA can also be an isolated finding without any association with cardiac or extra-cardiac malformations.

In our study we aimed to determine the frequency of isolated/non-isolated ARSA among a heterogenic population and to study its relation with chromosomal abnormalities, as well as different congenital anomalies including fetal congenital heart diseases (FCHD).

## MATERIAL AND METHODS

This was a retrospective cohort study conducted in Cukurova University Faculty of Medicine between December 2015 and September 2018. The study included women attended our Fetal Medicine Clinic for routine second-trimester fetal anomaly scanning or sent to our hospital during the second/third trimester of pregnancy for a possible fetal anomaly or positive aneuploidy screening. All patients underwent a detailed fetal anomaly scan and were checked for the presence of ARSA. The findings of anomaly scan; presence of soft markers, cardiac and extracardiac congenital malformations, were noted. This was a heterogenous population including both low and high-risk patients. All patients were evaluated by four experienced observers using VolusonE6 (GE Medical Systems, Zipf, Austria) with a transabdominal 4–8-MHz probe. The study was approved by the local ethics committee of Cukurova University Faculty of Medicine (approval number: 02.02.2018 74-2). All patients gave written informed consent for their data to be used.

Soft USG markers were as increased nuchal fold, hyper-echogenic bowel, echogenic intracardiac focus, hypoplastic/absent nasal bone, renal pyelectasis, shortened long bones (femur-humerus) and choroid plexus cyst.

## Ultrasound technique for the diagnosis of ARSA

The three-vessel-trachea view is optimal for the diagnosis of ARSA. ARSA is demonstrated from the intersection of the aortic arch and ductus arteriosus with a course backward the trachea toward the right shoulder and arm. To demonstrate its anomalous origin on the aortic arch and its retro-tracheal course toward the right shoulder, colour-Doppler must be applied in the three vessels and trachea view [2]. Pulsed-wave Doppler can be used to discriminate ARSA with the azygos vein, which courses to the right of the trachea. When ARSA was detected, it was also confirmed in the longitudinal aortic arc view [3]. These complementary approaches help to confirm the diagnosis of ARSA.

Fetal karyotyping with amniocentesis (cytogenetic analyses and 22q11 microdeletion) was discussed with the parents when ARSA was diagnosed. All maternal-perinatal data were noted during ultrasound examination and after birth. In all cases where the karyotype was not performed prenatally, if the newborn had doubtful characteristics of a chromosomal anomaly, a peripheral blood karyotype test was performed. The karyotype was noted normal if the newborn had normal findings of physical examination. All the patients having a major fetal cardiac abnormality underwent both fetal and postnatal echocardiography by a pediatric cardiologist experienced with diagnosing fetal congenital heart anomalies. The diagnosis of isolated ARSA was done in accordance with the nonexistence of other ultrasound signs suggesting chromosomal abnormalities and/or fetal structural malformations after complete prenatal and postnatal evaluation. All cases of ARSA were confirmed by postnatal echocardiography.

All information of patients (including gestational age at diagnosis, delivery week, karyotype, 22q11 microdeletion, extra-cardiac malformations, additional cardiac findings, and postnatal outcome) were recorded and analyzed.

Descriptive statistics were done using Microsoft Excel. The Chi-square test was used for the comparison. A p-value < 0.05 was considered to indicate statistical significance.

## RESULTS

A total of 5283 fetuses were examined during the second or third trimester of pregnancies for a suspected fetal anomaly or routine ultrasound examination. The median gestational age was 23 weeks at diagnosis. The median age of the patients with ARSA was 30 years. ARSA was detected in 27 cases (0.51%). ARSA was an isolated finding in 13 (48%) cases whereas in 14 cases (52%) ARSA was a non-isolated finding. In three cases (11.1%), ARSA was accompanied by other cardiac defects, whereas in six cases (22.2%) soft sonographic markers were observed. Extracardiac malformations were present in four fetuses (14.8%). In one case (3.7%), only fetal growth restriction (FGR) accompanied ARSA. Clinical, demographic and USG findings are shown in Table 1.

**Table 1.** Cases with aberrant right subclavian artery

	Maternal age [years]	Gestational age at diagnosis [weeks]	Delivery time [weeks]	Additional cardiac findings	Extracardiac findings	Karyotype	22q11.2 microdeletion	Postnatal outcome
1	25	20	42	none	none	normal	negative	Healthy, 15 months old
2	39	22	39	none	none	normal	negative	Healthy, 16 months old
3	26	20	39	none	none	NP	NP	Normal karyotype has dysphagia, 18 months old
4	29	23	39	none	none	NP	NP	Healthy, normal karyotype, 13 months old
5	24	21	37	none	none	Tri21	negative	Tri21, 7 months old
6	34	25	32	none	none	NP	NP	Healthy, normal karyotype, 12 months old
7	32	20	37	none	none	normal	negative	Healthy, 13 months old
8	32	24	38	none	none	normal	negative	Healthy, 11 months old
9	38	20	37	none	none	normal	negative	Healthy, 15 months old
10	27	25	25	AVSD, PLSVC, DORV, PS	SUA	Tri21	negative	Intrauterine exitus
11	21	23	41	none	mild VM	NP	NP	Healthy, normal karyotype, 7 months old
12	27	22	40	none	none	NP	NP	Healthy 6 months old
13	43	20	36	AVSD, BA	mild VM, CLP, SUA	NP	NP	Tri21, 5 months old
14	24	24	41	none	VM, CLP, HB	normal	NP	Postnatal exitus on the 1 <sup>st</sup> day
15	34	25	34	none	MCM, DA, NBH	Tri21	NP	Intrauterine exitus
16	34	21	33	none	CPC, NBH	Tri21	NP	Tri21, 16 months old
17	28	27	37	none	FGR, HB	NP	NP	Healthy, normal karyotype, 9 months old
18	39	23	33	none	NBH, DB, SG, SF	Tri21	NP	Tri 21, 9 months old
19	26	23	40	none	HB, NBH	normal	NP	Unknown
20	35	23	39	none	RP, INF, NBH	normal	NP	6 months old, operated for UPJO
21	21	26	41	none	RP	NP	NP	Healthy, normal karyotype, 30 months old
22	30	22	40	none	none	NP	NP	Healthy, normal karyotype, 28 months old
23	37	19	38	none	INF	normal	NP	Unknown
24	20	24	39	none	none	normal	NP	Healthy, 32 months old
25	31	25	40	none	none	NP	NP	Healthy, normal karyotype, 24 months old
26	33	27	39	none	SUA	normal	NP	Healthy, 36 months old
27	28	21	33	VSD	none	normal	negative	Healthy, 33 months old

NP — not performed; AVSD — atrioventricular septal defect; PLSVC — persistent left superior vena cava; DORV — double outlet right ventricle; PS — pulmonary stenosis; SUA — single umbilical artery; VM — ventriculomegaly; BA — bradycardia; CLP — cleft lip palate; MCM — mega cisterna magna; DA — duodenal atresia; NBH — nasal bone hypoplasia; CPC — choroid plexus cyst; FGR — fetal growth restriction; INF — increased nuchal fold; DB — dilated bowel; SF — short femur; SG — sandal gap; HB — hyperechogenic bowel; RP — renal pelviectasia, VSD — ventricular septal defect; UPJO — ureteropelvic junction obstruction

Prenatal karyotype analyses were performed in seven patients with isolated ARSA (53.8%) and revealed trisomy 21 in 1 case. Postnatal evaluation of other patients with isolated ARSA was normal for trisomy 21.

In the non-isolated group, eight patients (57.1%) accepted prenatal karyotyping, and trisomy 21 was diagnosed

in four cases. In the postnatal evaluation of other six fetuses of the non-isolated group, the karyotype analysis result of five fetuses were noted normal because of the nonexistence of postnatal clinical findings suggesting chromosomal anomaly whereas 1 patient had clinical features of trisomy 21 and karyotype analysis revealed trisomy 21.

The frequency of trisomy 21 was 7.6% (1/13) in the isolated group, and 35.7% (5/14) in the non-isolated group, and the difference was not statistically significant ( $p = 0.08$ ). In total, six cases with the diagnosis of ARSA were found to have trisomy 21 (22%).

In the total study group, 31 fetuses had trisomy21 with the rate of 0.58% (31/5283). Among 31 fetuses with trisomy 21, 6 fetuses had ARSA with the rate of 19.3% (6/31). In one of them ARSA was an isolated finding. ARSA rate was 0.39% (21/5252) in patients without trisomy 21. Trisomy 21 rate of patients with ARSA was 0.222 (6/27) whereas patients without ARSA had a trisomy 21 rate as 0.004% (25/5256) and there was a 47 fold increase of trisomy 21 in patients with ARSA.

## DISCUSSION

The prevalence of ARSA was 0.51% in our study population, which consists of both low and high-risk patients in a tertiary unit in Turkey. ARSA was an isolated finding in 13 of 27 (48%) fetuses. Six fetuses had soft sonographic markers, three fetuses had other cardiac malformations, and four fetuses had extra-cardiac malformations.

There is an ongoing debate about whether invasive diagnostic procedures are indicated when ARSA is noted as an isolated finding. The relationship between ARSA and trisomy 21 was first described by Chaoui et al. [2]. These authors identified ARSA in 35.7% of fetuses with trisomy 21 during the second and third trimester (5 of 14). We identified ARSA in 19.3% of fetuses with trisomy 21. Since then, ARSA was reported as one of the most powerful independent markers of trisomy 21 [7, 9, 10]. Agathokleous et al. [9] reported that trisomy 21 risk was increased about 3- to 4-fold in patients with ARSA but they emphasized that most of the studies in their meta-analysis were done in high-risk pregnancy groups. In our population trisomy 21 rate was 47 fold increased in patients with ARSA.

De Leon-Luis et al. [11] studied a large unselected population and found 60 ARSA cases among 8781 fetuses, with a prevalence of 0.7%, which was higher than our study. Trisomy21 was diagnosed in seven(12%) of the 60 cases, all were in the non-isolated group(21 fetuses) and associated with the strong markers of trisomy21, such as absent or hypoplastic nasal bone, nuchal fold thickness, cystic hygroma, and ventriculomegaly, which also indicate performing karyotype analysis. Trisomy21 rate of their patients with non-isolated ARSA was 33.3% and similar to our study with rate of 35.4%. Whereas in our study isolated ARSA group had a 7.6% trisomy21 rate, in their study no cases of trisomy21 were detected in fetuses with isolated ARSA. We evaluated the role of ARSA without USG markers associated with Trisomy21 and our data suggests that additional markers should be searched in these patients and family should be informed about trisomy21 risk. Even in the patients with

isolated ARSA increased trisomy21 risk must be taken into account.

Paladini et al. [7] studied a large trisomy21 group and found the incidence of 25% for ARSA. Borenstein et al. [12] and Paladini et al. [7] found that ARSA increased the risk of trisomy21 by about 16- to 20-fold.

Paladini et al. [7] diagnosed ARSA in 27 fetuses among the 106 fetuses with trisomy21; ARSA was the only finding in eight (30%) of these fetuses. Similarly we diagnosed ARSA in 6 fetuses among the 31 fetuses with trisomy21 and ARSA was the only finding in one of these cases. Based on these findings, they recommended that prenatal karyotyping analysis could be performed even in the cases of isolated ARSA [7]. Similarly, in the study of Gul et al. [13], the authors found Trisomy21 in one case of nine cases with isolated ARSA. In our study, one case (7.6%) presented with Down syndrome among the 13 cases with isolated ARSA.

While recommending amniocentesis for isolated ARSA cases, other risk factors should also be considered. Similarly, Esmer et al. [14] diagnosed trisomy21 with isolated ARSA in six fetuses; however, four cases had a positive first/second trimester screening test for trisomy21, and the remaining two of them had advanced maternal age. In three previous series, no case of trisomy21 with isolated ARSA was existed[6,15,16]. Yazicioglu et al. [6] concluded that the presence of ARSA without other sonographic findings is not a strong marker to recommend karyotyping and cell-free fetal DNA can be an alternative approach for these patients. In our study 7.6% of patients with isolated ARSA had trisomy21. According to these findings we suggest to explore additional risk factors to offer karyotyping or cell-free fetal DNA.

Our findings show that nasal bone hypoplasia and single umbilical artery were the most frequent additional findings to ARSA, with rates of 18.5% and 11.1%, respectively. Therefore, we agree with the idea of recommending karyotype analyses to the ARSA cases with additional findings. On the other hand, for the cases of isolated ARSA, screening test results should also be taken into account.

The close relationship between conotruncal anomalies and 22q11.2 microdeletion has been shown, especially if aortic arch anomalies (*i.e.*, interrupted aortic arch, tetralogy of Fallot, ARSA, etc.) are existing additionally [8]. In our study, we also investigated the existence of 22q11.2 microdeletion besides the conventional cytogenetic analyses. Eight patients accepted microdeletion analyses, but no cases were detected to have 22q11.2 microdeletion. In the study of Rembouskos et al. [8], 22q11.2 microdeletion was caught in a case of ARSA with increased nuchal translucency. The authors suggested that FISH analyses for this microdeletion can be added to the cytogenetic analyses, even if there are no other cardiac defects that accompany ARSA. We believe that more prospective studies are needed to predicate the

relation between 22q11.2 microdeletion and ARSA without cardiac defects before it becomes an additional routine test.

One of the limitations of our study was the retrospective design of the study and low number of patients used to determine the prevalence of associated structural and chromosomal anomalies, microdeletion 22q11.2. In future work, more patients with isolated ARSA would be needed to determine the value of routine cytogenetic analyses for these patients.

### CONCLUSIONS

In conclusion, the visualization of the right subclavian artery is likely a valuable marker especially in patients with additional USG findings for trisomy 21 and should be a part of extended basic cardiac screening. The detection of ARSA should alert the examiner to seek additional sonographic markers. In existence of other signs suggesting trisomy 21, we must offer invasive diagnostic procedures to the patients. Whereas in isolated cases, risk factors should be incorporated into the discussion about karyotype analyses or cell-free fetal DNA should be considered as a choice.

### Conflict of interest

All authors declared that they have no conflict of interest.

### REFERENCES

- Zapata H, Edwards JE, Titus JL. Aberrant right subclavian artery with left aortic arch: associated cardiac anomalies. *Pediatr Cardiol.* 1993; 14(3): 159–161, doi: [10.1007/BF00795645](https://doi.org/10.1007/BF00795645), indexed in Pubmed: [8415218](https://pubmed.ncbi.nlm.nih.gov/8415218/).
- Chaoui R, Heling KS, Sarioglu N, et al. Aberrant right subclavian artery as a new cardiac sign in second- and third-trimester fetuses with Down syndrome. *Am J Obstet Gynecol.* 2005; 192(1): 257–263, doi: [10.1016/j.ajog.2004.06.080](https://doi.org/10.1016/j.ajog.2004.06.080), indexed in Pubmed: [15672034](https://pubmed.ncbi.nlm.nih.gov/15672034/).
- Chaoui R, Rake A, Heling KS. Aortic arch with four vessels: aberrant right subclavian artery. *Ultrasound Obstet Gynecol.* 2008; 31(1): 115–117, doi: [10.1002/uog.5240](https://doi.org/10.1002/uog.5240), indexed in Pubmed: [18098341](https://pubmed.ncbi.nlm.nih.gov/18098341/).
- Carrizo GJ, Marjani MA. Dysphagia lusoria caused by an aberrant right subclavian artery. *Tex Heart Inst J.* 2004; 31(2): 168–171, indexed in Pubmed: [15212130](https://pubmed.ncbi.nlm.nih.gov/15212130/).
- Hara M, Satake M, Itoh M, et al. Radiographic findings of aberrant right subclavian artery initially depicted on CT. *Radiat Med.* 2003; 21(4): 161–165, indexed in Pubmed: [14514122](https://pubmed.ncbi.nlm.nih.gov/14514122/).
- Fe, Sevket O, Akin H, et al. Aberrant right subclavian artery in Down syndrome fetuses. *Prenat Diagn.* 2013; 33(3): 209–13.
- Paladini D, Sglavo G, Pastore G, et al. Aberrant right subclavian artery: incidence and correlation with other markers of Down syndrome in second-trimester fetuses. *Ultrasound Obstet Gynecol.* 2012; 39(2): 191–195, doi: [10.1002/uog.10053](https://doi.org/10.1002/uog.10053), indexed in Pubmed: [21793087](https://pubmed.ncbi.nlm.nih.gov/21793087/).
- Rembouskos G, Passamonti U, De Robertis V, et al. Aberrant right subclavian artery (ARSA) in unselected population at first and second trimester ultrasonography. *Prenat Diagn.* 2012; 32(10): 968–975, doi: [10.1002/pd.3942](https://doi.org/10.1002/pd.3942), indexed in Pubmed: [22847746](https://pubmed.ncbi.nlm.nih.gov/22847746/).
- Agathokleous M, Chaveeva P, Poon LCY, et al. Meta-analysis of second-trimester markers for trisomy 21. *Ultrasound Obstet Gynecol.* 2013; 41(3): 247–261, doi: [10.1002/uog.12364](https://doi.org/10.1002/uog.12364), indexed in Pubmed: [23208748](https://pubmed.ncbi.nlm.nih.gov/23208748/).
- Scala C, Leone Roberti Maggiore U, Candiani M, et al. Aberrant right subclavian artery in fetuses with Down syndrome: a systematic review and meta-analysis. *Ultrasound Obstet Gynecol.* 2015; 46(3): 266–276, doi: [10.1002/uog.14774](https://doi.org/10.1002/uog.14774), indexed in Pubmed: [25586729](https://pubmed.ncbi.nlm.nih.gov/25586729/).
- De León-Luis J, Gámez F, Bravo C, et al. Second-trimester fetal aberrant right subclavian artery: original study, systematic review and meta-analysis of performance in detection of Down syndrome. *Ultrasound Obstet Gynecol.* 2014; 44(2): 147–153, doi: [10.1002/uog.13336](https://doi.org/10.1002/uog.13336), indexed in Pubmed: [24585513](https://pubmed.ncbi.nlm.nih.gov/24585513/).
- Borenstein M, Minekawa R, Zidere V, et al. Aberrant right subclavian artery at 16 to 23 + 6 weeks of gestation: a marker for chromosomal abnormality. *Ultrasound Obstet Gynecol.* 2010; 36(5): 548–552, doi: [10.1002/uog.7683](https://doi.org/10.1002/uog.7683), indexed in Pubmed: [20503237](https://pubmed.ncbi.nlm.nih.gov/20503237/).
- Gul A, Corbacioglu A, Bakirci IT, et al. Associated anomalies and outcome of fetal aberrant right subclavian artery. *Arch Gynecol Obstet.* 2012; 285(1): 27–30, doi: [10.1007/s00404-011-1907-9](https://doi.org/10.1007/s00404-011-1907-9), indexed in Pubmed: [21487731](https://pubmed.ncbi.nlm.nih.gov/21487731/).
- Esmer AC, Gul A, Nehir A, et al. Detection rate of trisomy 21 in fetuses with isolated and non-isolated aberrant right subclavian artery. *Fetal Diagn Ther.* 2013; 34(3): 140–145, doi: [10.1159/000354650](https://doi.org/10.1159/000354650), indexed in Pubmed: [24051543](https://pubmed.ncbi.nlm.nih.gov/24051543/).
- Willruth AM, Dwinger N, Ritgen J, et al. Fetal aberrant right subclavian artery (ARSA) - a potential new soft marker in the genetic scan? *Ultraschall Med.* 2012; 33(7): E114–E118, doi: [10.1055/s-0029-1245935](https://doi.org/10.1055/s-0029-1245935), indexed in Pubmed: [21614745](https://pubmed.ncbi.nlm.nih.gov/21614745/).
- Zalel Y, Achiron R, Yagel S, et al. Fetal aberrant right subclavian artery in normal and Down syndrome fetuses. *Ultrasound Obstet Gynecol.* 2008; 31(1): 25–29, doi: [10.1002/uog.5230](https://doi.org/10.1002/uog.5230), indexed in Pubmed: [18098348](https://pubmed.ncbi.nlm.nih.gov/18098348/).



# The association of the amniotic fluid index (AFI) with perinatal fetal and maternal outcomes in pregnancies complicated by preterm premature rupture of membranes (PPROM)

Taner Günay<sup>1</sup>, Gamze Erdem<sup>1</sup>, Reyhan Ayaz Bilir<sup>1</sup>, Meryem Hocaoglu<sup>1</sup>,  
 Ozkan Ozdamar<sup>1</sup>, Abdulkadir Turgut<sup>1</sup>

*Medeniyet University Göztepe Training and Research Hospital, Eğitim mah. Dr. Erkin cad. Kadıköy, İstanbul, Turkey*

## ABSTRACT

**Objectives:** To investigate association of amniotic fluid index (AFI) with perinatal fetal and maternal outcomes in pregnancies complicated by preterm premature rupture of membranes (PPROM)

**Material and methods:** A total of 70 singleton pregnancies complicated by PPRM at 23–33 weeks' gestation were enrolled in this prospective observational study. Data on maternal clinical and obstetric characteristics [maternal age, gravidity, parity, PPRM time, and AFI (cm), latency period, treatments, type of delivery, length of hospital stay (LOS, day)], fetal characteristics (gestational age at delivery, birth weight (g), gender) and maternal and fetal complications were recorded and compared in AFI < 5 cm (n = 27) and AFI ≥ 5 cm (n = 21) groups.

**Results:** Overall AFI was ≤ 5 cm in 27 (56.3%) patients and > 5 cm in 21 (43.7%) patients. No significant difference was noted in maternal clinical and obstetric characteristics, gestational age at delivery and gender of the newborn as well as in maternal and fetal complications rates with respect to AFI groups. AFI was correlated positively with latency period (r = 0.399, p = 0.018) and negatively with postpartum LOS (r = -0.314, p = 0.030).

**Conclusions:** In conclusion, our findings seems to indicate increased likelihood of shorter latency to delivery and longer postpartum LOS with decrease in AFI after PPRM between 23–33 weeks' gestation, whereas no impact of AFI on mode of delivery and fetal or maternal complications.

**Key words:** Preterm premature rupture of membranes; amniotic fluid index; fetal outcomes; maternal outcomes

Ginekologia Polska 2020; 91, 8: 465–472

## INTRODUCTION

Premature rupture of fetal membranes (PROM), the leakage of amniotic fluid prior to labour irrespective of gestational age, occurs in 2–25% of all pregnancies, while PROM before 37 weeks of gestation occurs in nearly 3% of all pregnancies and referred to as preterm PROM (PPROM) [1–4].

Early recognition and appropriate treatment of PPRM is crucial for preventing potential adverse perinatal outcomes related to prematurity (*i.e.* neonatal morbidity and mortality) and for minimizing the risk of fetal and maternal complications [3–6]. However, PPRM continues to be a challenging condition in current obstetric practice in terms of controversies regarding the optimal timing and route of delivery to minimize maternal and perinatal morbidity [3, 5].

Amniotic fluid index (AFI), a widely used method for evaluation of fetal well-being, is considered a useful parameter in this regard, given its potential in predicting adverse outcomes, aiding to decide on optimal mode of delivery in pregnancies complicated by PPRM [5, 7, 8]. Accordingly, presence of oligohydramnios (AFI < 5 cm) after PPRM has been suggested to be associated with increased likelihood of adverse fetal (*i.e.* intrauterine growth restriction, fetal distress, pulmonary hypoplasia, respiratory distress syndrome, neonatal sepsis, necrotizing enterocolitis, intraventricular hemorrhage, and bronchopulmonary dysplasia) and maternal (*i.e.* chorioamnionitis) perinatal outcomes, contributing to an increase in neonatal sepsis and mortality [5, 8–12].

### Corresponding author:

Taner Günay  
 Medeniyet University Göztepe Training and Research Hospital, Eğitim mah. Dr. Erkin cad. Kadıköy, 34722 İstanbul, Turkey  
 e-mail: drtanergunay@gmail.com

However, the utility of AFI after PPROM in terms of adverse perinatal outcomes has not been extensively studied along with considerable controversy among the published studies [5, 8, 9, 12–16].

This study was therefore designed to investigate the potential association of AFI with fetal/maternal perinatal adverse outcomes in pregnancies complicated by PPROM.

## MATERIALS AND METHODS

### Study population

A total of 70 singleton pregnancies complicated by PPROM at 23–33 weeks' gestation were enrolled in this prospective observational study conducted at a single tertiary care center between September 2018 and September 2019. Women with singleton, non-anomalous fetuses with suspected diagnosis of PPROM at 23–33 weeks' gestation and amniotic fluid volume assessment at the time of presentation were included in the study. Presence of multiple pregnancy, cerclage major congenital anomaly, oligohydramnios, polyhydramnios, pregnancy-related hypertensive disorder, cervical dilatation  $\geq 6$  cm on admission and delivery within 2 hours of membrane rupture were the exclusion criteria of the study. Accordingly, final study population subjected to analysis was composed of 48 pregnant women due to exclusion of 22 women due to lack of PPROM diagnosis ( $n = 13$ ), multiple pregnancy ( $n = 2$ ), cervical dilatation  $\geq 6$  cm ( $n = 2$ ), hypertensive disease ( $n = 1$ ), cerclage ( $n = 1$ ), lumbar meningocele ( $n = 1$ ), idiopathic polyhydramnios ( $n = 1$ ) and discharge at her own request ( $n = 1$ ) (Fig. 1).

Written informed consent was obtained from each subject following a detailed explanation of the objectives and protocol of the study which was conducted in accordance with the ethical principles stated in the "Declaration of Helsinki" and approved by the institutional ethics committee.

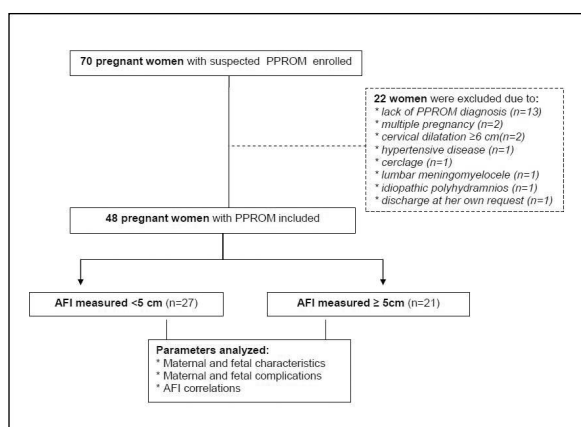


Figure 1. Study flow chart

### Assessments

Data on maternal clinical and obstetric characteristics [maternal age, gravidity, parity, body mass index prior to pregnancy ( $\text{kg}/\text{m}^2$ ), smoking status, PPROM time, amniotic fluid appearance and AFI (cm), latency period (days from rupture of amniotic sac to the delivery), treatments (steroid, magnesium), type of delivery, length of hospital stay (LOS, day)], fetal characteristics (gestational age at delivery, birth weight (g), gender) and maternal complications (placental abruption, retention, endometritis, bleeding, chorioamnionitis, last CRP before delivery, WBC and body temperature) and fetal complications within the first month of post-natal life (ICU stay, sepsis, meconium aspiration, respiratory distress syndrome, grade 3–4 intraventricular hemorrhage, umbilical artery pH level and 5<sup>th</sup> min Apgar score) were recorded. Patients were categorized into 2 groups on the basis of a 4-quadrant AFI  $< 5$  cm ( $n = 27$ ) or  $\geq 5$  cm ( $n = 21$ ), while maternal and fetal characteristics and complications were evaluated with respect to AFI groups and correlation of AFI with other study parameters was analyzed.

### PPROM diagnosis

PPROM diagnosis was based on patient history and physical examination findings including presence of typical gross amniotic fluid leakage history and/or identification of pooling of amniotic fluid in the posterior vaginal vault on sterile speculum examination. In women with suspected anamnesis but without history of gross leakage or positive findings on speculum examination, the diagnosis was made by positivity of placental alpha microglobulin-1 test (Amnisure ROM Test<sup>®</sup>, QIAGEN, USA) in the vaginal fluid. The pregnant women were monitored daily by clinical and obstetric examination, as well as with bacteriology smears and periodic hemogram analysis for screening of infections.

### Calculation of amniotic fluid index (AFI)

AFI was measured ultrasonographically with 4–8 MHz transabdominal convex probe General Electric Voluson (GE Healthcare, Chicago, IL, United States) device and calculated by four quadrant technique, which is sum of the deepest vertical length of pocket of fluid in each quadrant without umbilical cord [17].

### Treatments

All pregnant women received a single course of beta-methasone, consisting of two 12-mg injections during the first 24 hours after admission to induce fetal lung maturation and antibiotic treatment including single dose oral azithromycin (1 g) and *i.v.* ampicillin ( $4 \times 2$  g) within the first 48-h, as followed by oral amoxicillin ( $3 \times 500$  mg) to complete the 7-day antibiotherapy [1]. In women with delivery expected to occur before 32<sup>nd</sup> gestational week, magnesium sulphate

prophylaxis was administered for fetal neuroprotection (a loading dose of 6 g infused for 20–30 minutes followed by a maintenance infusion of 2 g per hour).

Emergency C/S was performed in women with placental abruption and identification of decelerations indicating fetal distress during NST. The decelerations were interpreted in accordance with ACOG Bulletin description.

### Fetal and maternal complications

Fetal and maternal complications were recorded up to 1 month postpartum. Respiratory distress syndrome was defined as a requirement for supplemental oxygen for more than 48 hours with a reticulogranular appearance on chest X-ray. Neonatal sepsis was diagnosed either by positive blood culture or by a combination of clinical signs and laboratory findings, such as leukopenia, thrombocytopenia, and elevated CRP levels. ICU need was considered for at least 24 hours of ICU stay in the neonatal period.

Chorioamnionitis was diagnosed based on increased body temperature ( $> 38^{\circ}\text{C}$ ) accompanied with positivity of at least one of the followings: lower abdominal or uterine tenderness, malodorous amniotic discharge, persistent fetal tachycardia or positive laboratory findings (CRP  $> 0.5$  mg/dL or WBC  $> 20.000$ ) [18]. Postpartum endometritis was diagnosed based on increased body temperature ( $> 38^{\circ}\text{C}$ ) and uterine tenderness and exclusion of other infection foci. Postpartum bleeding was considered in bleedings that cause 10% decline in hematocrit levels or necessitate blood transfusion.

### Statistical analysis

Statistical analysis was made using IBM SPSS Statistics for Windows, version 25.0 (IBM Corp., Armonk, NY, USA). Pearson Chi-Square test (Exact), Fisher Exact test (Exact), Fisher Freeman Halton Test (Monte Carlo) were used to analyze categorical data, while numerical data were analyzed with independent samples-t test (Bootstrap) and Mann Whitney U test (Monte Carlo). Correlation analysis was performed with Spearman's rho test. ROC curve was plotted to determine the role of AFI in predicting fetal birth weight with calculation of area under curve (AUC) and cut-off value via ROC analysis. Data were expressed as median (min–max), 95% confidence interval (CI) and n (%) where appropriate  $p < 0.05$  was considered statistically significant.

## RESULTS

Overall, mean  $\pm$  SD maternal age was  $27.15 \pm 5.04$  years, 54.2% of women were multiparous women. Mean PPRM time was 29.11 (SD 2.22) weeks, while spontaneous vaginal delivery was noted in 81.3% of women. Overall mean  $\pm$  SD AFI was  $4.41 \pm 1.80$  cm, while AFI was  $\leq 5$  cm in 27 (56.3%) patients and  $> 5$  cm in 21 (43.7%) patients. Median latency

period was 8 days (range, 1 to 26 days), while length of postpartum LOS was 2.5 days (range, 1 to 7 days) (Tab. 1).

No significant difference was noted in maternal clinical and obstetric characteristics, gestational age at delivery and gender of the newborn with respect to AFI groups. Latency period and LOS were also similar between AFI  $< 5$  cm and  $\geq 5$  cm groups (Tab. 1).

Fetal birth weight was significantly higher in the AFI  $\geq 5$  cm group as compared with AFI  $< 5$  cm group ( $1622.86 \pm 273.75$  vs  $1440.74 \pm 336.33$ ,  $p = 0.042$ ) (Tab. 1).

### Maternal and fetal complications

Overall, maternal complications were observed in 41.7% of women, including chorioamnionitis (33.3%) and endometritis (25.0%) in most of women (Tab. 2).

Overall, fetal complications were observed in 72.9% of neonates, including 5–min Apgar score  $\leq 5$  (52.1%), ICU stay (66.7%), and respiratory distress syndrome (52.1%) in most of neonates (Tab. 3).

No significant difference was noted in presence, type and number of maternal and fetal complications with respect to AFI groups (Tab. 3).

### Correlation of AFI with other study parameters

AFI was correlated positively with latency period ( $r = 0.399$ ,  $p = 0.018$ ) and negatively with postpartum LOS ( $r = -0.314$ ,  $p = 0.030$ ). No correlation of AFI was noted with maternal age, PPRM time, delivery week or number of maternal and fetal complications (Tab. 4).

## DISCUSSION

Our findings revealed positive correlation of AFI with latency period and association of AFI  $< 5$  cm after PPRM with higher postpartum LOS in pregnancies complicated by PPRM at 23–33 weeks' gestation, whereas no significant difference was noted in fetal and maternal complication rates and mode of delivery with respect to AFI groups ( $< 5$  cm vs  $\geq 5$  cm).

Increased likelihood of shorter latency to delivery with decreasing AFI values after PPRM in the current study supports the data on association of lower ( $< 5$  cm) AFI values with shorter latency to delivery reported from a prospective analysis of 225 singleton pregnancies complicated by PPRM between 24 and 32 weeks' gestation [12] as well as in a retrospective analysis of 389 women with PPRM between 24 and 34 weeks of gestation [14]. However, in both studies, authors also reported association of oligohydramnios after PPRM with higher rate of cesarean delivery [12, 14] and perinatal adverse outcomes such as early-onset neonatal sepsis [12] and chorioamnionitis [12, 14]. In this regard, the wide range of latency period length (1–26 days) in the current study should also be noted given that this alone may also refer to a considerable risk factor of adverse outcome.

Table 1. Maternal and fetal characteristics with respect to AFI					
Maternal characteristics		Total (n = 48)	AFI < 5 cm (n = 27)	AFI ≥ 5 cm (n = 21)	P
Maternal age, Mean ± SD		27.15 ± 5.04	27.15 ± 5.19	27.14 ± 4.97	0.997 <sup>t</sup>
Gravidity, Median (Min/Max)		2 (1/5)	2 (1/5)	2 (1/4)	0.402 <sup>u</sup>
Parity, n (%)					
	Primipar	22 (45.8)	12 (44.4)	10 (47.6)	0.999 <sup>p</sup>
	Multipar	26 (54.2)	15 (55.6)	11 (52.4)	
BMI [kg/m <sup>2</sup> ], n (%)					
	< 18.5	9 (18.8)	4 (14.8)	5 (23.8)	0.664 <sup>ff</sup>
	18.5–24.9	18 (37.5)	9 (33.3)	9 (42.9)	
	25–29.9	12 (25.0)	8 (29.6)	4 (19.0)	
	> 30	9 (18.8)	6 (22.2)	3 (14.3)	
Smoking, n (%)					
	No	44 (91.7)	24 (88.9)	20 (95.2)	0.621 <sup>f</sup>
	Yes	4 (8.3)	3 (11.1)	1 (4.8)	
PPROM time [week], Mean ± SD		29.11 ± 2.22	28.80 ± 2.21	29.51 ± 2.22	0.291 <sup>t</sup>
Amniotic fluid, n (%)					
	Clear	44 (91.7)	24 (88.9)	20 (95.2)	0.999 <sup>ff</sup>
	Bloody	1 (2.1)	1 (3.7)	0 (0.0)	
	Meconium	3 (6.3)	2 (7.4)	1 (4.8)	
Delivery type, n (%)					
	C/S	9 (18.8)	5 (18.5)	4 (19.0)	0.999 <sup>f</sup>
	Vaginal	39 (81.3)	22 (81.5)	17 (81.0)	
AFI, Mean ± SD.		4.41 ± 1.80	3.05 ± 0.97	6.15 ± 0.83	<b>0.001<sup>t</sup></b>
Latency period [day], Median (Min/Max)		8 (1/26)	7 (1/19)	9 (1/26)	0.322 <sup>u</sup>
Length of hospital stay [day], Median (Min/Max)		2.5 (1/7)	3 (1/7)	2 (1/7)	0.071 <sup>u</sup>
Steroid, n (%)					
	No	1 (2.1)	1 (3.7)	0 (0.0)	–
	Yes	47 (97.9)	26 (96.3)	21 (100.0)	
Magnesium, n (%)					
	No	8 (16.7)	4 (14.8)	4 (19.0)	0.715 <sup>f</sup>
	Yes	40 (83.3)	23 (85.2)	17 (81.0)	
Fetal characteristics					
Gestational age at delivery (week), Mean ± SD.		30.31 ± 1.97	29.86 ± 2.02	30.88 ± 1.80	0.078 <sup>t</sup>
< 34 weeks		44 (91.7)	25 (92.6)	19 (90.5)	0.999 <sup>f</sup>
34 weeks		4 (8.3)	2 (7.4)	2 (9.5)	
Birth weight [g], Mean ± SD.		1520.42 ± 320.62	1440.74 ± 336.33	1622.86 ± 273.75	<b>0.042<sup>t</sup></b>
Gender, n(%)					
	Girl	26 (54.2)	15 (55.6)	11 (52.4)	0.999 <sup>p</sup>
	Boy	22 (45.8)	12 (44.4)	10 (47.6)	

<sup>t</sup> — Independent Samples, <sup>t</sup> — Test(Bootstrap), <sup>u</sup> — Mann Whitney U test(Monte Carlo), <sup>p</sup> — Pearson Chi-Square Test(Exact), <sup>f</sup> — Fisher Exact test(Exact), <sup>ff</sup> — Fisher Freeman Halton Test(Monte Carlo), <sup>rc</sup> — Roc Curve Analysis (Youden index J-Honley&Mc Nell), AUC — Area under the ROC curve, SD. — Standard deviation, Med — Median, Min — Minimum, Max — Maximum

In a retrospective study of 191 pregnancies with PPROM, authors reported higher rates of cesarean sections, 5-min Apgar score < 7, chorioamnionitis, respiratory distress syndrome, composite neonatal morbidity and neonatal

mortality in the group with an AFI < 5 cm vs those with an AFI > 5 cm [19]. Moreover, in a retrospective cohort study of 86 pregnant women with PPROM at 24 to 35 weeks' gestation, authors reported higher rate of perinatal mortality in

**Table 2. Maternal complications with respect to AFI**

		Total (n = 48)	AFI < 5 cm (n = 27)	AFI ≥ 5 cm (n = 21)	P
		Med (Min/Max)	Med (Min/Max)	Med (Min/Max)	
Number of complications		0 (0/3)	0 (0/3)	0 (0/3)	0.349 <sup>u</sup>
		n (%)	n (%)	n (%)	
Complications					
	Absent	28 (58.3)	14 (51.9)	14 (66.7)	0.382 <sup>P</sup>
	Present	20 (41.7)	13 (48.1)	7 (33.3)	
Placental abruption					
	Absent	47 (97.9)	26 (96.3)	21 (100.0)	–
	Present	1 (2.1)	1 (3.7)	0 (0.0)	
Retention					
	Absent	46 (95.8)	26 (96.3)	20 (95.2)	–
	Present	2 (4.2)	1 (3.7)	1 (4.8)	
Endometritis					
	Absent	36 (75.0)	19 (70.4)	17 (81.0)	0.510 <sup>P</sup>
	Present	12 (25.0)	8 (29.6)	4 (19.0)	
Bleeding					
	Absent	45 (93.8)	25 (92.6)	20 (95.2)	0.999 <sup>f</sup>
	Present	3 (6.3)	2 (7.4)	1 (4.8)	
Chorioamnionitis					
	Absent	32 (66.7)	17 (63.0)	15 (71.4)	0.758 <sup>P</sup>
	Present	16 (33.3)	10 (37.0)	6 (28.6)	
CRP					
	normal	36 (75.0)	19 (70.4)	17 (81.0)	0.510 <sup>P</sup>
	elevated	12 (25.0)	8 (29.6)	4 (19.0)	
WBC					
	< 21	38 (79.2)	21 (77.8)	17 (81.0)	0.999 <sup>f</sup>
	> 21	10 (20.8)	6 (22.2)	4 (19.0)	
Body temperature [°C]					
	< 38	32 (66.7)	17 (63.0)	15 (71.4)	0.758 <sup>P</sup>
	> 38	16 (33.3)	10 (37.0)	6 (28.6)	

<sup>u</sup> — Mann Whitney U test (Monte Carlo), <sup>P</sup> — Pearson Chi-Square Test (Exact), <sup>f</sup> — Fisher Exact test (Exact), Med — Median, Min — Minimum, Max — Maximum

AFI < 5 cm vs AFI > 5 cm groups, whereas a higher frequency of 1-min Apgar scores < 7, neonatal sepsis and early neonatal mortality in AFI < 3 cm vs AFI > 3 cm groups [8].

Association of AFI scores < 5 cm with increased risk of chorioamnionitis and early onset neonatal sepsis [20, 21] as well as an association of AFI scores with APGAR scores, neonatal respiratory distress syndrome and maternal chorioamnionitis [15] were also reported in other studies.

Besides, although oligohydramnios has been suggested as an important parameter in the evaluation of fetal wellbeing and a warning sign for predicting poor fetal prognosis in pregnancies complicated by PPRM [8, 12, 14, 15, 18, 19], there is no consensus on the optimal time to induce labor to enable a reduction of perinatal risks [7, 8].

Indeed, comparable to findings in our cohort, lack of association between AFI scores and adverse outcomes in pregnancies complicated by PPRM was also reported in other studies [5, 15]. In a past study of 161 singleton pregnancies complicated by PPRM, authors reported that AFI < 5 cm and AFI ≥ 5 cm were similar in terms of gestational age at rupture of the membranes, gestational age at the delivery, mode of delivery, maternal chorioamnionitis, abruption, early onset neonatal sepsis and NICU stay as well as fetal birth weight [5]. No significant association of AFI with APGAR scores, neonatal RDS and maternal chorioamnionitis was also reported in another study [15].

Notably, in a retrospective cohort study in 92 women with PPRM, authors reported association of persistent

Table 3. Fetal complications with respect to AFI					
		Total (n = 48)	AFI < 5 cm (n = 27)	AFI ≥ 5 cm (n = 21)	P
Number of complications, Median (Min/Max)		2 (0/5)	2 (0/5)	2 (0/5)	0.563 <sup>u</sup>
		n (%)	n (%)	n (%)	
Complications					
	Absent	13 (27.1)	6 (22.2)	7 (33.3)	0.516 <sup>P</sup>
	Present	35 (72.9)	21 (77.8)	14 (66.7)	
ICU stay					
	Absent	16 (33.3)	8 (29.6)	8 (38.1)	0.758 <sup>P</sup>
	Present	32 (66.7)	19 (70.4)	13 (61.9)	
Sepsis					
	Absent	40 (83.3)	22 (81.5)	18 (85.7)	0.999 <sup>f</sup>
	Present	8 (16.7)	5 (18.5)	3 (14.3)	
Meconium aspiration					
	Absent	46 (95.8)	26 (96.3)	20 (95.2)	–
	Present	2 (4.2)	1 (3.7)	1 (4.8)	
Respiratory distress syndrome					
	Absent	23 (47.9)	12 (44.4)	11 (52.4)	0.771 <sup>P</sup>
	Present	25 (52.1)	15 (55.6)	10 (47.6)	
Intraventricular hemorrhage (Grade 3–4)					
	Absent	47 (97.9)	26 (96.3)	21 (100.0)	–
	Present	1 (2.1)	1 (3.7)	0 (0.0)	
Umbilical artery pH					
	< 7.1	43 (89.6)	24 (88.9)	19 (90.5)	0.999 <sup>f</sup>
	> 7.1	5 (10.4)	3 (11.1)	2 (9.5)	
5th min Apgar score					
	< 5	25 (52.1)	14 (51.9)	11 (52.4)	0.999 <sup>P</sup>
	> 5	23 (47.9)	13 (48.1)	10 (47.6)	

<sup>u</sup> — Mann Whitney U test (Monte Carlo), <sup>P</sup> — Pearson Chi-Square Test (Exact), <sup>f</sup> — Fisher Exact test (Exact), Med — Median, Min — Minimum, Max — Maximum

Table 4. Correlation of AFI with other study parameters		
	AFI	
	r	P
Age	0.043	0.771
Gravidity	-0.118	0.425
BMI	-0.162	0.270
PPROM time	-0.120	0.417
Delivery week	0.044	0.765
Birth weight	0.146	0.321
Latency period (day)	0.339	<b>0.018</b>
Post-partum length of hospital stay (day)	-0.314	<b>0.030</b>
Total number of maternal complications	-0.192	0.191
Total number of fetal complications	-0.0002	0.999

Spearman's rho test, r — Correlation Coefficient

oligohydramnios with lower postnatal survival rate and more frequent developmental delay among neonates as

compared with normal amniotic fluid volume, whereas they also indicated that most neonates born alive after PROM and persistent oligohydramnios to survive to discharge and to be developmentally normal [22]. Similarly, while prolonged oligohydramnios following PPRM has traditionally been associated with poor fetal outcomes including high neonatal mortality, an apparent improvement in outcome has also been emphasized recently even amongst the highest risk infants with documented persistent oligohydramnios [16].

Hence, the controversy regarding the association of oligohydramnios with adverse maternal and neonatal outcome in PPRM in published studies seems to emphasize the need for this association to be investigated by further larger scale studies with sufficient number of patients with low AFI [5, 12, 20, 23].

Although, higher fetal birth weight in the AFI ≥ 5 cm group as compared with AFI < 5 cm group in our cohort seems consistent with previously reported role of AFI in predicting macrosomia in a prospective observational study

in 600 patients in the first stage of labor before rupture of membranes [24], it should be noted that latency period and the mean gestational age at the delivery also differed between AFI groups emphasizing the birthweight to be variable dependent on gestational age and placental factors rather than on residual AFI.

In fact, while oligohydramnios has been associated with a higher likelihood of caesarean section due to non-reassuring fetal heart rate patterns [5, 12, 20] as well as with longer NICU stay [25], our findings revealed similar cesarean section delivery rates and length of NICU stay in AFI  $\geq$  5 cm and  $<$  5 cm groups. Nevertheless, caesarean section rate (18.8%) in our cohort of women with pregnancies complicated by PPROM at 23–33 weeks' gestation seems in accordance with the likelihood of an increased risk of maternal infection in cesarean sections, particularly in women at risk of developing chorioamnionitis [23, 26].

## CONCLUSIONS

In conclusion, our findings seem to indicate increased likelihood of shorter latency to delivery and longer postpartum LOS with decrease in AFI after PPROM between 23–33 weeks' gestation, whereas no impact of AFI on mode of delivery and fetal or maternal complications. Further larger scale longitudinal studies in pregnant women with PPROM are needed to investigate the utility of AFI as a potential prognostic variable in predicting adverse fetal or maternal outcomes.

### Conflict of interest

The authors declare that they have no conflict of interest.

### Ethical approval

Written informed consent was obtained from each subject following a detailed explanation of the objectives and protocol of the study which was conducted in accordance with the ethical principles stated in the "Declaration of Helsinki" and approved by the institutional ethics committee.

### Informed consent

Written informed consent was obtained from each subject following a detailed explanation of the objectives and protocol of the study.

## REFERENCES

- American College of Obstetricians and Gynecologists (2013) Premature rupture of membranes. Practice Bulletin No. 139. *Obstet Gynecol* 122:918–930. <https://doi.org/10.1097/01.AOG.0000435415.21944.8f>
- Mercer BM (2003) Preterm premature rupture of the membranes. *Obstet Gynecol* 101:178–193. [https://doi.org/10.1016/s0029-7844\(02\)02366-9](https://doi.org/10.1016/s0029-7844(02)02366-9)
- Dartibale CB, Uchimura NS, Nery L, Schumeish AP, Uchimura LYT, Santana RG, Uchimura TT (2017) Qualitative Determination of Human Chorionic Gonadotropin in Vaginal Washings for the Early Diagnosis of Premature Rupture of Fetal Membranes. *Rev Bras Ginecol Obstet* 39:317–321. <https://doi.org/10.1055/s-0037-1603939>
- Tigga M, Malik S (2014) Various biomarkers in diagnosing premature rupture of membranes: a cost effective analysis. *Internet J Gynecol Obstet* 19:1–6. <https://doi.org/10.5580/IJGO.20709>
- Saraswathy A, Vaman JV, Brahmanandan M, Nirmala C (2018) Correlation between obstetric outcome and amniotic fluid index (AFI) in preterm prelabour rupture of membranes (PPROM). *Int J Reprod Contracept Obstet Gynecol* 7:4858–4861. <http://dx.doi.org/10.18203/2320-1770.ijrcog20184929>
- Caughey AB, Robinson JN, Norwitz ER (2008) Contemporary diagnosis and management of preterm premature rupture of membranes. *Rev Obstet Gynecol* 1:11–22.
- Nabhan AF, Abdelmoula YA (2008) Amniotic fluid index versus single deepest vertical pocket as a screening test for preventing adverse pregnancy outcome. *Cochrane Database Syst Rev* (3):CD006593. <https://doi.org/10.1002/14651858.CD006593.pub2>
- Souza AS, Patriota AF, Guerra GV, Melo BC (2016) Evaluation of perinatal outcomes in pregnant women with preterm premature rupture of membranes. *Rev Assoc Med Bras* (1992) 62:269–275. <https://doi.org/10.1590/1806-9282.62.03.269>
- Tavassoli F, Ghasemi M, Mohamadzade A, Sharifian J (2010) Survey of pregnancy outcome in preterm premature rupture of membranes with amniotic fluid index  $<$ 5 and  $\geq$ 5. *Oman Med J* 25:118–123. <https://doi.org/10.5001/omj.2010.32>
- Melamed N, Ben-Haroush A, Pardo J, Chen R, Hadar E, Hod M, Yogev Y (2011) Expectant management of preterm premature rupture of membranes: is it all about gestational age? *Am J Obstet Gynecol* 204:48.e1–8. <https://doi.org/10.1016/j.ajog.2010.08.021>
- Vintzileos AM, Campbell WA, Nochimson DJ, Weinbaum PJ (1985) Degree of oligohydramnios and pregnancy outcome in patients with premature rupture of the membranes. *Obstet Gynecol* 66:162–167.
- Vermillion ST, Kooba AM, Soper DE (2000) Amniotic fluid index values after preterm premature rupture of the membranes and subsequent perinatal infection. *Am J Obstet Gynecol* 183:271–276. <https://doi.org/10.1067/mob.2000.107653>
- Frenette P, Dodds L, Armson BA, Jangaard K (2013) Preterm prelabour rupture of membranes: effect of latency on neonatal and maternal outcomes. *J Obstet Gynaecol Can* 35:710–717. [https://doi.org/10.1016/S1701-2163\(15\)30861-6](https://doi.org/10.1016/S1701-2163(15)30861-6)
- Ekin A, Gezer C, Taner CE, Ozeren M (2015) Perinatal outcomes in pregnancies with oligohydramnios after preterm premature rupture of membranes. *J Matern Fetal Neonatal Med* 28:1918–1922. <https://doi.org/10.3109/14767058.2014.972927>
- Piazzesi J, Anceschi MM, Cerekja A, Brunelli R, Meloni P, Marzano S, Cosmi E (2007) Validity of amniotic fluid index in preterm rupture of membranes. *J Perinat Med* 35:394–398. <https://doi.org/10.1515/JPM.2007.077>
- Williams O, Hutchings G, Debieve F, Debauche C (2009) Contemporary neonatal outcome following rupture of membranes prior to 25 weeks with prolonged oligohydramnios. *Early Hum Dev* 85:273–277. <https://doi.org/10.1016/j.earlhumdev.2008.11.003>
- Magann EF, Sanderson M, Martin JN, Chauhan S (2000) The amniotic fluid index, single deepest pocket, and two-diameter pocket in normal human pregnancy. *Am J Obstet Gynecol* 182:1581–1588. <https://doi.org/10.1067/mob.2000.107325>
- Kim CJ, Romero R, Chaemsaithong P, Chaiyasit N, Yoon BH, Kim YM (2015) Acute chorioamnionitis and funisitis: definition, pathologic features, and clinical significance. *Am J Obstet Gynecol* 213:S29–52. <https://doi.org/10.1016/j.ajog.2015.08.040>
- Kurdoglu M, Kulusari A, Adali E, Yildizhan R, Kurdoglu Z, Kucukaydin Z, Kaya A, Kirimi E, Sahin HG, Kamaci M (2010) Does residual amniotic fluid after preterm premature rupture of membranes have an effect on perinatal outcomes? 12 years' experience of a tertiary care center. *Arch Gynecol Obstet* 281:601–607. <https://doi.org/10.1007/s00404-009-1147-4>
- Borna S, Borna H, Khazardoost S, Hantoushzadeh S (2004) Perinatal outcome in preterm premature rupture of membranes with Amniotic fluid index  $<$  5 (AFI  $<$  5). *BMC Pregnancy Childbirth* 4:15. <https://doi.org/10.1186/1471-2393-4-15>
- Mousavi AS, Hashemi N, Kashanian M, Sheikhsani N, Bordbar A, Parashi S (2018) Comparison between maternal and neonatal outcome of PPROM in the cases of amniotic fluid index (AFI) of more and less than 5 cm. *J Obstet Gynaecol* 38:611–615. <https://doi.org/10.1080/01443615.2017.1394280>
- Lee JY1, Ahn TG, Jun JK (2015) Short-Term and Long-Term Postnatal Outcomes of Expectant Management After Prevalable Preterm Premature Rupture of Membranes With and Without Persistent Oligohydramnios. *Obstet Gynecol* 126:947–953. <https://doi.org/10.1097/AOG.0000000000001099>

23. Huang S, Qi HB, Li L (2009) Residue amniotic fluid volume after preterm premature rupture of membranes and maternal–fetal outcome. *Zhonghua Fu Chan Ke Za Zhi* 44:726–730.
24. El Khouly NI, Elkelani OA, Saleh SA (2017) Amniotic fluid index and estimated fetal weight for prediction of fetal macrosomia: a prospective observational study. *J Matern Fetal Neonatal Med* 30:1948–1952. <https://doi.org/10.1080/14767058.2016.1233398>
25. Ladella S, Leung T, Cortez C (2017) Effects of Amniotic Fluid Index on Perinatal Outcomes in Preterm Premature Rupture of Membranes [370]. *Obstet Gynecol* 129:S162. <https://doi.org/10.1097/01.AOG.0000514786.52391.ba>
26. Fernandes GL, Torloni MR, Hisaba WJ, Klimke D, Novaes J, Sancovski M, Peixoto S (2012) Premature rupture of membranes before 28 weeks managed expectantly: maternal and perinatal outcomes in a developing country. *J Obstet Gynaecol* 32 :45–49. <https://doi.org/10.3109/01443615.2011.609923>



# Ophthalmological problems in pregnancy — a review

Anna Rzeszotarska<sup>id</sup>, Justyna Szczapa-Jagustyn<sup>id</sup>, Jaroslaw Kociecki<sup>id</sup>

*Ophthalmology Institute and Clinic of Karol Marcinkowski University of Medical Sciences in Poznan, Poland*

## ABSTRACT

Pregnancy is associated with numerous changes affecting all organs. Ophthalmological changes in pregnant women are most often physiological and resolve spontaneously after delivery. However, the possibility of progression of previously diagnosed ophthalmic diseases or the occurrence of ophthalmological complications in the course of diseases characteristic for pregnancy should always be considered.

**Key words:** pregnancy; eye; glaucoma; diabetic retinopathy; myopia; preeclampsia; eclampsia; Sheehan's syndrome; papilloedema; central serous retinopathy

Ginekologia Polska 2020; 91, 8: 473–477

## INTRODUCTION

Ophthalmological changes during pregnancy are usually physiological, temporary and do not require any treatment. However, in some women with previously diagnosed glaucoma or diabetic retinopathy there is a great risk of illness progression. Also, some medical conditions typical for pregnancy, such as preeclampsia, eclampsia and Sheehan's syndrome, may manifest with ophthalmological symptoms.

The main aim of this review is to present possible pathological changes ophthalmological diseases progression that may occur throughout pregnancy. Moreover, we would like to discuss possible treatment methods of some disorders and the ophthalmological indications for caesarean section.

### Glaucoma and pregnancy

Glaucoma is neuropathy of the optic nerve characterized by typical changes in the visual field and optic nerve head that usually occur in people over 40 years of age but may present in younger patients. Glaucoma treatment is based on pharmacotherapy or surgical techniques, including laser treatment. The only modifiable risk factor in glaucoma patients is the intraocular pressure (IOP). Persisting high values of IOP lead to glaucoma progression. In many cases pharmacotherapy is adequate to maintain the target IOP. During pregnancy the IOP decreases but many women with diagnosed glaucoma still require further treatment.

### Glaucoma pharmacotherapy

Prostaglandins, beta blockers, alpha-2 agonists, carbonic anhydrase inhibitors, miotics and osmotic agents are used in glaucoma pharmacotherapy. Most of them are applied topically to the conjunctival sac. To obtain maximum local treatment and minimize the general adverse effects, proper application is essential. Inserting only one drop of antiglaucoma drug, closing the eye for 3–5 minutes and compressing the lacrimal puncta all help to reduce systemic absorption.

Brimonidine is one of the alpha-2 agonists classified as category B by the Food and Drug Administration (FDA). This drug may be used during pregnancy but therapy with brimonidine should be ceased before labour because it penetrates through the blood–brain barrier, which can cause apnoea in the newborn [1].

Among the beta blockers used in glaucoma pharmacotherapy there are several that are non-selective, such as timolol, carteolol, levobunolol, metipranolol and beta-1-selective betaxolol, all of which are classified as category C by the FDA. There are limited reports about the impact of locally administered beta blockers on the foetus, however extreme caution must be exercised, especially in the first trimester, due to their teratogenic effect. Moreover, if given systemically during the second or third trimester, beta blockers may lead to intrauterine growth restriction (IUGR), as well as dysfunction of the newborn's cardiovascular and nervous system. It is assumed that even small doses of timolol used by pregnant women lead to permanent changes in the heart's electrical conduction system [2]. Furthermore,

#### Corresponding author:

Anna Rzeszotarska

Ophthalmology Institute and Clinic of Karol Marcinkowski University of Medical Sciences in Poznan, ½ Długa St, 61–848 Poznan, Poland  
 e-mail: lek.arzeszotarska@gmail.com

breathing disorders were observed in newborns whose mothers used timolol during pregnancy [3].

Prostaglandin analogues (travoprost, latanoprost, bimatoprost, tafluprost) are very effective hypotensive drugs commonly used in glaucoma therapy, although their usage is not recommended in pregnant women. An increased number of miscarriages were observed, compared to a control group, when the prostaglandins were used topically in animal research [4]. Prostaglandin analogues may increase uterine tonus and stimulate uterine contractions, leading to miscarriage or premature labour.

Carbonic anhydrase inhibitors can be used both topically and systemically (orally or intravenously). Brinzolamide and acetazolamide are classified as category C by the FDA. Animal testing with brinzolamide revealed the presence of additional cranial bones in rabbit foetuses, however the dose was higher than that used in antiglaucoma eye drops [5]. Acetazolamide can be used topically, orally or intravenously. During animal testing with acetazolamide, front extremity defects in rat foetuses were observed after high doses [6]. Warsham et al. [7] published the case report of a newborn with sacrococcygeal teratoma whose mother used acetazolamide throughout her pregnancy. There is also a risk of metabolic disorders in newborns if the mother used acetazolamide whilst pregnant [8].

Pilocarpine is quite rarely used in glaucoma treatment, mainly for acute angle closure. Like other parasympathomimetic drugs, it is classified as category C by the FDA. In animal testing, pilocarpine's teratogenic action has been proved [9].

In order to achieve fast reduction of the IOP, osmotic drugs such as mannitol or 85% glycerol solution are commonly used. Both drugs are category C and should be used during pregnancy only if the benefits outweigh the risks.

#### *Surgical treatment in glaucoma patients*

Surgical treatment for glaucoma includes both laser and surgical methods.

Laser treatments such as selective laser trabeculoplasty (SLT) or YAG-laser iridotomy are possible throughout pregnancy. SLT allows the number of antiglaucoma drugs to be reduced or, in some cases, eliminated completely. Iridotomy is a well-known procedure performed in patients with a narrow or closed iridocorneal angle. Laser treatment seems to be a safe method for managing glaucoma but both SLT and iridotomy require perioperative medication with topical drugs, some of which are category C.

If progression in visual field changes is observed despite maximal pharmacological treatment with topical drugs, or if drops are not well tolerated and cause local or systemic side effects, then surgery should be considered. Many of the filtration surgeries, such as trabeculectomy, phacotra-

beculectomy and deep sclerectomy, require the use of antimetabolites (mitomycin C or 5-fluorouracil) during the procedure to achieve a better effect and reduce the risk of scarring. Unfortunately, antimetabolites have a teratogenic and mutagenic effect on the foetus [10, 11]. It seems that the best option is to conduct an operation before any planned conception. Other surgical techniques used in advanced glaucoma, such as cyclodestruction procedures (cyclocry-oapplication or the much more popular cyclophotocoagulation), should be preceded by periocular anaesthesia with lidocaine or bupivacaine, which may be associated with serious side effects in both the mother and child.

#### *Labour and glaucoma*

One of the surveys conducted on a group of healthy pregnant women revealed a statistically significant increase in IOP during labour [12]. Vaginal delivery in women with a narrow iridocorneal angle is associated with a high risk of acute angle closure [13]. Furthermore, decreased intraocular blood flow caused by postpartum haemorrhage is extremely dangerous. Caesarean section should be considered in patients with advanced glaucoma in order to prevent further ocular complications.

What are the indications for caesarean section in patients with glaucoma? According to the *Ophthalmologic and Obstetrical Consensus on Indications for Delivery by Caesarean Section due to Changes in the Sight Organ*, February 2017 [14], the decision is made by an experienced obstetrician based on the opinion of an ophthalmologist after ophthalmological examination. Patients with advanced changes in the visual field caused by glaucoma have a high risk of ophthalmological complications if they give birth vaginally. Each case should be considered individually after appropriate examination and careful analysis of previous medical records to determine the potential degree of disease progression.

#### **Diabetic retinopathy in pregnant women**

Gestational diabetes mellitus (GDM) is defined as the onset or first diagnosis during pregnancy of glucose intolerance. If diagnosed before conception, the diabetes is defined as pregestational diabetes mellitus (PGDM).

GDM does not require monitoring throughout pregnancy. In a survey of 107 pregnant women diagnosed with GDM, none of the patients developed diabetic retinopathy (DR) during pregnancy [15].

However, with PGDM (regardless of type), pregnancy is a significant risk factor for DR progression due to many factors: poor glycaemic control, duration of diabetes, fast normoglycaemia achievement during the first weeks of pregnancy, elevated serum levels of growth factors, co-existing hypertension or preeclampsia and haemodynamic changes

in blood vessels. Improper glycaemic control by a woman of conceptual age may lead to DR development before pregnancy [16]. Obtaining normoglycaemia decreases the risk of miscarriage or congenital defects but, paradoxically, is associated with DR progression. The duration of diabetes seems to be less relevant compared with the previously discussed risk factors. It has been proved that increased growth factor serum levels such as IGF-1 cause progression of DR despite good glycaemic control [17]. Hypertension is critical in DR progression, especially in pregnancy. In one cohort study of a group of 154 pregnant women diagnosed with both pregestational DR and hypertension, progression of retinal changes was observed in 55%. On the other hand, in women diagnosed with PGDM but with no hypertension, progression of DR occurred in only 25% [18]. Furthermore, haemodynamic changes characteristic for pregnancy, such as increased cardiac output, increased plasma volume and reduced peripheral vascular resistance, affect the retinal blood flow. In healthy pregnant women there are mechanisms that maintain a constant blood flow [19] but a hyperdynamic blood circulation in pregnant women with PGDM can cause further endothelial damage [20].

In 2015 the National Institute of Clinical Excellence (NICE) published new guidelines for women with PGDM [21]. According to the NICE guidelines all women with previously diagnosed diabetes should be informed about potential DR progression in the preconception period. Also, women with diabetes who are planning a pregnancy should accomplish good glycaemic control before conception. Moreover, patients should be informed about the risk of DR progression caused by rapidly achieving normoglycaemia. The authors of the NICE 2015 Guidelines advise that the first funduscopy should be conducted after an earlier application of mydriatics (e.g. tropicamide) during the first visit, optimally in the 10<sup>th</sup> week of pregnancy, and then also in the 28<sup>th</sup> week of pregnancy. If during the first ophthalmological examination there are any symptoms indicating DR, then an additional funduscopy should be conducted between the 16<sup>th</sup> and 20<sup>th</sup> week of pregnancy. The presence of features indicating DR are contraindications for rapid glycaemia and glycated haemoglobin (HbA1c) optimization. All women with diagnosed DR or with any retinal changes due to DR during pregnancy should be monitored for six months after labour.

Optimal glycaemic control and proper treatment of previously diagnosed DR before a planned pregnancy should prevent any DR progression that requires treatment. In one retrospective study conducted on 540 pregnant women with diabetes over a 12-year period, only eight patients (1.5%) experienced changes characteristic of proliferative retinopathy requiring retinal laser therapy [22]. Decisions about laser treatment of the retina in such cases should not be delayed because proliferative DR is associated with

a great risk of complications and the need for extensive vitreoretinal surgery.

Diabetic macular oedema (DMO) occurs in a minor number of pregnant women with diabetes and subsides spontaneously after labour [23]. Co-existing nephropathy and hypertension are important risk factors for DMO in GDM. Intravitreal injections of anti-vascular endothelial growth factor (anti-VEGF) — ranibizumab, bevacizumab, aflibercept — are widely used in DMO treatment, although animal tests demonstrate adverse effects on embryo and foetus, therefore they should not be used during pregnancy.

According to the NICE Guidelines 2015, uncomplicated DR is not a direct indication for spontaneous delivery [21]. On the other hand, the authors of the *Ophthalmologic and Obstetrical Consensus on Indications for Delivery by Caesarean Section due to Changes in the Sight Organ* recommend that ending pregnancy by caesarean section should be considered in the following cases: the presence of recurrent vitreous haemorrhage due to DR; the presence of neovascularization at the disk (NVD) or neovascularization elsewhere (NVE), which probably will not disappear (after treatment or spontaneously) before delivery; and the presence of tractional retinal detachment that develops and progresses throughout pregnancy [14].

### Central serous retinopathy

Central serous retinopathy (CSR) is an idiopathic disease characterized by retinal detachment in the macular region secondary to focal defect of the retinal pigment epithelium. CSR is typical for males aged 20–50 years but it can also be observed in females. The risk factors of CSR are stress, steroid therapy, Cushing syndrome, hypertension and gestation. Presented symptoms such as blurry vision, central scotoma, micropsia and metamorphopsia are usually unilateral.

In one prospective study it has been estimated that CSR affects 0.44% of pregnant women [24]. The best diagnostic method to confirm CSR is fluorescein angiography, however optical coherence tomography (OCT) seems to be a safer option.

CSR is usually self-limiting, with all symptoms generally resolving within three months. However, if CSR symptoms do not resolve there are a few therapeutic methods that might be considered, such as laser therapy or pharmacological treatment (using spironolactone, eplerenone, finasteride, carbonic anhydrase inhibitor or acetylsalicylic acid) [25]. When choosing a specific therapy for CSR in pregnant women, the risk of foetal defects must be considered.

### Myopia

Myopia is a common refractive error caused by both genetic and environmental factors and is classified as low (less than –2 dioptre), moderate (–2 to –6 dioptre) or high

(more than  $-6$  dioptr). In a survey, Fernandez-Montero et al. [26] found that pregnancy is a risk factor for myopia development or progression. Another survey conducted by Piazzello [27] found that a myopic shift was observed in pregnant women but that it returned to pre-pregnancy values after labour.

Although high myopia is a risk factor for retinal detachment, it is not a contraindication for spontaneous vaginal delivery. Neri et al. [28] examined 50 women with myopia ranging from  $-4,5$  to  $-15$  dioptr, with each patient undergoing funduscopy before and after labour; none of them had a retinal detachment or tear caused by the delivery.

In some patients with degenerative myopia, choroidal neovascularization may develop and caesarean section should be performed [14]; otherwise, even high myopia should not be considered an indication for caesarean section.

### Papilloedema during pregnancy

Papilloedema is always a diagnostic challenge and is defined as optic disc oedema secondary to increased intracranial pressure. Optic disc swelling may be caused by both life-threatening and non-life-threatening conditions and requires complex diagnostics. There are many causes of papilloedema in pregnant women, some of which are related to the pregnancy. For a differential diagnosis, malignant hypertension, mass lesion and obstructive hydrocephalus should be taken into consideration; however, the most common causes of papilloedema are idiopathic intracranial hypertension (IHT) and central venous thrombosis (CVT) [29].

Evaluating the blood pressure and tests for proteinuria should be conducted to exclude preeclampsia. MRI of the brain without contrast is a safe diagnostic procedure after 18 weeks of pregnancy [31] for detecting mass lesions, hydrocephalus or CVT but there are few data confirming the safety of MRI without contrast in the first trimester. Due to exposure to radiation and a teratogenic effect on the foetus, computed tomography (CT) should only be conducted if MRI is inaccessible. Proper preventive methods should be used to avoid radiation to the foetus. Lumbar puncture (LP) is also a possible diagnostic method in pregnant women if any contraindications are found after evaluating the MRI or CT scans; after obtaining cerebrospinal fluid (CSF) several laboratory tests (glucose, cell, protein count, cytology, VDRL, cryptococcal antigen) should be conducted.

Treatment depends on diagnosis of the primary disorder that leads to papilloedema and must be undertaken to avoid loss of optic nerve function. Diuretics, steroids and anticoagulants are used in the treatment of IHT or CVT. Many of these drugs are classified as category C, which is why there is always a probable risk of side effects on the foetus [29].

### Ocular symptoms of preeclampsia and eclampsia

Blurry vision, photopsia and visual field defects are symptoms that may occur in women with eclampsia or preeclampsia. Funduscopy reveals retinal haemorrhages, Elschnig spots, macular oedema, cotton wool spots and segmented or generalized blood vessel narrowing. In some cases, papilloedema or serous retinal detachment is also observed [31].

The most crucial for therapy is obtaining an optimal blood pressure level. Macular oedema may be treated with laser therapy, steroids or anti-VEGF intravitreal injections after carefully reviewing the benefits and risks. Serous retinal detachment should spontaneously subside after curing the underlying disease.

### Sheehan's syndrome

An ocular manifestation of Sheehan's syndrome can be diplopia (double vision), sudden vision loss or visual field defects and ophthalmoplegia. Medical history that suggests perinatal haemorrhage requires proper diagnostics regarding assessment of thyroid and adrenal gland function, level of growth hormone and MRI scan results [32]. Ocular symptoms of Sheehan's syndrome may recede after using hydrocortisone [33].

### SUMMARY

Ocular disorders in pregnant women are most often physiological and transient. However, severe eye disorders during pregnancy should always be considered and treated in order to avoid serious complications. In patients with diabetes, hypertension, glaucoma, papilloedema or retinal detachment, constant ophthalmological evaluation is necessary throughout pregnancy.

### REFERENCES

1. Cantor LB, Safyan E, Liu CC, et al. Brimonidine in the treatment of glaucoma and ocular hypertension. *Ther Clin Risk Manag.* 2006; 2(4): 337–346, doi: [10.2147/tcrm.2006.2.4.337](https://doi.org/10.2147/tcrm.2006.2.4.337), indexed in Pubmed: [18360646](https://pubmed.ncbi.nlm.nih.gov/18360646/).
2. Wagenvoort AM, van Vugt JM, Sobotka M, et al. Topical timolol therapy in pregnancy: is it safe for the fetus? *Teratology.* 1998; 58(6): 258–262, doi: [10.1002/\(SICI\)1096-9926\(199812\)58:6<258::AID-TERA7>3.0.CO;2-B](https://doi.org/10.1002/(SICI)1096-9926(199812)58:6<258::AID-TERA7>3.0.CO;2-B), indexed in Pubmed: [9894675](https://pubmed.ncbi.nlm.nih.gov/9894675/).
3. Olson R, Bromberg BB, Zimmerman T. Apneic Spells Associated with Timolol Therapy in a Neonate. *American Journal of Ophthalmology.* 1979; 88(1): 120–122, doi: [10.1016/0002-9394\(79\)90766-9](https://doi.org/10.1016/0002-9394(79)90766-9).
4. Sharif NA. Synthetic FP-prostaglandin-induced contraction of rat uterus smooth muscle in vitro. *Prostaglandins Leukot Essent Fatty Acids.* 2008; 78(3): 199–207, doi: [10.1016/j.plefa.2008.01.005](https://doi.org/10.1016/j.plefa.2008.01.005), indexed in Pubmed: [18375109](https://pubmed.ncbi.nlm.nih.gov/18375109/).
5. Alcon Ophthalmics. Azopt Product Monograph. Fort Worth, TX: Alcon Ophthalmics.; 1998.
6. Weaver TE, Scott WJ. Acetazolamide teratogenesis: interaction of maternal metabolic and respiratory acidosis in the induction of ectrodactyly in C57BL/6J mice. *Teratology.* 1984; 30(2): 195–202, doi: [10.1002/tera.1420300207](https://doi.org/10.1002/tera.1420300207), indexed in Pubmed: [6436998](https://pubmed.ncbi.nlm.nih.gov/6436998/).
7. Worsham G. Sacrococcygeal Teratoma in a Neonate. *JAMA.* 1978; 240(3): 251, doi: [10.1001/jama.1978.03290030069029](https://doi.org/10.1001/jama.1978.03290030069029).

8. Capino AC, Dannaway DC, Miller JL. Metabolic Acidosis with Ophthalmic Dorzolamide in a Neonate. *J Pediatr Pharmacol Ther.* 2016; 21(3): 256–259, doi: [10.5863/1551-6776-21.3.256](https://doi.org/10.5863/1551-6776-21.3.256), indexed in Pubmed: [27453705](https://pubmed.ncbi.nlm.nih.gov/27453705/).
9. Landauer W. The teratogenic activity of pilocarpine, pilocarpidine and their isomers, with special reference to the importance of steric configuration. *Journal of Experimental Zoology.* 1956; 132(1): 39–50, doi: [10.1002/jez.1401320104](https://doi.org/10.1002/jez.1401320104).
10. Kuwagata M, Takashima H, Nagao T. A comparison of the in vivo and in vitro response of rat embryos to 5-fluorouracil. *J Vet Med Sci.* 1998; 60(1): 93–99, doi: [10.1292/jvms.60.93](https://doi.org/10.1292/jvms.60.93), indexed in Pubmed: [9492366](https://pubmed.ncbi.nlm.nih.gov/9492366/).
11. Shepard TH, Lemire RJ. *Catalog of Teratogenic Agents*, 2nd edn. Baltimore, MD: Johns Hopkins University Press, 2004, p. ; 278.
12. Avasthi P, Sethi P, Mithal S. Effect of pregnancy and labor on intraocular pressure. *Int Surg.* 1976; 61(2): 82–84, indexed in Pubmed: [1254403](https://pubmed.ncbi.nlm.nih.gov/1254403/).
13. Kearns PP, Dhillon BJ. Angle closure glaucoma precipitated by labour. *Acta Ophthalmol (Copenh).* 1990; 68(2): 225–226, doi: [10.1111/j.1755-3768.1990.tb01910.x](https://doi.org/10.1111/j.1755-3768.1990.tb01910.x), indexed in Pubmed: [2356714](https://pubmed.ncbi.nlm.nih.gov/2356714/).
14. Ophthalmologic and obstetric consensus on indications for caesarean section. Warsaw: Polish Ophthalmological Society. ; 2017.
15. Horvat M, Maclean H, Goldberg L, et al. Diabetic retinopathy in pregnancy: a 12-year prospective survey. *Br J Ophthalmol.* 1980; 64(6): 398–403, doi: [10.1136/bjo.64.6.398](https://doi.org/10.1136/bjo.64.6.398), indexed in Pubmed: [7387964](https://pubmed.ncbi.nlm.nih.gov/7387964/).
16. Chew EY, Mills JL, Metzger BE, et al. Metabolic control and progression of retinopathy. The Diabetes in Early Pregnancy Study. National Institute of Child Health and Human Development Diabetes in Early Pregnancy Study. *Diabetes Care.* 1995; 18(5): 631–637, doi: [10.2337/diacare.18.5.631](https://doi.org/10.2337/diacare.18.5.631), indexed in Pubmed: [8586000](https://pubmed.ncbi.nlm.nih.gov/8586000/).
17. Lauszus FF, Klebe JG, Bek T, et al. Increased serum IGF-I during pregnancy is associated with progression of diabetic retinopathy. *Diabetes.* 2003; 52(3): 852–856, doi: [10.2337/diabetes.52.3.852](https://doi.org/10.2337/diabetes.52.3.852), indexed in Pubmed: [12606530](https://pubmed.ncbi.nlm.nih.gov/12606530/).
18. Rosenn B, Miodovnik M, Kranias G, et al. Progression of diabetic retinopathy in pregnancy: association with hypertension in pregnancy. *Am J Obstet Gynecol.* 1992; 166(4): 1214–1218, doi: [10.1016/s0002-9378\(11\)90608-5](https://doi.org/10.1016/s0002-9378(11)90608-5), indexed in Pubmed: [1566772](https://pubmed.ncbi.nlm.nih.gov/1566772/).
19. Chen HC, Newsom RS, Patel V, et al. Retinal blood flow changes during pregnancy in women with diabetes. *Invest Ophthalmol Vis Sci.* 1994; 35(8): 3199–3208, indexed in Pubmed: [8045714](https://pubmed.ncbi.nlm.nih.gov/8045714/).
20. Tooke JE. Microvascular function in human diabetes. A physiological perspective. *Diabetes.* 1995; 44(7): 721–726, doi: [10.2337/diab.44.7.721](https://doi.org/10.2337/diab.44.7.721), indexed in Pubmed: [7789639](https://pubmed.ncbi.nlm.nih.gov/7789639/).
21. <https://www.nice.org.uk/guidance/ng3/resources/diabetes-in-pregnancy-management-from-preconception-to-the-postnatal-period-51038446021>.
22. Chan WC, Lim LT, Quinn MJ, et al. Management and outcome of sight-threatening diabetic retinopathy in pregnancy. *Eye (Lond).* 2004; 18(8): 826–832, doi: [10.1038/sj.eye.6701340](https://doi.org/10.1038/sj.eye.6701340), indexed in Pubmed: [14976547](https://pubmed.ncbi.nlm.nih.gov/14976547/).
23. Sinclair SH, Nesler C, Foxman B, et al. Macular edema and pregnancy in insulin-dependent diabetes. *Am J Ophthalmol.* 1984; 97(2): 154–167, doi: [10.1016/s0002-9394\(14\)76085-4](https://doi.org/10.1016/s0002-9394(14)76085-4), indexed in Pubmed: [6696026](https://pubmed.ncbi.nlm.nih.gov/6696026/).
24. Said-Ahmed K, Moustafa G, Fawzy M. Incidence and natural course of symptomatic central serous chorioretinopathy in pregnant women in a maternity hospital in Kuwait. *Middle East Afr J Ophthalmol.* 2012; 19(3): 273–276, doi: [10.4103/0974-9233.97920](https://doi.org/10.4103/0974-9233.97920), indexed in Pubmed: [22837618](https://pubmed.ncbi.nlm.nih.gov/22837618/).
25. Abouammoh MA. Advances in the treatment of central serous chorioretinopathy. *Saudi J Ophthalmol.* 2015; 29(4): 278–286, doi: [10.1016/j.sjopt.2015.01.007](https://doi.org/10.1016/j.sjopt.2015.01.007), indexed in Pubmed: [26586979](https://pubmed.ncbi.nlm.nih.gov/26586979/).
26. Fernández-Montero A, Bes-Rastrollo M, Moreno-Montañés J, et al. Effect of pregnancy in myopia progression: the SUN cohort. *Eye (Lond).* 2017; 31(7): 1085–1092, doi: [10.1038/eye.2017.24](https://doi.org/10.1038/eye.2017.24), indexed in Pubmed: [28304386](https://pubmed.ncbi.nlm.nih.gov/28304386/).
27. Pizzarello LD. Refractive changes in pregnancy. *Graefes Arch Clin Exp Ophthalmol.* 2003; 241(6): 484–488, doi: [10.1007/s00417-003-0674-0](https://doi.org/10.1007/s00417-003-0674-0), indexed in Pubmed: [12736728](https://pubmed.ncbi.nlm.nih.gov/12736728/).
28. Neri A, Grausbord R, Kremer I, et al. The management of labor in high myopic patients. *Eur J Obstet Gynecol Reprod Biol.* 1985; 19(5): 277–279, doi: [10.1016/0028-2243\(85\)90041-3](https://doi.org/10.1016/0028-2243(85)90041-3), indexed in Pubmed: [4018367](https://pubmed.ncbi.nlm.nih.gov/4018367/).
29. Schiffman JS, Scherokman B, Tang RA, et al. Evaluation and treatment of papilledema in pregnancy. *Compr Ophthalmol Update.* 2006; 7(4): 187–202, indexed in Pubmed: [17007732](https://pubmed.ncbi.nlm.nih.gov/17007732/).
30. Principles for the protection of patients and volunteers during clinical magnetic resonance diagnostic procedures. *Ann NY Acad Sci.* 1992; 649: 372–375, doi: [10.1111/j.1749-6632.1992.tb49634.x](https://doi.org/10.1111/j.1749-6632.1992.tb49634.x), indexed in Pubmed: [1580515](https://pubmed.ncbi.nlm.nih.gov/1580515/).
31. Abu Samra K. The eye and visual system in the preeclampsia/eclampsia syndrome: What to expect? *Saudi J Ophthalmol.* 2013; 27(1): 51–53, doi: [10.1016/j.sjopt.2012.04.003](https://doi.org/10.1016/j.sjopt.2012.04.003), indexed in Pubmed: [23964188](https://pubmed.ncbi.nlm.nih.gov/23964188/).
32. Krysiak R, Okopień B. [Sheehan's syndrome—a forgotten disease with 100 years' history]. *Przegl Lek.* 2015; 72(6): 313–320, indexed in Pubmed: [26817341](https://pubmed.ncbi.nlm.nih.gov/26817341/).
33. Vaphiades MS, Simmons D, Archer RL, et al. Sheehan syndrome: a splinter of the mind. *Surv Ophthalmol.* 2003; 48(2): 230–233, doi: [10.1016/s0039-6257\(02\)00459-9](https://doi.org/10.1016/s0039-6257(02)00459-9), indexed in Pubmed: [12686307](https://pubmed.ncbi.nlm.nih.gov/12686307/).

## Interstitial ectopic pregnancy following ipsilateral salpingectomy

Dariusz Piecha<sup>1</sup>, Dagmara Pluta<sup>2</sup>, Patrycja Pas<sup>3</sup>, Joanna Plonka<sup>3</sup>, Karolina Kowalczyk<sup>2</sup>

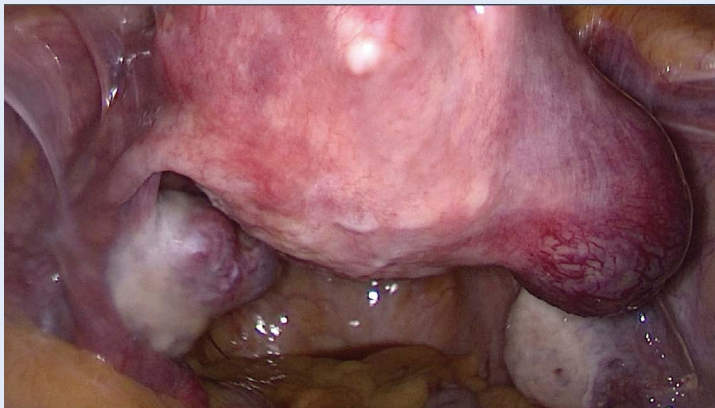<sup>1</sup>Department of Obstetrics and Gynaecology, Medical Center in Piekary Slaskie, Poland

<sup>2</sup>Clinic of Gynecological Endocrinology, Department of Gynecology and Obstetrics, Medical University of Silesia, Katowice, Poland

<sup>3</sup>Gynecological Endocrinology Students Scientific Association, Medical University of Silesia, Katowice, Poland

A 32-year-old woman (gravida 3, para 1) was referred to the Department of Gynecology with suspected ectopic pregnancy six weeks after her last menstrual period. Her medical history revealed one cesarean section with concomitant intramural fibroid resection 18 months earlier. Then, after 10 months, she experienced an ectopic pregnancy in the right fallopian tube. Because of this, a laparoscopy was performed and the whole tube with gestational sac was removed due to isthmus and interstitial part adhesions.

On admission the patient was asymptomatic, having neither abdominal pain nor uterine bleeding. A physical exam revealed benign abdomen, normal uterine size and non-palpable adnexa. Gradual increase in beta human chorionic gonadotropin ( $\beta$ -hCG) was observed — 415 mIU/mL in the fourth week of pregnancy and 5000 mIU/mL in the fifth week. After admission, two-day increase from 9384 mIU/mL to 16345 mIU/mL was observed. However, there was no gestational sac inside the uterine cavity visible on the transvaginal ultrasound. A 30×15 mm heterogeneous mass with hypoechoic central part and a peripheral vascular rim in Power Doppler ultrasound was observed in the right cornual area.



**Figure 1.** Right interstitial ectopic pregnancy with visible myometrial trophoblast invasion

The patient was scheduled for exploratory laparoscopy which showed an interstitial ectopic pregnancy in the right uterine horn with a diameter of 2–3 cm (Fig. 1). Due to massive pelvic adhesions a decision was made to proceed with a conversion to laparotomy. A successful right-sided cornual resection with removal of interstitial ectopic pregnancy tissue was performed. Uterine closure was performed with double-layer suturing. Anti-adhesion prophylaxis was applied. The patient made an uneventful postoperative recovery and was discharged from the hospital 3 days after the surgery.

Interstitial (cornual) pregnancy refers to an ectopic pregnancy that is implanted in the tubal segment

traversing the muscular wall of the uterus. This section of tube is relatively thick, and is located in a highly vascular region. Therefore, interstitial ectopic pregnancy tends to rupture later, with more severe bleeding than other ectopic pregnancies. Its incidence accounts for 2–4% of ectopic pregnancies. Additionally, the mortality rate varies from 2.0 to 2.5%. The high mortality in this type of pregnancy is partially because of delay in diagnosis and the speed of hemorrhage. The etiology of interstitial pregnancy remains unknown. However, similar risk factors for tubal ectopic pregnancy such as pelvic inflammatory disease, tubal disease, adnexal surgery, and assisted reproductive techniques are associated [1]. The risk of reappearance of ectopic pregnancy is approximately 15% and increases to 30% with two previous ectopic pregnancies [2]. Recurrent ipsilateral spontaneous ectopic pregnancy after total salpingectomy is a very rare occurrence.

There are several described mechanisms of recurrent ipsilateral ectopic pregnancy. The first one involves the spermatozoa or embryo passing through the contralateral patent tube into the pouch of Douglas and then migrating to the damaged fallopian tube. A second theory suggests the passage of the fertilized egg through the contralateral intact uterine tube. It is also possible that despite surgical excision of the tube after salpingectomy; the lumina remain intact in the interstitial portion and

Corresponding author:

Karolina Kowalczyk

Clinic of Gynecological Endocrinology, Department of Gynecology and Obstetrics, Medical University of Silesia, Katowice, Poland

e-mail: karolina.kowalczyk74@gmail.com

distal remnant of the fallopian tube, allowing communication between the endometrial and peritoneal cavities. This allows for fertilization and implantation within this portion of the remnant tube [3].

The literature reports a high variety of interstitial pregnancy treatment regimens. Surgical management is indicated in the presence of significant symptoms, cornual rupture or large pregnancies. A trend in the last few years has been to use conservative treatment such as laparoscopic cornual resection or cornuostomy if possible [4]. In our patient, recurrent ectopic pregnancy and massive pelvic adhesions justified the protocol of cornual resection via laparotomy. Methotrexate injection is used as a successful noninvasive option — it is administered either systemically or locally [5].

A cornual gestation is one of the most hazardous types of ectopic gestation. The diagnosis and treatment of such a pregnancy is challenging and constitutes an urgent medical situation. Early clinical diagnosis of ectopic pregnancy based on the combination of a clinical suspicion, serum  $\beta$ -hCG assays, transvaginal ultrasonography findings supported by laparoscopy may help to contribute towards effective conservative treatment options.

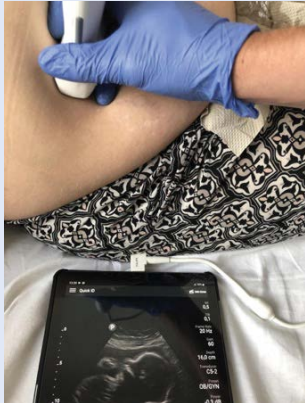## REFERENCES

1. Pramayadi CT, Bramantyo A, Gunardi ER. Successful Procedure in Conservative Management of Interstitial (Cornual) Ectopic Pregnancy. *Gynecol Minim Invasive Ther.* 2018; 7(4): 172–174, doi: [10.4103/GMIT.GMIT\\_9\\_18](https://doi.org/10.4103/GMIT.GMIT_9_18), indexed in Pubmed: [30306037](https://pubmed.ncbi.nlm.nih.gov/30306037/).
2. Diagnosis and Management of Ectopic Pregnancy. RCOG Green Top Guidelines . 2016; 21.
3. Gao MY, Zhu H, Zheng FY. Interstitial Pregnancy after Ipsilateral Salpingectomy: Analysis of 46 Cases and a Literature Review. *J Minim Invasive Gynecol.* 2020; 27(3): 613–617, doi: [10.1016/j.jmig.2019.04.029](https://doi.org/10.1016/j.jmig.2019.04.029), indexed in Pubmed: [31589932](https://pubmed.ncbi.nlm.nih.gov/31589932/).
4. Cucinella G, Calagna G, Rotolo S, et al. Interstitial pregnancy: a 'road map' of surgical treatment based on a systematic review of the literature. *Gynecol Obstet Invest.* 2014; 78(3): 141–149, doi: [10.1159/000364869](https://doi.org/10.1159/000364869), indexed in Pubmed: [25060047](https://pubmed.ncbi.nlm.nih.gov/25060047/).
5. Nikodjjevic K, Bricou A, Benbara A, et al. Cornual pregnancy: Management and subsequent fertility. *Gynecol Obstet Fertil.* 2016; 44(1): 11–16, doi: [10.1016/j.gyobfe.2015.10.011](https://doi.org/10.1016/j.gyobfe.2015.10.011), indexed in Pubmed: [26678164](https://pubmed.ncbi.nlm.nih.gov/26678164/).

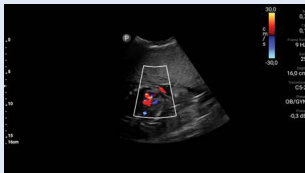## Performance of portable handheld ultrasound system in fetal therapy

Anna Szczepkowska<sup>ID</sup>, Michal Lipa<sup>ID</sup>, Przemyslaw Kosinski<sup>ID</sup>, Mirosław Wielgos<sup>ID</sup>

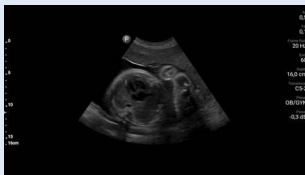*1<sup>st</sup> Department of Obstetrics and Gynecology, Medical University of Warsaw, Poland*



**Figure 1.** Portable ultrasound system in use



**Figure 2.** Cross section of the fetal chest revealing fetal heart rate after intravenous blood transfusion and severe placentomegaly



**Figure 3.** Cross section of fetal thorax after shunt placement

There is no doubt ultrasound remains the most important, safe, non-invasive and acceptable diagnostic method in obstetrics and gynecology. Throughout the years, new technological advances have significantly improved imaging quality, prenatal detection of congenital defects and ultrasonographic assistance in the field of fetal therapy [1]. Easy access allows more direct investigation and fetal wellbeing monitoring, especially in cases of emergency events [1]. Certainly, portable ultrasound systems open new opportunities in the fetal therapy, especially during preparation of the intrauterine procedures, ultrasonographic guidance and fetal monitoring after intrauterine surgeries/ invasive procedures [1]. In this paper, we present several, clinical applications of portable ultrasound system (Fig. 1) in patients who have undergone fetal therapy.

Careful planning is essential in fetal therapy- invasive procedures require proper precision and accuracy. This can be achieved even before the use of a regular high-resolution ultrasound machine to assess placental location and fetal position to plan the incision site. Portable ultrasound devices are even more useful in early follow-up after invasive procedures [1]. Normal fetal heart rate after prenatal intervention displayed on the monitor remains an especially important psychological aspect for patients and good prognostic factor for further pregnancy outcome.

Twin-to-twin transfusion syndrome (TTTS), a severe complication that affects about 10% of monochorionic twin pregnancies, can be effectively treated with endoscopic laser coagulation of the vascular anastomoses present on the fetal side of the placenta [2]. Endoscopic laser coagulation may be also used as a treatment in twin reversed arterial perfusion syndrome (TRAP) to occlude umbilical vessels in the acardiac twin [3]. As the first several days after the laser procedures in twins seem to determine long-term outcomes, serial monitoring of fetal heart rates, deepest vertical pockets (DVP) of amniotic fluids and appearance of fetal bladders remain the most important aspects in postsurgical monitoring. As patients may feel uncomfortable after these procedures, portable ultrasound systems may help to monitor hemodynamic, fetal status on the bedside with no need to refer patient to the ultrasound department.

Rhesus disease or infections with Parvovirus B19 may induce progressing fetal anemia, heart failure or intrauterine death. The gold standard of diagnosis and treatment of these pathologies are intrauterine blood transfusions. The technique, injection site and volume of transfused blood depend on gestational age and hemodynamic status. In cases of severe anemia usually fetal hydrops coexist. Serial blood transfusions may prevent from cardiac failure and adverse pregnancy outcome [4]. In this group of patients, portable ultrasound allows to register fetal heart rate following the procedure. Figure 2 shows fetus with severe hydrops fetalis and severe anemia due to Parvovirus B19 infection few hours after blood transfusion.

In cases of pleural effusion ultrasound-guided placement of thoraco-amniotic shunt can bring benefits such as restoring normal intrathoracic anatomy, reducing the risk of lung hypoplasia.

Portable system can be useful in clinical setting after the procedure to confirm correct shunt's placement (Fig. 3) and fetal heart rate, particularly during ward rounds and when a patient reports complaint. It also allows easy evaluation of pleural effusion and amniotic fluid index.

Hand-held ultrasound devices are easy and convenient for both, physicians and patients [1]. As an ultrasound scan is possible instantly at a patient's bedside it is useful in emergency situations. Considering the abovementioned, clinical applications it seems that portable ultrasound systems may be widely used in the future, not only in fetal surgery, but in other fields as well.

Corresponding author:

Przemyslaw Kosinski

1<sup>st</sup> Department of Obstetrics and Gynecology, Medical University of Warsaw, Poland, 1/3 Sokratesa St, 02–015 Warsaw, Poland

e-mail: pkosinski@wum.edu.pl



#### REFERENCES:

1. Rykkje A, Carlsen JF, Nielsen MB. Hand-Held Ultrasound Devices Compared with High-End Ultrasound Systems: A Systematic Review. *Diagnostics (Basel)*. 2019; 9(2), doi: [10.3390/diagnostics9020061](https://doi.org/10.3390/diagnostics9020061), indexed in Pubmed: [31208078](https://pubmed.ncbi.nlm.nih.gov/31208078/).
2. Bolch C, Fahey M, Reddihough D, et al. Twin-to-twin transfusion syndrome neurodevelopmental follow-up study (neurodevelopmental outcomes for children whose twin-to-twin transfusion syndrome was treated with placental laser photocoagulation). *BMC Pediatr*. 2018; 18(1): 256, doi: [10.1186/s12887-018-1230-8](https://doi.org/10.1186/s12887-018-1230-8), indexed in Pubmed: [30068295](https://pubmed.ncbi.nlm.nih.gov/30068295/).
3. Buyukkaya A, Tekbas G, Buyukkaya R. Twin Reversed Arterial Perfusion (TRAP) Sequence; Characteristic Gray-Scale and Doppler Ultrasonography Findings. *Iranian Journal of Radiology*. 2015; 12(3), doi: [10.5812/iranradiol.12\(3\)2015.14979](https://doi.org/10.5812/iranradiol.12(3)2015.14979).
4. Jong Ede, Haan Tde, Kroes A, et al. Parvovirus B19 infection in pregnancy. *Journal of Clinical Virology*. 2006; 36(1): 1–7, doi: [10.1016/j.jcv.2006.01.004](https://doi.org/10.1016/j.jcv.2006.01.004).

# Recommendations of the Group of Experts of the Polish Society of Gynecologists and Obstetricians regarding abnormal uterine bleeding in adolescents

Agnieszka Drosdzol-Cop<sup>1</sup>, Violetta Skrzypulec-Plinta<sup>2</sup>, Lidia Hinrle<sup>3</sup>, Anna Fuchs<sup>1</sup>,  
Iwona Joanna Czech<sup>4</sup>, Grazyna Jarzabek-Bielecka<sup>5</sup>

<sup>1</sup>Chair and Department of Gynecology, Obstetrics and Oncological Gynecology, Medical University of Silesia in Katowice, Poland

<sup>2</sup>Chair of Woman's Health, Medical University of Silesia in Katowice, Poland

<sup>3</sup>1<sup>st</sup> Department and Clinic of Gynaecology and Obstetrics, Wrocław Medical University, Poland

<sup>4</sup>Department of Woman's Health, School of Health Sciences in Katowice, Medical University of Silesia, Katowice, Poland

<sup>5</sup>Division of Gynecology, Department of Perinatology and Gynecology, Poznan University of Medical Sciences, Poland

## INTRODUCTION

The recommendations present the current knowledge and procedures, which can be modified and changed in some cases, after careful analysis of a given clinical situation, which in the future may become the basis for their modification and updating.

### Menstrual cycle in adolescents

Normal menstrual cycles in adolescents last 21–45 days, with 2–7 days of menstrual bleeding and 20–80 mL of menstrual blood loss. During the first year after menarche, the mean duration of the menstrual cycle is 32.2 days. In the majority of teenagers, in the first 2–3 years after the menarche, menstrual cycles are irregular, which is caused by anovulation and immaturity of the hypothalamic-pituitary-ovarian system [1, 2].

Anovulatory menstrual cycles are present typically during first years of menarche. The rate of ovulation depends on the period of time from the first menstruation and the age of menarche. Earlier menarche age correlates with faster onset of ovulatory cycles. Some girls who had menarche before the age of 12 have ovulation in 50% of their menstrual cycles in the first year, while at the point of later menarche, the ovulatory menstrual cycle stabilizes even after 8–12 years. By the 3<sup>rd</sup> year after menarche, 60–80% of menstrual cycles are normalized (mean duration 21–34 days). It is also believed that the time needed to normalize the menstrual cycle may extend up to 6 years after menarche [1, 2].

### Abnormal uterine bleeding — definition, epidemiology, etiology

In adolescents, heavy menstrual bleeding (HMB) is most often caused by anovulatory irregular menstrual cycles and can occur in two forms:

- as abnormal uterine bleeding (AUB), the most common clinical picture, with irregularity in the timing of bleeding, cycle length and the volume of menstrual blood lost;
- as episodes of amenorrhea for an average of 3 months, followed by 1-day bleeding in the next month (non-cyclic or insufficient exfoliation of the functional layer of the endometrium, which is thickened, resulting in amenorrhea for the next few months, during which there is a slow growth endometrium) — a less common clinical picture [1–3].

Less frequently, heavy menstrual bleeding in adolescents take the form of functional anovulatory uterine bleeding (predominantly at the beginning of adolescence) [1–3].

The most common cause of abnormal bleeding from the genital tract (AUB) in adolescence is juvenile bleeding, defined as profuse bleeding with clots lasting more than 10 days, often leading to anemia, not associated with any organic pathology of the reproductive organ and systemic diseases. The menstrual blood loss usually exceeds 80 mL. Such bleeding episodes that are not related to the menstrual cycle can occur up to 5 years after the menarche; they are characterized by various bleeding times and intervals between episodes, as well as different degrees of bleeding: from moderate to heavy. It is a very common form of menstrual disorders in adolescence, usually of a functional nature.

#### Corresponding author:

Agnieszka Drosdzol-Cop

Chair and Department of Gynecology, Obstetrics and Oncological Gynecology, Medical University of Silesia in Katowice, Poland

e-mail: cor111@poczta.onet.pl

The main cause of juvenile bleeding in girls are anovulatory cycles, physiologically lasting up to 2–3 years after the menarche, caused by immaturity of the hypothalamic-pituitary-ovary system. However, the etiopathogenesis of juvenile bleeding has not been clearly established — most adolescents do not have ovulation in the first years after the menarche, but only some girls experience abnormal heavy vaginal bleeding [1–3].

Juvenile bleeding occurs in about 12–37% of adolescent girls. In 20% of cases, such episodes are observed already during the first menstruation, and in 80% they occur in the period from one to two years after the menarche. Such heavy menstrual bleeding is often described by girls as: the presence of clots in the menstrual blood  $\geq 2.5$  cm in diameter, the need to change the pads/tampons more often than every hour, the pads / tampons become soaked after 1h for the next 2–3 hours, the use of “double protection” (a pad and a tampon or 2 pads in total), menstrual bleeding, “gushing” sensations of blood, frequent incidents of leaking pads, and iron deficiency anemia may occur [1–3].

Abnormal vaginal bleeding in girls in the form of juvenile bleeding does not have organic origin but is caused by anovulation (90%) or luteal failure (10%). Post-menstrual cycles are usually anovulatory, more or less irregular, and with varying degrees of bleeding. During this period, pulse secretion of gonadotrophins also begins during the day and is regulated until the frequency and amplitude of the pulses reach the value characteristic of ovulatory cycles. The mucosa of the uterine cavity proliferates upon exposure to estrogens in the follicular phase (normal FSH pulses), and the lack of progesterone in the luteal phase (no LH pulse in the middle of the cycle) does not adequately stabilize the endometrium which does not undergo secretory transformation. The mucosa peels off and there is profuse, unrelated to the menstrual cycle, sometimes difficult to control bleeding. The endometrium is atrophied as manifested by continual vaginal bleeding. The above fact indicate that the use of only progestins (cyclically, in the luteal phase) in the treatment of adolescent bleeding in girls often does not bring the expected results and may lead to the need for curettage of the uterine cavity [1–5].

Excessive, abnormal, prolonged bleeding during adolescence may also occur in girls in other clinical conditions related to anovulation, such as: eating disorders, weight changes, chronic systemic diseases, intense emotional stress, excessive physical activity related to playing sports, drug abuse, ovarian tumors, endocrine disorders, and polycystic ovary syndrome (PCOS) (20–30% of PCOS patients have pre-existing AUB) [1–5].

### Differential diagnosis

Although the most common type of abnormal bleeding from the genital tract in adolescent girls are juvenile bleed-

ing (non-ovulatory, functional), which accounts for 45–97% of all causes, in each case of prolonged bleeding a careful differential diagnosis should be performed and any possible etiology of the symptoms should be ruled out. The causes of AUB in girls include [1–8]:

- **juvenile bleeding (non-ovulatory, functional) — 45–97%;**
- pregnancy-related disorders (miscarriage, ectopic pregnancy, gestational trophoblastic disease);
- sexually transmitted infections (STI; pelvic inflammatory syndrome, endometritis, cervicitis, vaginitis, Neisseria gonorrhoeae and Chlamydia trachomatis infection);
- coagulation disorders (thrombocytopenia, von Willebrand's disease, congenital disorders of coagulation factors, platelets, leukemia, aplastic anemia, liver failure) — 3–19%;
- endocrine disorders (hypothyroidism and hyperthyroidism, hyperprolactinaemia, PCOS, adrenal gland disease, ovarian failure in Turner syndrome, after chemotherapy/radiotherapy);
- cervical diseases (polyps, inflammation, hemangiomas, neoplastic changes — very rarely);
- vaginal diseases (inflammation, neoplastic changes — very rarely);
- endometrial pathologies (congenital malformations, submucosal fibroids, polyps, bleeding associated with the use of hormonal contraceptives or IUD, neoplastic changes — very rarely);
- pathologies of appendages (cystic, neoplastic changes);
- endometriosis;
- injuries to the reproductive organ (sexual abuse);
- presence of a foreign body in the vagina (most often an unremoved, forgotten tampon);
- systemic diseases (diabetes, kidney diseases, systemic lupus);
- medications used (hormonal contraception, androgens, spironolactone, anticoagulants, antipsychotics).

### The diagnosis of AUB

Important elements in the diagnostic process of juvenile bleeding are: clinical history, physical examination, basic laboratory tests and imaging tests (in selected cases). The clinical history should cover the following issues [1–8]:

#### Gynecological history

- menarche — the older the age of the first menstruation, the longer the period of anovulatory cycles, a heavy first menstruation may suggest congenital disorders of the coagulation system;
- length and regularity of menstrual cycles (based on the menstrual calendar and Menstrual Bleeding Questionnaire — MBQ), presence of dysmenorrhea [6];
- characteristics of menstrual bleeding — (based on the Menstrual Bleeding Questionnaire — MBQ) date of

the last menstruation, length, abundance, presence of blood clots during the day and night, average number of pads/tampons used per day (it is estimated that the consumption of more than 3 soaked sanitary napkins) or 5–6 saturated, normal-size tampons per day for at least 3 days is equivalent to blood loss of more than 80 mL) [6];

- episodes of galactorrhea, discharge from the nipples;
- STI risk factors (early age of sexual initiation, high risk behavior, multiple sexual partners, not using condoms, having intercourse during menstrual bleeding) and their history;
- date of last sexual contact, forms of contraception used;
- sexual abuse (may be related to a genital trauma).

#### Medical history

- presence of systemic diseases (coagulation disorders, diabetes, kidney and liver diseases, gastroenterological disorders);
- prone to bruising, bruising, nosebleeds or gums;
- previous surgical procedures;
- medications used (hormonal contraceptives, anticoagulants, psychiatric drugs);
- the presence of symptoms of hyperandrogenism (acne, hirsutism, acanthosis nigricans);
- exposure to stress (psychological factors);
- changes in body weight (diet, weight loss, increased physical activity).

#### Family history

- a family history of heavy menstrual bleeding (risk of von Willebrand disease);
- the presence of coagulation disorders;
- autoimmune diseases;
- endocrine disorders;
- neoplastic diseases.

#### Physical examination

Next element of the juvenile bleeding diagnostic algorithm is the physical examination, which should start with a careful assessment of the girl's general and emotional condition. Then, a typical physical examination should be performed, paying particular attention to [1–8]:

- height, weight, BMI, body build, nutritional status, fat distribution (excluding Cushing's syndrome, Turner syndrome);
- measurement of blood pressure (lying down and standing) and heart rate (excluding cardiovascular disorders as a consequence of severe anemia);
- presence of headaches, visual disturbances;
- the presence of symptoms of hyperandrogenism;
- presence of symptoms typical for coagulation disorders (bruises, ecchymosis);
- assessment of the thyroid gland (nodules, enlargement);
- assessment of the breast glands (galactorrhea);

- evaluation of sexual maturation — Tanner scale (pubarche, thelarche, adrenarche).

#### Gynecological examination

Gynecological examination in sexually inactive girls rarely requires examination with a speculum. It is enough to perform an internal examination with one finger to assess the palpation of the vaginal part of the cervix and exclude the presence of a foreign body in the vagina. It is also possible to supplement such a procedure with a transrectal examination, carefully examining the appendages area (exclusion of nodular changes). In selected clinical cases (massive vaginal bleeding, suspected foreign body or vaginal damage), even in sexually inactive girls, a complete gynecological examination under general anesthesia should be performed [1–8].

In sexually active girls, a full gynecological examination is recommended. Assess the external genitalia (the size of the clitoris), and in the speculum: the cervix and vaginal walls (exclusion of STI, foreign body, trauma, determination of the bleeding site), and at the same time take a swab to determine bacteriological culture (for *Neisseria gonorrhoeae* and *Chlamydia trachomatis*); in the combined two-handed examination — determine the correctness of the uterine body and appendages (excluding palpation, nodular changes). Sometimes there is a need for a gynecological examination under general anesthesia, even in sexually active girls [1–8].

As a supplement to the AUB diagnostic process, it is recommended to perform an ultrasound examination of the smaller pelvis (transabdominal transducer with a full bladder, rectal or vaginal — in sexually active girls), especially in the case when gynecological examination shows an adnexal lesion, suspected developmental defects of the reproductive organ or when gynecological examination cannot be performed due to profuse bleeding. In individual indications, other imaging tests can also be performed (computed tomography, magnetic resonance imaging) [1–8].

#### Laboratory tests

The routine laboratory tests in the diagnosis of adolescent bleeding in girls include [3–5, 7–8]:

- pregnancy test (serum  $\beta$ HCG level, alternatively urine test) — pregnancy exclusion;
- complete blood count (with level of platelets, reticulocytes);
- glucose level;
- assessment of the coagulation system (prothrombin time — PT, activated partial thromboplastin time — APTT, bleeding time, activity of selected coagulation factors); PT and APTT will always be abnormal even in mild coagulation disorders; with NSAIDs, the bleeding

time should be assessed 24–48 hours after discontinuing NSAID;

- von Willebrand factor level assessment (to be performed a few weeks after discontinuation of estrogen therapy, which overstates the actual factor level) — approximately 24% of girls with chronic HMB have von Willebrand disease;
  - blood group (blood group 0 is associated with a lower level of von Willebrand factor).
- In selected clinical cases, laboratory diagnostics should be extended to hormonal tests [3–5, 7–8]:
- TSH, fT4, fT3 (exclude thyroid disorders);
  - prolactin (may be slightly elevated after examination of the mammary glands, level > 100 ng/mL suggests pituitary adenoma);
  - serum androgen levels (total and free testosterone, DHEAS, 17-OH-progesterone, androstendione), especially with symptoms of hyperandrogenism;
  - LH and FSH (assessment of the functions of the pituitary gland and ovaries).

The American College of Obstetricians and Gynecologists (ACOG) recommends routine coagulation tests for AUB in girls who are under 18 years of age and have symptoms of abnormal uterine bleeding, especially if their Hb level is less than 10 g/dL. At the same time, these patients should be screened for anemia. In addition, screening for disorders of the coagulation system should be performed in girls in the case of: menstruation lasting  $\geq 7$  days with heavy bleeding interfering daily activities, history of treatment of anemia, family history of coagulation disorders, excessive bleeding after tooth extraction or surgery [8].

### The treatment of AUB

Treatment of abnormal uterine bleeding in girls depends on the etiology, severity of the bleeding and the degree of maturity of the hypothalamic-pituitary-ovarian system. The principle of hormonal treatment of juvenile bleeding is estrogen supplementation to heal the bleeding sites in the atrophic endometrium and stimulate its proliferation and progestogens (in the luteal phase) to stabilize the uterine mucosa and regulate the menstrual cycle [1–9].

#### Mild AUB

Mild AUB is a prolonged period of menstrual bleeding or a shortened menstrual cycle lasting from at least 2 months; menstrual blood loss is moderate and the Hb level is > 12 g/dL [1–9].

The therapeutic management of AUB of mild severity is preservative (proper diet, lifestyle). It is recommended to keep a menstrual calendar in order to closely monitor the following periods. Individually, according to indications, you can also use: vitamins and iron (preventing ane-

mia), antifibrinolytic drugs that reduce menstrual blood loss by about 40–50% (aminocaproic acid 20 mg/kg/day in 2–3 doses, tranexamic acid 1–1.5 g orally 3–4 times/day up to 5 days during menstruation), non-steroidal anti-inflammatory drugs (recommended: mefenamic acid 250 mg 2–4 times/day, naproxen 250–500 mg 2–4 times/day, ibuprofen 600–1200 mg/day, flurbiprofen, diclofenac, indomethacin), which reduce the amount of bleeding [1–9].

In the case of mild juvenile bleeding, follow-up is recommended after 3 months or earlier, when the applied treatment does not bring the expected results [1–9].

#### Moderate AUB

Moderate AUB is defined as prolonged and /or heavy menstrual bleeding (greater than 7 days) or shortening of the menstrual cycle with frequent periods (every 7–21 days); the loss of menstrual blood is moderate, and Hb levels indicate mild anemia (Hb within 10–12 g/dL) [1–9].

Estrogen–progestogen (E–P) therapy, oral contraceptives (OCs), or progestogen therapy alone can be used to treat moderate AUB. E–P therapy is recommended when the bleeding persists for a long time and the thickness of the endometrium on ultrasound examination does not exceed 5 mm. The following treatment regimen is proposed [1–9]:

##### E–P therapy (initial stage):

- estrogen orally 2 × 2 mg for 20 days;
- from day 10, additionally include: dydrogesterone 20 mg/d or micronized progesterone; 100–150 mg/d for the next 10–14 days;

##### E–P therapy (cycle 2):

- oral estrogen 2 × 2 mg from the 5<sup>th</sup> day of the cycle for 20 days;
- from the 15<sup>th</sup> day of the cycle, additionally include: dydrogesterone 20 mg/d or micronized progesterone 100–150 mg/d for the next 10 days;

##### E–P therapy (cycle 3 and 4):

- oral estrogen 1 × 2 mg from the 5<sup>th</sup> day of the cycle for 20 days;
- from the 15<sup>th</sup> day of the cycle, additionally include: dydrogesterone 20 mg/d or micronized progesterone 100–150 mg/d for the next 10 days;

##### E–P therapy (cycle 5 and 6):

- oral estrogen 1 × 1 mg from the 5<sup>th</sup> day of the cycle for 20 days;
- from the 15<sup>th</sup> day of the cycle, additionally include: dydrogesterone 20 mg/d or micronized progesterone 100–150 mg/d for the next 10 days.

An alternative to E–P therapy (according to ACOG standards) is oral combined hormonal contraception. Good results are obtained with the use of OCs containing 30–35  $\mu$ g ethinylestradiol or natural estradiol and a progestogen ensuring adequate cycle control and endometrial stabilization (rec-

recommended: norgestrel 0.3 mg or levonorgestrel 0.15 mg). OCs containing desogestrel, norgestimate, dydrogesterone and dienogest also have a beneficial therapeutic effect. In case of moderate bleeding and mild anemia, it is recommended to use 1 tablet/day for 21 days [10].

When bleeding and anemia are more severe, the recommended dosage is:

- 1 pill 2 times/day for 3–4 days, until the bleeding stops completely;
- then: 1 pill/day until the end of the 21-day treatment cycle.

If bleeding returns during the above therapy, the dose of OCs should be increased to 2 tablets/day until the end of the 21-day treatment cycle.

Only in the case of massive bleeding and significant anemia is the following treatment regimen exceptionally proposed [10]:

- 1 pill 4 times/day for 2–4 days;
- 1 pill 3 times/day for 3 days;
- 1 pill 2 times/day for 2 weeks.

When using such high doses of OCs, due to side effects, it is often necessary to start antiemetics (recommended 2 hours before each dose of OCs). OCs should be used in the 21 + 7 scheme, but if the withdrawal bleeding is too heavy, the interval between packages should be shortened to 3–4 days. In order to obtain the best cycle control, it is recommended to extend the OCs therapy (1 tablet/day) to 3–6 menstrual cycles [10].

If there are contraindications to the inclusion of estrogens or OCs, or there is poor tolerance of the above regimens, and as a continuation of EP or OCs therapy, it is recommended to use only progestagens — cyclically in the second phase of the menstrual cycle (for 10–12 days when the bleeding is moderate or 12–14 days when the bleeding is moderate, prolonged and abundant). Recommended progestogens, well stabilizing the endometrium in adolescents, are MPA (10–20 mg/day), 19-nortestosterone derivatives: NETA (5–10 mg/day) and lynesterol (5–10 mg/day) and dydrogesterone (10–20 mg/day). Alternatively, one can administer progesterone (100–200 mg) intramuscularly once, followed by a 10–14-day substitution with oral progestogen. The use of cyclic progestogenic therapy should be continued for the next 3–6 months [9].

There are also clinical reports showing a beneficial effect of the intrauterine hormonal contraceptive system (releasing levonorgestrel) and long-acting GnRH analogues (used for the longest period of 6 months) in the treatment of moderate and severe adolescent bleeding [11].

Additionally, in moderate AUB, according to individual indications, the following can be used: vitamins and iron preparations (correction of anemia), antifibrinolytics, NSAIDs and possibly antibiotic therapy [1–9].

### Severe AUB

Severe AUB is defined as profuse, prolonged vaginal bleeding associated with a disturbed menstrual cycle; menstrual blood loss is significant and Hb levels indicate significant anemia (Hb levels < 10 g/dL). Symptoms of increasing anemia and haemodynamic failure are often observed, and in most cases hospitalization is indicated (especially when Hb < 7 g/dL).

In the treatment of severe AUB (Hb 8–10 g/dL) and haemodynamic stability, it is recommended to use E–P therapy in the following scheme [1–9]:

#### E–P therapy (initial stage):

- oral estrogen 2–4 mg every 6 hours until bleeding stops or significantly reduces, then:
- estrogen orally 2 × 2 mg until the end of the 20-day treatment cycle;
- from day 10, additionally include: dydrogesterone 20 mg/d or micronized progesterone 100–150 mg/d for the next 10–14 days;

#### E–P therapy (cycle 2):

- oral estrogen 2 × 2 mg from the 5<sup>th</sup> day of the cycle for 20 days;
- from the 15<sup>th</sup> day of the cycle, additionally include: dydrogesterone 20 mg/d or micronized progesterone 100–150 mg/d for the next 10 days;

#### E–P therapy (cycle 3 and 4):

- oral estrogen 1 × 2 mg from the 5<sup>th</sup> day of the cycle for 20 days;
- from the 15<sup>th</sup> day of the cycle, additionally include: dydrogesterone 20 mg/d or micronized progesterone 100–150 mg/d for the next 10 days;

#### E–P therapy (cycle 5 and 6):

- oral estrogen 1 × 1 mg from the 5<sup>th</sup> day of the cycle for 20 days;
- from the 15<sup>th</sup> day of the cycle, additionally include: dydrogesterone 20 mg/d or micronized progesterone 100–150 mg/d for the next 10 days.

Alternatively (ACOG guidelines) in the treatment of severe AUB (Hb 8–10 g/dL) and ineffectiveness of E–P therapy, the use of OCs (containing 30–50 µg ethinylestradiol and norgestrel/levonorgestrel) is exceptionally proposed in the following scheme [10]:

- 1 pill every 4 hours until bleeding stops or is significantly reduced then:
- 1 pill 4 times/day for 2–4 days;
- 1 pill 3 times/day for 3 days;
- 1 pill 2 times/day until the end of the 21-day treatment cycle.

With such high doses of OCs, it is usually necessary to include antiemetics. OCs therapy should be continued (1 tablet/day) for the next 3–6 menstrual cycles. OCs should be used in the 21 + 7 scheme, but if the withdrawal bleed

is too heavy, the interval between consecutive packages should be shortened to 3–4 days [10].

When severe AUB (Hb < 7 g/dL) is accompanied by symptoms of haemodynamic failure, urgent hospitalization is recommended; the necessity to transfuse fluids and red blood cells preparation (individual indications) should also be taken into account. In the case of very massive bleeding, intravenous/intramuscular administration of estrogens is recommended to obtain a hemostatic effect: 25 mg of conjugated estrogens iv. every 4–6 hours or 10–20 mg i.m. estradiol valerate once (Estradiol Depot) during the first day. OCs should be turned on in the next 24–48 hours to deliver the progestogen and stabilize the endometrium; then use OCs continuously for several consecutive cycles, abandoning menstrual bleeding in order to compensate for iron deficiency [1–10].

In case of contraindications to estrogen therapy or OCs, progestogens can be used (MPA 10 mg, NETA 5–10 mg or lynesterol 5–10 mg 4 times/day for 4 days, 3 times/day for 3 days and then 2 times/day for 14 days) but the effectiveness of such therapy in severe AUB is limited [9].

An alternative treatment option for severe juvenile bleeding is the intrauterine hormonal contraceptive system (releasing levonorgestrel) or long-acting GnRH analogues (used for the longest period of 6 months) [11].

Abrasion of the uterine cavity may be considered as an exceptional indication in girls when hormonal treatment (various regimens) is ineffective and bleeding continues for another 24–36 hours [2].

In the adjunctive therapy of severe AUB, the following are recommended: antiemetics, antifibrinolytics, vitamins, iron and folic acid supplementation (anemia correction), NSAIDs and antibiotic therapy. Antibiotic therapy is recommended in order to reduce the inflammatory component in cases where bleeding lasts more than 10 days, the uterus is painful at examination, and when there are symptoms of infection [1–9].

The correct diagnostic and therapeutic process of AUB should stop the bleeding and prevent its recurrence, explain the cause of the symptoms and prevent the intensification of co-occurring endocrine disorders (*e.g.* acne, hirsutism, obesity in the course of PCOS). It is estimated that about

10–15% of girls with symptoms of juvenile bleeding will forever remain anovulatory menstrual cycles and will develop PCOS. Therefore, in the case of abnormal uterine bleeding during adolescence, long-term follow-up is recommended, ensuring constant control of symptoms and preventing long-term complications interfering the reproductive functions of a young woman (persistent disorders of the menstrual cycle, hormonal dysfunction, fertility disorders).

### Conflict of interest

None declared.

### REFERENCES

1. Sokkary N, Dietrich JE. Management of heavy menstrual bleeding in adolescents. *Curr Opin Obstet Gynecol.* 2012; 24(5): 275–280, doi: [10.1097/GCO.0b013e3283562bcb](https://doi.org/10.1097/GCO.0b013e3283562bcb), indexed in Pubmed: [22729091](https://pubmed.ncbi.nlm.nih.gov/22729091/).
2. Haamid F, Sass AE, Dietrich JE. Heavy menstrual bleeding in adolescents. *J Pediatr Adolesc Gynecol.* 2017; 30(3): 335–340, doi: [10.1016/j.jpag.2017.01.002](https://doi.org/10.1016/j.jpag.2017.01.002), indexed in Pubmed: [28108214](https://pubmed.ncbi.nlm.nih.gov/28108214/).
3. Mullins TL, Miller RJ, Mullins ES. Evaluation and management of adolescents with abnormal uterine bleeding. *Pediatr Ann.* 2015; 44(9): e218–e222, doi: [10.3928/00904481-20150910-09](https://doi.org/10.3928/00904481-20150910-09), indexed in Pubmed: [26431240](https://pubmed.ncbi.nlm.nih.gov/26431240/).
4. Committee on Practice Bulletins—Gynecology. Practice bulletin no. 128: diagnosis of abnormal uterine bleeding in reproductive-aged women. *Obstet Gynecol.* 2012; 120(1): 197–206, doi: [10.1097/AOG.0b013e328318262e320](https://doi.org/10.1097/AOG.0b013e328318262e320), indexed in Pubmed: [22914421](https://pubmed.ncbi.nlm.nih.gov/22914421/).
5. Bennett AR, Gray SH. What to do when she's bleeding through: the recognition, evaluation, and management of abnormal uterine bleeding in adolescents. *Curr Opin Pediatr.* 2014; 26(4): 413–419, doi: [10.1097/MOP.000000000000121](https://doi.org/10.1097/MOP.000000000000121), indexed in Pubmed: [25007322](https://pubmed.ncbi.nlm.nih.gov/25007322/).
6. Matteson KA, Scott DM, Raker CA, et al. The menstrual bleeding questionnaire: development and validation of a comprehensive patient-reported outcome instrument for heavy menstrual bleeding. *BJOG.* 2015; 122(5): 681–689, doi: [10.1111/1471-0528.13273](https://doi.org/10.1111/1471-0528.13273), indexed in Pubmed: [25615842](https://pubmed.ncbi.nlm.nih.gov/25615842/).
7. LaCour DE, Long DN, Perlman SE. Dysfunctional uterine bleeding in adolescent females associated with endocrine causes and medical conditions. *J Pediatr Adolesc Gynecol.* 2010; 23(2): 62–70, doi: [10.1016/j.jpag.2009.06.003](https://doi.org/10.1016/j.jpag.2009.06.003), indexed in Pubmed: [20347757](https://pubmed.ncbi.nlm.nih.gov/20347757/).
8. Long S. Implementing screening recommendations for adolescents with heavy menstrual bleeding. *The Journal of Pediatrics.* 2015; 166(1): 1–3, doi: [10.1016/j.jpeds.2014.10.061](https://doi.org/10.1016/j.jpeds.2014.10.061).
9. Hickey M, Higham J, Fraser IS, et al. Progestogens versus oestrogens and progestogens for irregular uterine bleeding associated with anovulation. *Cochrane Database Syst Rev.* 2000(2): CD001895, doi: [10.1002/14651858.CD001895](https://doi.org/10.1002/14651858.CD001895), indexed in Pubmed: [10796833](https://pubmed.ncbi.nlm.nih.gov/10796833/).
10. Farquhar C, Brown J. Oral contraceptive pill for heavy menstrual bleeding. *Cochrane Database Syst Rev.* 2009(4): CD000154, doi: [10.1002/14651858.CD000154.pub2](https://doi.org/10.1002/14651858.CD000154.pub2), indexed in Pubmed: [19821266](https://pubmed.ncbi.nlm.nih.gov/19821266/).
11. Lethaby AE, Cooke I, Rees M, et al. Progesterone/progestogen releasing intrauterine systems versus either placebo or any other medication for heavy menstrual bleeding. *Cochrane Database Syst Rev.* 2000(2): CD002126, doi: [10.1002/14651858.CD002126](https://doi.org/10.1002/14651858.CD002126), indexed in Pubmed: [10796865](https://pubmed.ncbi.nlm.nih.gov/10796865/).

# Recommendations of the Expert Group of the Polish Society of Gynecologists and Obstetricians regarding gynecological examination and treatment of a minor during the SARS-CoV-2 pandemic

Agnieszka Drosdzol-Cop<sup>1</sup>, Anna Fuchs<sup>1</sup>, Agnieszka Dulaska<sup>1</sup>, Violetta Skrzypulec-Plinta<sup>2</sup>

<sup>1</sup>Chair and Department of Gynecology, Obstetrics and Oncological Gynecology, Medical University of Silesia in Katowice, Poland

<sup>2</sup>Chair of Woman's Health, Medical University of Silesia in Katowice, Poland

**Keywords:** adolescents, SARS-CoV-2 coronavirus infection, gynecological examination

The recommendations present current methods of treatment that may be subject to modification and change in justified cases, after careful analysis of the given clinical situation. In the future, this may be the basis for their modification and updating.

Due to the spread of SARS-CoV-2 coronavirus infection and the reported increase in COVID, there was a need to set new standards for gynecological care for children and adolescents during a pandemic.

## Planning a visit

The child population is characterized by a low incidence of COVID-19. Over 90% of children infected with SARS-CoV-2 had contact to a sick person in their own household. Although children often have an asymptomatic infection, it is rare for any of the household members to experience no disease symptoms. Therefore, before planning a visit to the gynecologist, it is particularly important to conduct a thorough interview about the health status of the child and his household.

Before each planned medical procedure on a child, it is recommended to collect a thorough epidemiological interview with his legal guardian. The questions should relate to possible contact within the last 14 days with a person with confirmed COVID-19, a person in quarantine or in isolation. You should also ask questions about the current symptoms of the child and his or her household that indicate COVID-19 infection, *i.e.* fever, cough, sore throat, vomiting and diarrhea, weakness and loss of smell or taste. It is important to inquire about possible contact of household members with a person from epidemiological outbreaks, *i.e.* as employees of the mine in Silesia.

According to the announcements of the Polish Pediatric and Adolescent Gynecology (Polish PAG), it is not recommended that scheduled visits to the doctor's office be preceded by tests for SARS-CoV-2 infection. Of course, if any of the household members received a positive result, and the planned procedure is not necessary to save the child's health or life, it should be postponed to the nearest date safe for both parties [1].

## Before gynecological examination

A National Consultant in Obstetrics and Gynecology recommends that only healthy patients should be admitted for a visit to the gynecologist. It is also recommended to give up the presence of an accompanying person [2]. According to the applicable provisions of the Civil Code, a minor is one who is under 18 years of age. The exceptions are women after 16 years of age who, with the consent of the family court, got married and thus became of legal age. Therefore, the visit of a child and teenager in a gynecological office is associated with the presence of an additional person — their legal guardian. This should be borne in mind when collecting epidemiological history of both the patient and the person accompanying her during the examination [3].

Visits are planned at appropriate intervals to minimize the risk of contact with other patients. Patients should use personal protective equipment (*i.e.* masks, gloves), excluding children under 4 years of age for whom masks are not recommended. Before visiting a doctor, it is recommended that patients wash their hands with warm water and soap for 30 seconds according to hand washing instructions [4].

Corresponding author:

Agnieszka Drosdzol-Cop

Chair and Department of Gynecology, Obstetrics and Oncological Gynecology, Medical University of Silesia in Katowice, Poland  
Markiefki 87, 40-211 Katowice; Phone: +48 32 208 8751



### The course of the visit at the gynecological office during a pandemic

Gynecological examination is one of the most intimate medical procedures, extremely stressful and embarrassing for young girls. Mother's help is invaluable in this case. Appropriate preparation of the patient for examination by the mother / guardian significantly reduces the child's anxiety and improves the well-being of the minor before the examination. Earlier conversation about the gynecological examination has become particularly important during a pandemic, when the doctor's contact with the patient is significantly limited in time and takes place under sanitary regime with distance and the use of personal protective equipment [5].

An unusual doctor's outfit, *i.e.* a mask, a visor, goggles, tight aprons, can negatively affect the reception of the youngest patients, so it is important for the parent to prepare the child for such a situation.

A minor gynecological examination should be performed by an experienced pediatric gynecologist. In urgent cases, *i.e.* after genital trauma, the examination may be carried out by an experienced obstetrician-gynecologist or other specialist with due diligence in both the examination and medical records [6].

A pandemic has no effect on the indications for a minor gynecological examination. The most important of them, requiring an immediate visit regardless of the symptoms of COVID-19 infection or contact with an infected person, include: suspected sexual abuse, trauma to the genitals and pelvis, abdominal or abdomen pain, genital infections, abnormal genital bleeding.

Other indications for gynecological examination in girls, especially of a preventive nature, are assessed individually by the doctor. In the case of girls with a positive epidemiological history, if visit cancellation does not directly affect her health and life, it is recommended to postpone the examination. An appointment can then be scheduled after a minimum of 14 days has elapsed since contact with an infected person or in isolation (without symptoms), or immediately after obtaining two negatives COVID-19 swab result [6, 7].

### Medical history and physical examination

The current epidemiological situation does not significantly change the standards of collecting medical history and physical examination. However, the fact that the test time is reduced to the necessary minimum remains important. When possible, *e.g.* during an interview, it is a good habit to keep a safe distance between the doctor and patient.

Both medical history and physical examination should be conducted in accordance with the recommendations of the Polish Society of Gynecology and Obstetrics. Pursuant to the provisions of the Family and Guardianship Code, the examination should be carried out in the presence of a legal repre-

sentative (parent or legal guardian). It should be remembered that a minor may ask for a gynecological examination without witnesses (parent/guardian), which should be noted in the medical records. If the legal representative does not agree, this fact should be noted in the medical documentation and the examination might be then carried out in his presence [3, 7].

During the examination, the staff work in personal protective equipment according to the recommendations of the National Consultant in the field of Anaesthesiology and Intensive Care developed on the basis of the European Center for Disease Control and Prevention, and all equipment in direct contact with the patient is one-of [4].

After the gynecological examination, the patient and her parent/guardian should be provided with information on the patient's health, examination result and diagnosis. Next, possible further diagnostic and therapeutic methods, foreseeable consequences of their use or omission, and prognosis should be presented in an accessible way.

The pediatric gynecologist should also propose to a statutory representative and a minor over 16 years of age to carry out selected preventive examinations (including cytological examinations, with a recommendation every 12 months for sexually active minors) and the possibility of prophylaxis of HPV infection (protective vaccinations). In patients with negative epidemiological history of COVID-19, both cytological examination and vaccination against HPV can be safely performed even during a pandemic [8].

### REFERENCES

1. PTP. Komunikat 1. Planowe hospitalizacje i badania diagnostyczne u dzieci w okresie pandemii SARS-CoV-2. [https://ptp.edu.pl/dokumenty/covid/Komunikat\\_kk\\_2020.05.04.pdf](https://ptp.edu.pl/dokumenty/covid/Komunikat_kk_2020.05.04.pdf) (access: 20.07.09).
2. Opieka nad kobietą w okresie okołoporodowym w sytuacji zagrożenia epidemiologicznego. <https://www.mp.pl/ginekologia/aktualnosci/230408,opieka-nad-kobieta-w-okresie-okoloporodowym-w-sytuacji-zagrozenia-epidemiologicznego> (access: 2020.07.09).
3. Szczygieł K, Szełalski T. Pozycja małoletniego w procesie wyrażania zgody na zabieg leczniczy [The position of a minor in the process of consenting to a therapeutic procedure]. *Przeegląd Prawniczy UW*. 2013 (1-2).
4. European Centre for Disease Prevention and Control. Guidance for wearing and removing personal protective equipment in healthcare settings for the care of patients with suspected or confirmed COVID-19. Stockholm: ECDC; 2020 (access: 2020.07.09).
5. Skrzypulec-Plinta V, Drosdzol-Cop A. In: *Ginekologia dziecięca i dziewczęca*. [Pediatric and Adolescent Gynecology. 2016; 1: 1–46.
6. Drosdzol-Cop A, Skrzypulec-Plinta V, Guzik-Makaruk EM, et al. Rekomendacje Grupy Ekspertów Polskiego Towarzystwa Ginekologów i Położników dotyczące badania ginekologicznego i leczenia osoby małoletniej (stan na 1.01.2020 r.) [Recommendations of the Expert Group of the Polish Society of Gynecologists and Obstetricians regarding gynecological examination and treatment of a minor (state for 1.01.2020)]. *Ginekologia i Perinatologia Praktyczna*. 2019; 4(4): 164–167.
7. Jackowska T, Peregud-Pogorzelski J, Marczyńska M, et al. Recommendations of the Polish pediatric society and the national consultant in the field of pediatrics regarding outpatient care for children during the COVID-19 pandemic, caused by the SARS-COV-2virus. *Przeegląd Pediatryczny*. 2020; 49 (2): 19–23.
8. Ministerstwo Zdrowia. Komunikat w sprawie wykonywania szczepień ochronnych w czasie pandemii COVID-19. <https://www.gov.pl/web/zdrowie/komunikat-sprawie-wykonywania-szczepien-ochronnych-w-czasie-pandemii-covid-19> (access: 2020.07.09).

# Practice guidelines of the Polish Society of Gynecologists and Obstetricians — Ultrasound Section for ultrasound screening in uncomplicated pregnancy — 2020

Dariusz Borowski<sup>1</sup>, Marek Pietryga<sup>2</sup>, Paweł Basta<sup>3</sup>, Wojciech Cnota<sup>4</sup>,  
Bartosz Czuba<sup>4</sup>, Mariusz Dubiel<sup>5</sup>, Tomasz Fuchs<sup>6</sup>, Hubert Huras<sup>7</sup>, Rafał Iciek<sup>8</sup>,  
Renata Jacyńska<sup>9</sup>, Piotr Kaczmarek<sup>10</sup>, Przemysław Kosinski<sup>11</sup>,  
Sebastian Kwiatkowski<sup>12</sup>, Agnieszka Nocun<sup>13</sup>, Michał Pomorski<sup>6</sup>,  
Mariola Ropacka-Lesiak<sup>14</sup>, Magda Rybak-Krzyszowska<sup>13</sup>, Piotr Sieroszewski<sup>15</sup>,  
Piotr Węgrzyn<sup>16</sup>, Marcin Wiechec<sup>17</sup>, Mirosław Wielgos<sup>11</sup>, Mariusz Zimmer<sup>6</sup>

<sup>1</sup>Clinic of Fetal-Maternal, Gynecology and Neonatology, Collegium Medicum, Nicolaus Copernicus University in Bydgoszcz, Poland

<sup>2</sup>Department of Obstetrics and Women's Diseases, Poznan University of Medical Sciences, Poznan, Poland

<sup>3</sup>Chair of Gynecology and Obstetrics, Department of Gynecology and Oncology, Jagiellonian University Medical College, Cracow, Poland

<sup>4</sup>Department of Obstetrics and Gynecology in Ruda Śląska, Medical University of Silesia, Poland

<sup>5</sup>Department of Maternal-Fetal Medicine and Gynecology, Chair of Obstetrics, Bydgoszcz, Poland

<sup>6</sup>2<sup>nd</sup> Department of Gynecology and Obstetrics, Wrocław Medical University, Wrocław, Poland

<sup>7</sup>Jagiellonian University Collegium Medicum, Department of Obstetrics and Perinatology, Cracow, Poland

<sup>8</sup>Department of Obstetrics and Women's Diseases, Karol Marcinkowski University of Medical Sciences, Poznan, Poland

<sup>9</sup>Clinic of Obstetrics and Gynecology, Institute of Mother and Child, Warsaw, Poland

<sup>10</sup>Operative Gynecology and Oncological Gynecology Clinic, Polish Mother's Memorial Hospital-Research Institute, Lodz, Poland

<sup>11</sup>1<sup>st</sup> Chair and Department of Obstetrics and Gynecology, Medical University of Warsaw, Poland

<sup>12</sup>Department of Obstetrics and Gynecology, Pomeranian Medical University in Szczecin, Poland

<sup>13</sup>Department of Obstetrics and Perinatology, University Hospital in Cracow, Poland

<sup>14</sup>Department of Perinatology and Gynecology, Poznan University of Medical Sciences, Poland

<sup>15</sup>Department of Fetal Medicine and Gynecology, Medical University of Lodz, Poland

<sup>16</sup>Department of Obstetrics and Perinatology, Medical University of Warsaw, Poland

<sup>17</sup>Department of Gynecology and Obstetrics, Faculty of Medicine, Jagiellonian University Medical College, Cracow, Poland

## INTRODUCTION

The Ultrasonography Section of the Polish Society of Gynecologists and Obstetricians and Obstetrics is an organization promoting the development of ultrasound prenatal diagnostics and supporting the education of doctors and patients. The aim of the update of existing Guidelines from 2015 is to organize and indicate the optimal scheme of performing ultrasound examinations in uncomplicated pregnancies [1].

These updated Guidelines are in accordance with the Standards of international organizations such as the Inter-

national Society of Ultrasound in Obstetrics and Gynecology (ISUOG 2010, 2013, 2016, 2019), the American College of Obstetricians and Gynecologists (ACOG) and the Fetal Medicine Foundation (FMF 2013, 2016, 2019).

Ultrasound examination is an essential diagnostic tool during pregnancy. According to the Standards of the Polish Society of Gynecologists and Obstetricians for uncomplicated pregnancy management, this test should be offered to all pregnant women, at least four times during pregnancy. The purpose of the examination is different depending on the stage of pregnancy.

### Corresponding author:

Dariusz Borowski

Clinic of Fetal-Maternal, Gynecology and Neonatology, Collegium Medicum, Nicolaus Copernicus University in Bydgoszcz, Poland  
e-mail: darekborowski@gmail.com

### What is the purpose of an ultrasound examination?

The primary goal of ultrasound evaluation during pregnancy is to minimize the occurrence of unfavorable obstetric outcomes that may result from undiagnosed congenital defect in the fetus, fetal immaturity or other intrauterine complications. The task of the doctor performing ultrasound screening is to refer the pregnant woman to a referral center in every case of diagnostic doubts or suspected abnormal fetal development.

At each stage of fetal development, the ultrasound scan has different scope. The purpose of the examination is different in the first trimester of pregnancy as opposed to the second and third trimesters. The post-delivery term examination is also characterized by certain differences. Regardless of the period of pregnancy during which the test is performed, the doctor should present the pregnant woman undergoing the test with a written result of the test with data enabling the identification of both the person under examination and the investigator and a summary with detailed elements of fetal anatomy which have been assessed and biometric measurements. The printout of the ultrasound image is not the result of the examination, but only supplementary documentation which may be part of the results. The patient should also receive comprehensive information about the results.

### Who should receive an ultrasound examination?

In accordance with current legislation, ultrasound-based screening should be offered to all pregnant women. Refusal by the patient to undergo the examination should be documented, in writing, preferably with the pregnant woman's signature.

### Is ultrasound examination safe?

At present, there are no study results suggesting that ultrasonography has an adverse effect on fetal development. When performing this examination, it is necessary to follow the principle of minimal exposure and time of examination to complete the procedure — **ALARA (As Low As Reasonably Achievable)**. In particular, the values of thermal (TI) and mechanical (MI) indexes should be below 1, during the entire study ( $TI < 1$ ,  $MI < 1$ ). The safety principles of ultrasound examination are described in detail in separate publications [2].

### What are the ultrasound equipment requirements?

Ultrasound for gynecological diagnostics should have the following capabilities: 2D real time, at least 128-step grey scale image, capacity to measure distance (at least two dimensions), circumference and surface area and obstetric software. Additionally, they should be equipped with

transabdominal and transvaginal transducers with capacity to print and store images.

### What should an ultrasound results include?

An ultrasound examination results should present the following data:

- patient's first and last name, date of birth and Personal Identification Number (PESEL),
- place and date of examination, first and last name of the examiner,
- Information regarding the name of the ultrasound and the type and frequency of the transducers used
- initial diagnosis written by the referring physician, if not a routine examination
- date of last menstrual period and gestational age based on last menstrual period
- If it is difficult to determine the date of last menstrual period, the gestational age should be determined by the crown-rump length (CRL) in the first trimester. In the absence of testing in the first trimester of the pregnancy, the gestational age is determined based on HC measured in the second trimester of pregnancy.
- The examining doctor information which should consist of a stamp and his/her signature

It should be clearly stated that any deviation from the normal condition of the fetus, the pelvic organ/uterus and any other abnormal symptoms diagnosed during the examination should also be included in the description of the examination. Oral communication of such information is not acceptable without an appropriate note in the result.

If a complete examination cannot be performed it should be noted in the examination result, and guidelines should be given on how to proceed and whether a further examination is planned. Elements which were unable or incomplete to visualize should be marked in the examination results. If a complete examination cannot be carried out or there insurmountable technical constraints during pregnancy affecting the quality of the ultrasound examination (e.g. due to the pregnant woman's being overweight or obese, defects of the uterus, retroverted uterus, uterine fibroids etc.), this fact should be noted in the examination result, and guidelines should be given on how to proceed and whether a further examination is planned.

When informing pregnant woman/parents about the result of the ultrasound examination, attention should be paid to the limitations of this method and the impossibility of excluding all anatomical defects.

### ULTRASOUND EXAMINATION BEFORE 10 WEEKS OF GESTATION

The ultrasound examination during this period of pregnancy should be performed with a transvaginal transducer. This

examination is not mandatory, and we perform it on medical indications. The purpose of the ultrasound examination before 10 weeks of pregnancy, performed on medical indications, is:

- a) **Image and location of the fertilized egg** — confirmation of the presence of an intrauterine pregnancy or confirmation of a pregnancy with an unknown location. Special attention should be paid to the location of the gestational sac in patients after Caesarean sections due to the risk of pregnancy implantation in the scar after hysterotomy [3–5]. In case of any doubts in this respect, the patient should be referred for examination at the referral center.
- b) **Assessment of gestational age** — based on fetal crown-rump length measurement (CRL)
- c) **Assessment of the presence of the gestational sac** — measurement of the gestational sac (GS - mean of 3 dimensions), position in the uterine cavity, number of gestational sacs. Until the embryo is visualized and until CRL measurement, with GS values above 20 mm and absent embryo there is a high risk of miscarriage.
- d) **Assessment of trophoblast echostructure** for trophoblastic disease in the case of subjective hypertrophy of a chorionic echostructure typical in molar pregnancy (numerous small and disseminated hypoechogenic fields in the chorionic area), serum level of  $\beta$ -hCG determination should be ordered and the pregnant woman should be referred to hospital.
- e) **Assessment of the number of embryos, chorions and amnions** — note: in case of a multiple pregnancy, the *chorionicity and amnionicity* should be determined by assessing the visibility of two separate or one common gestational sac.
- f) **Assessment of the yolk sac (YS)** — presence of the YS (yes/no), description of possible YS irregularities. Note: If GS is present in the absence of YS or the embryo, attention should be paid to the possibility of ectopic pregnancy (pseudogestational sac).
- g) **Assessment of the presence of the embryo** — presence (yes/no), CRL measurement, presence of the FHR (with CRL over 4 mm). Note: Using the transvaginal transducer, the FHR is visible with  $CRL \geq 4$  mm. In case of absent FHR with  $CRL < 5$  mm — the examination should be repeated to confirm the proper development of pregnancy.
- h) **Using the Doppler technique** in the examination before 10 weeks of pregnancy, including for FHR assessment, is not recommended. It is preferred that FHR is shown in 2D (the so-called B presentation) or M-mode. The presence of bradycardia below 80 beats per minute increases the risk of miscarriage.
- i) **Evaluation of the genital organs of the pregnant woman** — uterus together with the cervix (regular, ir-

regular shape), anatomy (normal, abnormal – defects, myomas). We assess the outline and presence of focal lesions, *i.e.* mainly myomas in terms of their location and relationship with the trophoblast. Differential diagnosis of congenital defects of the uterus during pregnancy is limited, but the focus should be on the possible presence of a septate uterus (the septum has a myometrial echostructure and remains in continuity with the uterine wall), a double uterus and a unicornuate uterus with a residual horn. In contrast, the chorionic strands which do not pose a threat to the development of the fetus are hyperechoic and remain in continuity with the trophoblast. The assessment of the cervix should include the possible presence of focal lesions such as myomas or the proliferative process (irregular focal lesions with uneven contours most often hypoechogenic with increased vascularization). The assessment of appendages for focal changes should be based on the system of simple rules, according to the terminology of the IOTA group. The examination technique is described in detail in recommendations for gynecological ultrasounds. Note: Abnormal masses in appendages should be described. If there are uterine myomas, describe their location and take measurements. The recto-uterine pouch should be examined for the presence of free fluid. The thickness of the fluid layer should be measured at cervical level following a perpendicular measurement line, the value of the measurement above 10 mm should be recorded in the result of the test. If there is no deviation from the standard, a detailed description is not necessary, but a statement is sufficient, for example: “uterus and appendages without pathological changes”.

### **ULTRASOUND EXAMINATION BETWEEN 11<sup>+0</sup>–13<sup>+6</sup> WEEKS OF PREGNANCY (CRL BETWEEN 45–84 MM)**

The ultrasound examination performed at this stage of pregnancy involves several assumptions. The doctor providing prenatal care is obliged to explain to the patient the validity of these examinations. Each patient has the right to receive information about the possibility of performing prenatal tests. Such an obligation is imposed by Art. 38. Point 3 of the Code of Medical Ethics, which states: “A doctor is obliged to inform patients with the possibilities of modern medical genetics, prenatal diagnosis and therapy.” In some Patients, these tests may be reimbursed by the National Health Fund (NFZ) within the framework of the Prenatal Screening Program, provided that the Patients meet the criteria for inclusion in the program.

The primary objective is to assess the anatomical structures of the fetus, to search for early structural defects and to assess the size of the fetus and determine the duration

of pregnancy, the date of birth, if this has not been done reliably at an earlier stage. Due to the technological development of ultrasound and the related high resolution and precision of imaging, ultrasound examination between 11 + 0–13 + 6 allows to suspect an increasing number of fetal defects [6–8]. We now estimate that the detection of abnormalities of the fetal anatomy in the first trimester is about 60% [9–11]. If early anatomical defects of the fetus are diagnosed, early prenatal invasive diagnostics can be offered to the pregnant woman to exclude the genetic disorders. The absolute prerequisite for reliable prenatal examination is to obtain ultrasound cross sections images in accordance with the standards and to obtain the best available images under given examination conditions. In connection with the introduction into clinical practice of cell-free fetal DNA in maternal blood (cffDNA) for screening for chromosome aberrations, in selected clinical situations it is recommended to suggest this diagnostic method to the pregnant woman. The evaluation of cell-free fetal DNA in maternal blood is recommended (only if there are no anatomical abnormalities in ultrasound examination) for pregnant women of the indirect risk group of trisomy 21, 18, 13 (1:300–1:1000) [12]. If an abnormal prenatal screening result, structural defect in the fetus or abnormal values of nuchal translucency (above 95th percentile) are found, the pregnant woman should be referred for further evaluation at the referral center with the genetic consultation [13]. Due to the increase in the number of Caesarean sections in Poland (42.2% according to the Euro-Peristat 2015 report), more frequent complications occur in subsequent pregnancies in the form of implantation of a pregnancy in a scar after Caesarean section and as a result of trophoblast growth [14–16].

Therefore, if the trophoblast is located on the anterior wall of the uterus, it is recommended to accurately assess the site of hysterotomy. In cases of doubts and suspicion of trophoblast growth in the scar after Caesarean section, the pregnant woman should be immediately referred to the reference center.

In other cases, at this stage of pregnancy we do not assess the location of the trophoblast, and it is particularly unjustified to make a diagnosis or suspicion of extremely low-lying trophoblast.

A detailed assessment of the structure of the fertilized egg includes the following elements (abdominal or transvaginal transducer):

- a) number of gestational sacs and fetuses in the uterine cavity
- b) fetal heart rate evaluation (FHR)  
Note: during normal pregnancy, the fetal heart rate decreases from about 170 beats per minute at 11 weeks of pregnancy to about 150 beats per minute at 14 weeks.
- c) biometrics

CRL — crown-rump length measurement — assessment/verification of gestational age when CRL < 84 mm. Note: every effort must be made to ensure that the CRL is measured reliably and precisely, because this is the basis for determining the age of the fetus and the date of delivery. CRL measurement should be taken when the fetus is in a neutral position and on its back, in the sagittal section. The value of 45 mm corresponds to 11 weeks + 0 days (according to some nomograms 11 weeks + 2 days) and 84 mm – 13 weeks + 6 days (14 + 1 respectively)

d) fetal anatomy assessment [18–21]

- skull — shape, cerebral falx, plexuses, proportions of the choroid plexuses and cerebrospinal fluid in the fetal skull
- facial skeleton — we recommend assessing the profile and presence of eyeballs if possible
- abdominal walls — umbilical cord insertion visibility position of the stomach - on the left under the diaphragm
- fetal heart — location, axis and heart rate; if possible, it is good clinical practice to visualize 4 cardiac chambers and a cross-section through the transverse part of the ductal and aortic arches (expected V sign) mapped with colored Doppler.
- bladder in the sagittal projection (in some normal pregnancies it may be difficult to see)
- upper and lower limbs — tri-segmental assessment
- assessment of the chorion, description of possible irregularities
- chorionicity assessment in multiple pregnancy (LAMBDA or T sign)

The second goal of ultrasound examination at 11 + 0 – 13 + 6 weeks of pregnancy is to assess the risk of the most common chromosome aberrations (trisomy 21, 18, 13) [1]. The risk calculation is based on the history, maternal age, assessment of ultrasound and biochemical markers and should be performed using FMF-certified calculators only.

We recommend providing two risk values: background, which takes into account the age of the pregnant woman and a final result which evaluates all used ultrasound markers and biochemical parameters. It is a mistake to provide the patient with two separate results: the first one based on ultrasound examination alone, and the second one based on the ultrasound and biochemical markers.

In case of blood sampling for biochemical test on the day of ultrasound, the patient should be given a preliminary result of the examination without the risk of genetic defects (evaluation of gestational age, evaluation of fetal anatomy).

The final result of the examination with the genetic risk assessment should only be given after the biochemical test result.

Ultrasound markers include the following basic markers [17]:

**a) FHR — Fetal Heart Rate**

**b) NT — Nuchal Translucency.**

Principles of assessing fetal NT according to FMF [18, 22]:

**a) Image magnification** — the head and 1/3 of the fetal chest occupy the entire screen.

**b) Neutral fetal head position** — no excessive bending in either direction of the fetal head.

**c) Fetus position** — fetal sagittal section.

Note: The sagittal section is obtained by showing the tip of the nose, nasal bone, nasal skin, hypoechogenic mesencephalon and a rectangular image of the fetal jaw.

**d) Amniotic membrane** — if it is visible, it must be distinguished from the skin of the fetus. Note: To obtain a contrasting NT and amniotic membrane image, reduce the gain to low values.

**e) NT measurement** — at the widest point, markers “inner to inner”, horizontal arms of markers placed on the NT limiting lines.

Note: If the umbilical cord runs around the neck of the fetus, it is recommended to first assess the anatomy of the fetus counting on the change of the fetus position. If this is not possible, it is possible to measure above and below the course of the umbilical cord and note the mean value, avoiding the use of such expressions as “umbilical cord around the neck” in the description.

The risk assessment of fetal chromosome aberrations should be performed between 11 + 0 – 13 + 6 (at 45–84 mm CRL). Mother’s age, history, NT and FHR in combination with biochemical markers (PAPP-A, free beta-hCG subunit) are components of the so-called combined test, also known as FTS (First Trimester Screening) [1, 22, 23]. Biochemical test which includes at least two of the above-mentioned elements is an indispensable element of a correct risk calculation.

A risk assessment without biochemical markers is an incorrect practice and such a result should be considered as incomplete.

It is not appropriate to replace a biochemical test with a free fetal DNA test, as biochemical markers are not only used to assess the risk of trisomy.

Biochemical tests of the first trimester should be performed only on FMF-certified machines (Delfia, Kryptor, Roche).

The optimal time to collect blood for biochemical tests in the first trimester is 10–11 weeks of pregnancy.

Evaluation of the blood sample should be performed no later than 13 + 6 weeks of pregnancy (CRL — 84 mm).

In the case of abnormal values of collected biochemical markers, they should not be re-tasted unless an error is suspected in the collection, storage or transport of the sample.

Evaluation of additional ultrasound markers of chromosome aberrations [23–25]:

- **NB — Nasal Bone**

- Note: we don’t measure nasal length in the first trimester of pregnancy. It is evaluated as: present, absent (hypoplastic) or not assessable (under difficult technical conditions).

- **DV PIV — Ductus Venosus, PIV)**

- **TR — Tricuspid Regurgitation**

Assessment of additional markers increases the Detection Rate (DR) for trisomy 21 chromosome to 95%, with False Positive Rate (FPR) at 2.5%.

A physician with appropriate audits and an FMF license to assess additional markers (NB, TR, DV PIV) and a Polish Society of Gynecologists and Obstetricians — Ultrasound Section certificate can use additional markers to calculate the risk of genetic defects.

Invasive diagnostics (chorionic biopsy, genetic amniocentesis) should be recommended for pregnant women, who after performing the combined test (pregnant woman’s age, FHR, NT, PAPP-A, free beta-hCG), have a risk of chromosome aberrations in the fetus  $\geq 1:300$ .

In the light of recent reports, the additional risk of pregnancy loss (adjusted for specific risk groups) and indications for amniocentesis) after the amniocentesis is about 0.1% [26].

During the first trimester of pregnancy, it is good clinical practice to try to exclude the occurrence of major ultrasound markers of chromosome abnormalities [27].

- hernia of the anterior abdominal wall (omphalocele)
- common atrioventricular canal,
- megacystis,
- congenital diaphragmatic hernia,
- holoprosencephaly,

If they are present, regardless of other markers, the risk of chromosome aberrations in the fetus increases and the pregnant woman should be referred to a referral center for further examination and invasive diagnostics.

A referral to an invasive procedure (chorionic biopsy, amniocentesis, cordocentesis) may be issued by an obstetrician-gynecologist or a perinatologist. Genetic consultation is not necessary to perform an invasive procedure (but it is recommended especially in the case of genetic disease family history).

Ultrasound examination between 11 + 0–13 + 6 also provides the possibility of achieving the third aim of calculating the risk of pre-eclampsia PE [28–30].

Specialists with appropriate FMF certification can perform an extended examination PE risk calculation based on patient history, arterial pressure (MAP), uterine arterial pulsation index (Ut PI), placental growth factor (PIGF) concentration in pregnant blood serum [31].

If PIGF measurement cannot be used, PAPP-A values below 0.4 MoM suggest an increased risk of pre-eclampsia.

The ASPRE study in pregnant women examined the risk of PE preeclampsia using the FMF algorithm between 11 + 0–13 + 6 weeks of pregnancy.

In the high-risk group  $> 1:100$  administration of acetylsalicylic acid (150 mg/day, from 11–14 weeks of pregnancy) reduced the incidence of PE  $< 37$  weeks by 62% ( $p = 0.004$ ) and PE  $< 34$  weeks by 82% [32].

If a high risk is identified (currently the most common cut-off points are  $> 1:100$  or  $> 1:150$ ), prophylaxis with 150 mg of acetylsalicylic acid (once a day before sleep) introduced after risk evaluation (week 11–14) and before 16 weeks of pregnancy and continued until 36 weeks is recommended [32].

Each result of the ultrasound examination performed in the first trimester of pregnancy should be completed with a commentary and possible recommendations for further treatment for the referring doctor and the Patient.

## ULTRASOUND EXAMINATION IN PREGNANCY WEEKS 18–22 AND 28–32 — FETAL DEVELOPMENT ASSESSMENT

The aim of an ultrasound examination in weeks 18–22 of pregnancy is a detailed assessment of the fetal organs in terms of congenital defects (assessment of the fetal anatomical structure). Weeks 28–32 examination entails first and foremost the assessment of fetal growth and possibly fetal wellbeing assessment in particular clinical situations. In addition, the examinations are to determine the approximate fetal weight and gestational age (in case the date of last menstrual period is not known and/or no ultrasound was performed in the first trimester of pregnancy), based on biometric parameters. It is worth noting that both the multitude and individual variability of parameters (BPD, HC, AC, FL, HL, TCD) on the basis of which the gestational age can be determined, causes that the accuracy of this method, during this period of pregnancy, may be incorrect. In the first half of the second trimester (14–20 weeks), on the basis of the measurement of HC and the cerebellar transverse dimension, the gestational age can be estimated with an accuracy of  $\pm 7$ ,  $\pm 10$  days. In the third trimester of pregnancy, the average spread of the estimated gestational age (multiparameter evaluation) is  $\pm 3$  weeks — in such situations HC or TCD is recommended to be used for the evaluation of the progress of pregnancy in the third trimester.

It should also be added that if the gestational age had previously been defined based on the CRL in the first trimester of pregnancy, no correction should be made for that age based on biometric measurements carried out in the second and third trimesters of pregnancy to adjust the date of birth.

### 1. Biometry, determination of estimated fetal weight and gestational age

measurement based on biometric parameters:

**BPD** – Bi-Parietal Diameter,  
**HC** – Head Circumference,

**AC** – Abdominal Circumference,  
**FL** – Femur Length,  
optionally **HL** – Humerus Length  
and **TCD** — Transverse Cerebellar Diameter [1, 33].

**Bi-parietal diameter (BPD)** — the transthalamic plane (recommended)

- cross-section at the height of the thalami,
- insonation angle  $90^\circ$ ,
- symmetric hemispheres and calvaria, the cerebellar hemispheres should not be in the plane of the image
- midline falx with the cavum septi pellucidi.

Note: The calipers should be set according to the reference method used (usually “outer to inner” edge if the calvaria wall). In the transventricular plane, it is recommended to measure the width of the brain's lateral ventricles.

Brain structures visible in particular planes:

Transthalamic plane: anterior horns of the lateral ventricles, CSP, thalami, hippocampus

Transventricular: parallel to the plane described above, anterior and posterior horns of the lateral ventricles, CSP.

Transcerebellar: anterior horns of the lateral ventricles, cavum septum pellucidum (CPS), thalami, cerebellum, cisterna magna.

**Fetal head circumference (HC)** — measurement plane analogous to BPD measurement.

Note: use an ellipse, covering the outer outline of the fetal skull.

**Abdominal circumference (AC)** — measurement plane:

- cross section in the transverse plane,
- umbilical vein at the hepatic sinus level,
- visible gastric bubble, invisible kidneys.

Note: Use an ellipse, covering the external contour of the fetal abdomen.

**Femur length (FL)** — measurement plane:

- Measurement in the longest axis,
- Insonation angle  $45\text{--}90^\circ$ .

Note: The markers should be placed on the farthest ends of the bone, excluding cartilage if visible.

**Fetal humerus length (HL)** — measurement plane:

- measurement in the longest axis,
- Insonation angle  $45\text{--}90^\circ$ .

Note: The markers should be placed at the farthest ends of the bone, not including cartilage if visible

### 2. Evaluation of fetal structures and organs — evaluation of fetal anatomy [1, 33–35]

Table I presents the recommended minimum values of fetal anatomy during ultrasound examination between 18–22 weeks of pregnancy.

**a) Skull** — evaluation of 4 features:

- Size** — assessment when measuring BPD, HC.

**Table 1. Recommended evaluation of the fetus in the second trimester of pregnancy (18–22 weeks of pregnancy)**

Head	Skull continuity Cavum septi pellucidi Cerebral falx Thalami Lateral ventricles Cerebellum Cisterna magna	Abdomen	Stomach in the correct position Bowels not expanded Both kidneys present Umbilical cord insertion Bladder
Face	Eyeballs, Face profile Mouth, upper lip alveolar process of the jaw	Skeleton	Spine - no defects (axial, sagittal and coronal plane) Upper and lower limbs — tri-segmental
Neck	Lack of tumors (cystic hygroma, neck teratoma)	Placenta	Position Possible abnormalities
Chest/Heart	Shape of the chest Size, position and axis of the heart Heart rate, 4 chamber view Outflow track from the heart ventricles 3-vessel view 3-vessel-trachea view	Umbilical cord	Number of vessels, insertion
		Gender	Female of male*

\*optional, depending on examination conditions and patient's wish

**Table 2. Recommended range of fetal heart rate screening [1]****Minimum evaluation parameters have been bolded**

FETAL HEART SCREENING performed by an obstetrician-gynecologist

- **Determination of the sides of the fetus based on its position in the uterus**
- **Visualization of the stomach**
- Visualization of the aorta descending to the front and left of the fetal spine
- Visualization of the inferior vena cava forward of the aorta and to the right of the fetal spine
- **Visibility of the heart in the chest**
- **Heart size - the area of the heart is about 1/3 of the chest area**
- **Visualization of the heart on the left side of the chest**
- **Determination of heart axis** —  $45^\circ \pm 20^\circ$
- No pericardial fluid
- **Assessment of the heart rate** — preferably in the left ventricle in a four-chamber projection at the ventricular septum at the border of inflow and outflow, which gives the possibility to additionally determine if there is no atrial to ventricular impulse conduction disturbance - (normal sinus rhythm 110–160 beats/min)
- **Visualization of the 4 cardiac chambers (4CHV) with a cross of the heart**
- **Visualization of 3 vessels in the upper mediastinum (3V)** — **pulmonary trunk, aorta, upper vena cava**
- Visualization of 3 vessels and trachea in the upper mediastinum (3VT) — trachea to the right of the aortic arch and ductal arch
- **Visualization of the outflow tracts from the chambers:**
- LVOT — the left ventricular outflow tract is not divided, septal-vascular continuity is maintained
- RVOT — the right ventricular outflow tract is divided into branches: right and left pulmonary artery and ductus arteriosus
- **Visualization of the crossing of Ao and PA after leaving the respective chambers**

4CHV (4 Chamber View), 3VV (3 Vessel View), 3VTV (3-Vessel-Trachea View), LVOT (Left Ventricle Outflow Tract), RVOT (Right Ventricle Outflow Tract)

- **Shape** — oval, no loss of continuity - except for cranial sutures. Abnormal shape (lemon, strawberry, clover leaves) should be documented.
  - **Continuity** — no bone defects, no external visible brain structures.
  - **Echogenicity** — homogeneous, only cavities at the cranial sutures. The "excessively" visible brain structures of a fetus may show defects in bone mineralization (e.g. hypophosphatasia, osteogenesis imperfecta), similarly to the susceptibility of the skull to transducer compression through maternal abdominal walls [36].
- b) Fetal central nervous system** — assessment in at least three planes allowing for visualization of the CNS — transventricular, transthalamic and transcerebellar (posterior fossa).  
The following should be visualized: lateral ventricles with choroid plexuses, cavum septum pellucidum, cerebral falx, thalami, cerebellum and cistern magna. The posterior horn of the lateral ventricle should be measured.
- c) Fetal face** — the assessment should include the evaluation of the upper lip (assessment of the presence of cleft), alveolar process of the jaw, eyeballs, face profile, visibility and measurement of nasal bone.
- d) Fetal neck** — assessment of the presence of possible tumors. The assessment includes examination for lesions such as the cystic hygroma or teratoma in this area and measurement of NF — Nuchal Fold in 18–22 weeks of pregnancy.



- e) **Fetal chest** — regular shape, without deformities, both lungs of homogeneous echogenicity, without pathological masses, fluid reservoirs and mediastinal displacement. Hypoechoic diaphragm line visible on the sagittal section.
- f) **Fetal heart** — it is recommended that the fetal heart image is magnified so it occupies 1/3 of the image.
- g) **Fetal abdomen** — the position of internal organs in relation to the heart apex should be assessed:
- **Fetal stomach** on the left side, position and shape abnormalities (e.g. double bubble image) should be documented.
  - **Bowels** should be located in the abdomen. Signs of bowel loop dilatation should be documented.
  - **Cord insertion** should form a picture of the letter T with the abdominal wall. The cord insertion should be examined for any disturbances in the anterior abdominal wall (umbilical hernia, gastroschisis). The number of vessels in the umbilical cord should be determined, preferably by doppler ultrasonography, showing the course of the umbilical arteries along the fetal urinary bladder or on the transverse section. The presence of a **single umbilical artery** should be an indication for a thorough reassessment of the fetal anatomy or further diagnosis at the referral center.
  - **Fetal gallbladder** is not part of a routine evaluation in the 2<sup>nd</sup> and 3<sup>rd</sup> trimester
  - **Both kidneys** should be visualized, the expansion of the pelvicalyceal system should be documented (measurement of AP or PA on the transverse section). The measurement of the renal pelvis should be performed on the transversal section of the fetal abdomen at the height of the fetal kidneys with the fetal spine at 6 or 12 o'clock. A measurement above 7 mm should be considered as an indication for verification at the referral center.
  - **Fetal urinary bladder** should be visualized, magnification and abnormal shape should be documented (e.g. "keyhole" image — posterior urethral valve).
  - **Fetal spine** — assessment in the sagittal, axial and coronal planes with assessment of skin continuity. Spina bifida is often accompanied by changes in the fetal CNS anatomy (cerebellum — banana sign, collapsed cisterna magna). Other measurement planes may be helpful in detecting deformations e.g. of the vertebrae or sacral agenesis.
- h) **Fetal limbs** — minimum evaluation involves three-segmental view of the fetal limbs. It is not recommended to count fingers and toes.
- i) **Placenta evaluation** — the minimum evaluation includes determining the position of the placenta and

the relation to the cervical internal os in the sagittal projection. Abnormalities in the placenta structure — hematomas, tumors and other pathological masses should be documented. Pregnant women after uterine procedures or with a low-lying placenta should be referred for a follow-up placenta accreta examination. In cases of doubts, the placenta should be reassessed, or the patient should be referred to a higher reference center to evaluate for PAS (placenta accreta spectrum) — the currently recommended term for placental accreta/increta/percreta.

- j) **Examination of the cervix, uterus, uterine appendages** — During the second trimester ultrasound examination it is possible to assess the risk of preterm birth by measuring the length of the cervical canal.
- k) In case the so-called "amniotic sludge" is found, this fact should be recorded in the result of the examination. Any abnormal masses within the cervix or adnexa should be documented if they may constitute an obstacle to delivery.
- l) **Evaluation of amniotic fluid** — may be performed subjectively or using semi-quantitative indicators (AFI, MVP, DP). Pregnant women with abnormal amounts of amniotic fluid should receive a detailed fetal evaluation at a reference center.
- m) **Fetal gender evaluation** — may be performed upon request and after the parents' consent. If there are any changes of the nature of e.g. testicular hygroma, ovarian cyst or clitoral hypertrophy, this should be included in the test description.
- n) In the 3<sup>rd</sup> trimester examination during pregnancy, the assessment of blood flow in the umbilical artery, middle cerebral artery or uterine arteries is not routinely performed. However, it may be performed if the examining physician, who is qualified to do so, considers this examination to be clinically justified and is able to interpret the results.

## V. FETAL ULTRASOUND EXAMINATION AFTER DELIVERY DATE

After 280 days of pregnancy, the risk of intrauterine fetal death is greater, especially in cases of fetuses with previously undiagnosed growth restriction (SGA) [37]. According to the current recommendations, after delivery date, each patient should have an ultrasound examination, which primary goal is [38]:

1. Evaluation of the fetal position and presentation,
2. Evaluation of fetal heart activity and beats per minute,
3. Biometry and determination of the estimated fetal weight — if the stage of delivery makes it possible and since the last evaluation was more than 7 days ago. Measurement based on the following biometric

Table 3. Ultrasound examination report form in 18–22 and 28–32 weeks of pregnancy								
			FETAL ANATOMY EVALUATION	normal	abnormal	not visualized		
First name, Surname:..... Date of birth:..... PESEL (Personal Identification Number) ..... LMP/gestational age based on LMP..... Date of examination:..... Machine..... Transducer..... Referring physician..... Examining physician.....			<b>HEAD</b>					
			Shape					
			Cavum septi pellucidi					
			Midline falx					
			Thalami					
			Lateral ventricles, Vp standard up to 10 mm					
			Cerebellum					
			Cisterna magna – standard 2–10 mm					
			<b>FACE</b>					
			Orbits					
			Face profile					
			Nasal bone, NB...(mm)					
			Upper lip and lower lip					
			<b>FETAL BIOMETRY</b>					
Parameter	mm	week	Alveolar process of the jaw					
BPD			NECK, NF standard up to 6 mm					
HC			<b>HEART</b>					
AC			Heart activity	.....ud/min				
FL			Axis					
HL			Size					
TCD			4-chamber view					
Fetal weight (g)			3-vessel-trachea view					
PLACENTA: Position (wall)..... Distance from os (mm).....			Left ventricular outflow					
			Right ventricular outflow					
AMNIOTIC FLUID (volume) <input type="checkbox"/> normal <input type="checkbox"/> abnormal AFI (cm)..... MVP (cm).....			<b>ABDOMEN</b>					
			Stomach					
			Bowels					
FETAL MOVEMENTS <input type="checkbox"/> normal <input type="checkbox"/> absent			Kidneys					
			Urinary bladder					
			Abdominal cord insertion					
FETAL LIE <input type="checkbox"/> longitudinal <input type="checkbox"/> cephalic <input type="checkbox"/> breech <input type="checkbox"/> transverse <input type="checkbox"/> oblique			Number of cord vessels	<input type="checkbox"/> 2	<input type="checkbox"/> 3			
			<b>SKELETON</b>					
			<b>LIMBS</b>					
			Left upper limb					
			Right upper limb					
Left lower limb								
Right lower limb								
COMMENT:			GENDER (optional)	<input type="checkbox"/> M	<input type="checkbox"/> Ż			
			<b>RECOMMENDATIONS:</b>					
CONCLUSIONS: <input type="checkbox"/> normal and complete exam result <input type="checkbox"/> normal but incomplete exam result								

parameters: BPD — Bi-Parietal Diameter, HC — Head Circumference, AC — Abdominal Circumference, and FL — Femur Length using the Hadlock equations to estimate fetal weight,

4. Assessment of the volume of amniotic fluid (AFI or MVP),
5. Assessment of the position of the placenta and its relation to the internal cervical os,
6. In justified cases — further evaluation including the fetal biophysical profile (BPS, Manning test) and/or umbilical arterial Doppler and middle cerebral artery Doppler with qualitative assessment of the flow spectrum and semi-quantitative assessment, including determination of the PI - Pulsatility Index, with reference to reference values.

It should be emphasized that the ultrasound examination after the expected delivery date carries the highest risk of error. In the case of finding fetal presentation other than cephalic, too low or too high fetal weight, or reduced volume of amniotic fluid, it is necessary to refer the patient to an obstetric-gynecological hospital to plan the delivery.

## ULTRASOUND EXAMINATION OF MULTIFETAL PREGNANCY

Multiple pregnancy cannot be considered a physiological pregnancy and is associated with an increased risk of premature delivery, pre-eclampsia, complications related to fetal growth and death. For this reason, obstetric care for this type of pregnancy is usually provided in referral centers.

This type of pregnancy is diagnosed by ultrasound examination performed in the first trimester. During the examination, chorionicity and amnionicity (number of chorions and amnions) are determined. Assessment of chorionicity from the ultrasound examination shall be documented by a sonographic image

If the pregnant woman reports after the 14th week of pregnancy or if chorionicity cannot be determined and both fetuses are of the same sex, it should be treated as a monochorionic twin pregnancy.

The rules of ultrasound examination in a patient with a dichorionic twin pregnancy:

1. The diagnosis of a dichorionic pregnancy by ultrasound in the first trimester of pregnancy is based on the following findings: two separate sacs with embryos and a lambda sign;
2. ultrasound examination in multiple pregnancies should be performed:
  - a) in the first trimester of pregnancy (11–13 weeks + 6 days) — with an assessment of the risk of genetic defects for each fetus separately,
  - b) in the second trimester of pregnancy (18–22 weeks) — with evaluation of the anatomy of each fetus and with transvaginal measurement of the cervical length

- c) in the third trimester of pregnancy examination should be performed in weeks 28, 32, 36 — to assess the growth of the fetuses (if a mass discrepancy is greater than or equal to 25% is found, the patient should be referred for care to a third degree perinatal care center),

- d) before delivery — to determine fetal presentation;

The rules of ultrasound examination in a patient with a monochorionic twin pregnancy:

Due to the frequent occurrence of specific complications associated with fetal growth and the risk of fetal intrauterine death, the care of monochorionic twins must be performed at a third-degree level of perinatal care. In addition to ultrasound examinations, fetal echocardiography should always be ordered in this type of pregnancy.

1. care of a patient with monochorionic diamniotic pregnancy:

- a) The diagnosis of a monochorionic diamniotic pregnancy results from an ultrasound examination in the first trimester finding a single gestational sac with two embryos and two amniotic sacs, with the insertion of the amniotic membrane separating the embryos to the chorion having the shape of the letter "T",

- b) ultrasound examination in a monochorionic diamniotic pregnancy should be performed: — in the first trimester of pregnancy (11–13 weeks + 6 days) — with an evaluation of the risk of genetic defects (the same for both fetuses) and fetal biometry,

- c) from week 16 of pregnancy, every 2 weeks for the detection of TTTS or sIUGR, taking into account assessment of: fetal biometry, volume of amniotic fluid in both sacs, symptom of free-floating intertwin membrane, filling of both fetal urinary bladders and vascular flows by Doppler (umbilical arteries, middle cerebral arteries, venous ducts).

In the case of complications, the frequency and scope of ultrasound examinations should be decided individually.

- d) before delivery — to determine the biometrics and presentation of the fetuses;

2. care of a patient with monochorionic-monoamniotic twin pregnancy:

- a) the diagnosis of a monochorionic-monoamniotic pregnancy is based on the finding of a single gestational sac with two closely spaced embryos and no embryo separating membrane in the first trimester of pregnancy; the absence of the separating membrane should be confirmed in subsequent ultrasound examinations; it is also important to exclude the presence of conjoined twins,

- b) ultrasound examinations in a monochorionic-monoamniotic pregnancy shall be performed: — in the

- first trimester of pregnancy (11–13 weeks + 6 days), with an assessment of the risk of genetic abnormalities (the same for both fetuses), exclusion of conjoined twins and an assessment of cords insertion,
- c) from the 16<sup>th</sup> week of pregnancy — every 2 weeks with the assessment of fetal growth and vascular flows by Doppler evaluation (umbilical arteries, middle cerebral arteries, venous ducts).
  - d) in the second trimester of pregnancy (18–22 weeks) — with evaluation of the anatomy of each fetus and transvaginal measurement of the cervical length,
  - e) in hospital conditions from the 26<sup>th</sup> week — with an assessment of the fetal hemodynamics: Doppler examination of vascular flows (umbilical arteries, middle cerebral arteries, venous ducts) — should be performed at least twice a week.

## CONCLUSIONS

For the safety and the highest quality of services provided, the ultrasound examination should be performed by an individual with appropriate qualifications, confirmed by appropriate documents issued by national and international organizations and subjecting their results to periodic control and audit.

At the time of this update, the documents confirming the above skills and qualifications are:

1. documents confirming the specialization in obstetrics and gynecology,
2. certificates issued by the Ultrasound Section of the Polish Society of Gynecologists and Obstetricians
  - Basic certificate of the Ultrasound Section of the Polish Society of Gynecologists and Obstetricians,
  - Certificate of Prenatal Screening of the Ultrasound Section of the Polish Society of Gynecologists and Obstetricians,
  - Certificate of Fetal Heart Examination of the Ultrasound Section of the Polish Society of Gynecologists and Obstetricians,
3. Certificates issued by international organizations, *i.e.*:
  - FMF certificate of competence in measurement of nuchal translucency (NT),
  - FMF certificates in other ultrasound markers (NB, TR and DV and uterine artery),
  - Diploma in Fetal Medicine — issued by FMF.

Since 2012, the Ultrasound Section of the Polish Society of Gynecologists and Obstetricians has been conducting courses and workshops, as well as theoretical and practical exams in order to select specialists in prenatal diagnosis and fetal echocardiography.

The Ultrasound Section of the Polish Society of Gynecologists and Obstetricians additionally recommends:

1. Conducting the examination in conditions that allow to the sonographer to concentrate (limited of the number of people present at the study, keeping silence in the office).
2. The presence of children in the examination room during examination is not recommended

The rules described above also apply to the performance of ultrasound examinations according to the recommendations of the Polish Society of Gynecologists and Obstetricians in the period between 11–14 weeks of pregnancy, 18–22 weeks of pregnancy, 27–32 weeks of pregnancy, and immediately after week 40 referred to in the Annex to the Regulation of the Minister of Health of 16 August 2018 (item 1756): Organisational Standard of Health Care for Entities Providing Perinatal Care Services [39].

The guidelines are accompanied by a guide containing images showing the normal scans obtained during ultrasound examination.

## REFERENCES

1. Pietryga M, Borowski D, Brązert J, et al. Polskie Towarzystwo Ginekologiczne. Polish Gynecological Society—Ultrasound Section Guidelines on ultrasound screening in uncomplicated pregnancy-2015. *Ginekol Pol.* 2015; 86(7): 551–559, indexed in Pubmed: 26376536.
2. Abramowicz J. Benefits and risks of ultrasound in pregnancy. *Semin Perinatol.* 2013; 37(5): 295–300, doi: 10.1053/j.semperi.2013.06.004.
3. Stirnemann JJ, Chalouhi GE, Forner S, et al. First-trimester uterine scar assessment by transvaginal ultrasound. *Am J Obstet Gynecol.* 2011; 205(6): 551.e1–551.e6, doi: 10.1016/j.ajog.2011.06.104, indexed in Pubmed: 21893310.
4. Naji O, Wynants L, Smith A, et al. Predicting successful vaginal birth after Cesarean section using a model based on Cesarean scar features examined by transvaginal sonography. *Ultrasound Obstet Gynecol.* 2013; 41(6): 672–678, doi: 10.1002/uog.12423, indexed in Pubmed: 23371440.
5. Jachymski T, Moczulska H, Guzowski G, et al. Conservative treatment of abnormally located intrauterine pregnancies (cervical and cesarean scar pregnancies): a multicenter analysis (Polish series). *J Matern Fetal Neonatal Med.* 2018; 33(6): 993–998, doi: 10.1080/14767058.2018.1514009.
6. Timor-Tritsch IE, Fuchs KM, Monteagudo A, et al. Performing a fetal anatomy scan at the time of first-trimester screening. *Obstet Gynecol.* 2009; 113(2 Pt 1): 402–407, doi: 10.1097/AOG.0b013e3181954b23, indexed in Pubmed: 19155913.
7. Abu-Rustum RS, Daou L, Abu-Rustum SE. Role of first-trimester sonography in the diagnosis of aneuploidy and structural fetal anomalies. *J Ultrasound Med.* 2010; 29(10): 1445–1452, doi: 10.7863/jum.2010.29.10.1445, indexed in Pubmed: 20876898.
8. Timor-Tritsch IE, Bashiri A, Monteagudo A, et al. Qualified and trained sonographers in the US can perform early fetal anatomy scans between 11 and 14 weeks. *Am J Obstet Gynecol.* 2004; 191(4): 1247–1252, doi: 10.1016/j.ajog.2004.03.007, indexed in Pubmed: 15507948.
9. Syngelaki A, Chelemen T, Dagklis T, et al. Challenges in the diagnosis of fetal non-chromosomal abnormalities at 11-13 weeks. *Prenat Diagn.* 2011; 31(1): 90–102, doi: 10.1002/pd.2642, indexed in Pubmed: 21210483.
10. Syngelaki A, Hammami A, Bower S, et al. Diagnosis of fetal non-chromosomal abnormalities on routine ultrasound examination at 11-13 weeks' gestation. *Ultrasound Obstet Gynecol.* 2019; 54(4): 468–476, doi: 10.1002/uog.20844, indexed in Pubmed: 31408229.
11. Karim JN, Roberts NW, Salomon LJ, et al. Systematic review of first-trimester ultrasound screening for detection of fetal structural anomalies and factors that affect screening performance. *Ultrasound Obstet Gynecol.* 2017; 50(4): 429–441, doi: 10.1002/uog.17246, indexed in Pubmed: 27546497.
12. Rekomendacje Zespołu Ekspertów Polskiego Towarzystwa Ginekologicznego oraz Polskiego Towarzystwa Genetyki Człowieka w zakresie

- przesiewowego badania genetycznego wykonywanego na wolnym płodowym DNA. *Ginekol Pol.* 2015; 86: 966–969.
13. Bardi F, et al. Is there still a role for nuchal translucency measurement in the changing paradigm of first trimester screening? *Prenatal Diagnosis.* ; 2019: 1–9.
  14. Stirnemann JJ, Chalouhi GE, Forner S, et al. First-trimester uterine scar assessment by transvaginal ultrasound. *Am J Obstet Gynecol.* 2011; 205(6): 551.e1–551.e6, doi: 10.1016/j.ajog.2011.06.104, indexed in Pubmed: 21893310.
  15. Naji O, Wynants L, Smith A, et al. Predicting successful vaginal birth after Cesarean section using a model based on Cesarean scar features examined by transvaginal sonography. *Ultrasound Obstet Gynecol.* 2013; 41(6): 672–678, doi: 10.1002/uog.12423, indexed in Pubmed: 23371440.
  16. Stirnemann J, Mousty E, Chalouhi G, et al. Screening for placenta accreta at 11–14 weeks of gestation. *Am J Obstet Gynecol.* 2011; 205(6): 547.e1–547.e6, doi: 10.1016/j.ajog.2011.07.021.
  17. Nicolaides K. Screening for fetal aneuploidies at 11 to 13 weeks. *Prenat Diagn.* 2011; 31(1): 7–15, doi: 10.1002/pd.2637.
  18. Chaoui R, Benoit B, Mitkowska-Wozniak H, et al. Assessment of intracranial translucency (IT) in the detection of spina bifida at the 11–13-week scan. *Ultrasound Obstet Gynecol.* 2009; 34(3): 249–252, doi: 10.1002/uog.7329, indexed in Pubmed: 19705402.
  19. Lachmann R, Chaoui R, Moratalla J, et al. Posterior brain in fetuses with open spina bifida at 11 to 13 weeks. *Prenat Diagn.* 2011; 31(1): 103–106, doi: 10.1002/pd.2632, indexed in Pubmed: 21188735.
  20. Ushakov F, Sacco A, Andreeva E, et al. Crash sign: new first-trimester sonographic marker of spina bifida. *Ultrasound Obstet Gynecol.* 2019; 54(6): 740–745, doi: 10.1002/uog.20285, indexed in Pubmed: 30977215.
  21. Salomon LJ, Alfirevic Z, Bilardo CM, et al. ISUOG practice guidelines: performance of first-trimester fetal ultrasound scan. *Ultrasound Obstet Gynecol.* 2013; 41(1): 102–113, doi: 10.1002/uog.12342, indexed in Pubmed: 23280739.
  22. Kagan KO, Cicero S, Staboulidou I, et al. Fetal nasal bone in screening for trisomies 21, 18 and 13 and Turner syndrome at 11–13 weeks of gestation. *Ultrasound Obstet Gynecol.* 2009; 33(3): 259–264, doi: 10.1002/uog.6318, indexed in Pubmed: 19248005.
  23. Maiz N, Wright D, Ferreira AF, et al. A mixture model of ductus venosus pulsatility index in screening for aneuploidies at 11–13 weeks' gestation. *Fetal Diagn Ther.* 2012; 31(4): 221–229, doi: 10.1159/000337322, indexed in Pubmed: 22614037.
  24. Maiz N, Valencia C, Kagan KO, et al. Ductus venosus Doppler in screening for trisomies 21, 18 and 13 and Turner syndrome at 11–13 weeks of gestation. *Ultrasound Obstet Gynecol.* 2009; 33(5): 512–517, doi: 10.1002/uog.6330, indexed in Pubmed: 19338027.
  25. Kagan KO, Wright D, Valencia C, et al. Screening for trisomies 21, 18 and 13 by maternal age, fetal nuchal translucency, fetal heart rate, free beta-hCG and pregnancy-associated plasma protein-A. *Hum Reprod.* 2008; 23(9): 1968–1975, doi: 10.1093/humrep/den224, indexed in Pubmed: 18544579.
  26. Salomon LJ, Sotiriadis A, Wulff CB, et al. Risk of miscarriage following amniocentesis or chorionic villus sampling: systematic review of literature and updated meta-analysis. *Ultrasound Obstet Gynecol.* 2019; 54(4): 442–451, doi: 10.1002/uog.20353, indexed in Pubmed: 31124209.
  27. Kagan KO, Staboulidou I, Syngelaki A, et al. The 11–13-week scan: diagnosis and outcome of holoprosencephaly, exomphalos and megacystis. *Ultrasound Obstet Gynecol.* 2010; 36(1): 10–14, doi: 10.1002/uog.7646, indexed in Pubmed: 20564304.
  28. Sotiriadis A, Hernandez-Andrade E, Costa Fd, et al. ISUOG Practice Guidelines: role of ultrasound in screening for and follow-up of pre-eclampsia. *Ultrasound Obstet Gynecol.* 2018; 53(1): 7–22, doi: 10.1002/uog.20105.
  29. Poon LC, Shennan A, Hyett JA, et al. The International Federation of Gynecology and Obstetrics (FIGO) initiative on pre-eclampsia: A pragmatic guide for first-trimester screening and prevention. *Int J Gynaecol Obstet.* 2019; 145 Suppl 1: 1–33, doi: 10.1002/ijgo.12802, indexed in Pubmed: 31111484.
  30. Tan MY, Wright D, Syngelaki A, et al. Comparison of diagnostic accuracy of early screening for pre-eclampsia by NICE guidelines and a method combining maternal factors and biomarkers: results of SPREE. *Ultrasound Obstet Gynecol.* 2018; 51(6): 743–750, doi: 10.1002/uog.19039, indexed in Pubmed: 29536574.
  31. Rolnik DL, Wright D, Poon LC, et al. Aspirin versus Placebo in Pregnancies at High Risk for Preterm Preeclampsia. *N Engl J Med.* 2017; 377(7): 613–622, doi: 10.1056/NEJMoa1704559, indexed in Pubmed: 28657417.
  32. Prejbisz A, Dobrowolski P, Kosiński P, et al. Management of hypertension in pregnancy: prevention, diagnosis, treatment and longterm prognosis. *Kardiologia i Pol.* 2019; 77(7–8): 757–806, doi: 10.33963/KP.14904, indexed in Pubmed: 31322138.
  33. Pietryga M, Brązert J. Podstawy praktycznej ultrasonografii w ginekologii i położnictwie. Exemplum, Poznań 2009.
  34. Carvalho JS, Allan LD, Chaoui R, et al. ISUOG Practice Guidelines (updated): sonographic screening examination of the fetal heart. *Ultrasound Obstet Gynecol.* 2013; 41(3): 348–359, doi: 10.1002/uog.12403, indexed in Pubmed: 23460196.
  35. Salomon LJ, Alfirevic Z, Berghella V, et al. Practice guidelines for performance of the routine mid-trimester fetal ultrasound scan. *Ultrasound Obstet Gynecol.* 2011; 37(1): 116–126, doi: 10.1002/uog.8831.
  36. ACR–ACOG–AIUM practice guideline for the performance of obstetrical ultrasound. Brown BS. The prenatal ultrasonographic diagnosis of osteogenesis imperfecta lethalis. *J Can Assoc Radiol.* 1984, 35, 63–66. <http://www.acr.org/guidelines>.
  37. Divon MY, Haglund B, Nisell H, et al. Fetal and neonatal mortality in the postterm pregnancy: the impact of gestational age and fetal growth restriction. *Am J Obstet Gynecol.* 1998; 178(4): 726–731, doi: 10.1016/s0002-9378(98)70482-x, indexed in Pubmed: 9579434.
  38. Lindqvist PG, Pettersson K, Morén A, et al. Routine ultrasound examination at 41 weeks of gestation and risk of post-term severe adverse fetal outcome: a retrospective evaluation of two units, within the same hospital, with different guidelines. *BJOG.* 2014; 121(9): 1108–15; discussion 1116, doi: 10.1111/1471-0528.12654, indexed in Pubmed: 24593288.
  39. Rozporządzenie Ministra Zdrowia z dnia 16 sierpnia 2018 r.w sprawie standardu organizacyjnego opieki okołoporodowej, Dziennik Ustaw Rzeczypospolitej Polskiej, Warszawa, dnia 11 września 2018 r. Poz. 1756.

# NOWOŚCI W LECZENIU NOWOTWORÓW GINEKOLOGICZNYCH

18–20 LISTOPADA 2020 ROKU



VIRTUAL MEETING



Przewodniczący Komitetu Naukowego:  
prof. dr hab. n. med. Maciej Krzakowski  
dr hab. n. med. Radosław Mądry



**WWW.GINONKO.VIAMEDICA.PL**



**ginonko@viamedica.pl**



**58 320 94 94**



PATRONAT

ORGANIZATOR

PATRONAT MEDIALNY

PARTNER



Polskie Towarzystwo  
Onkologii Klinicznej




Onkoedu  
Serwis dla lekarzy specjalistów

tvmed



Virtual Meeting jest skierowany tylko do osób uprawnionych do wystawiania recept lub osób prowadzących obrót produktami leczniczymi — podstawa prawna: Ustawa z dnia 6 września 2001 r. Prawo farmaceutyczne (t. j. Dz.U. z 2019 r. poz. 499).

# PERINATOLOGIA I GINEKOLOGIA PRZEDŚWIĄTECZNIE



**Warszawa**

11–12 grudnia 2020 roku

**Przewodniczący Komitetu Naukowego:**  
prof. dr hab. n. med. Mirosław Wielgoś



Szczegółowe informacje oraz rejestracja na stronie internetowej

**[www.ginekologia.viamedica.pl](http://www.ginekologia.viamedica.pl)**

ORGANIZATOR



Konferencja jest skierowana do wszystkich osób zainteresowanych tematyką. Sesje satelitarne firm farmaceutycznych, sesje firm farmaceutycznych oraz wystawy firm farmaceutycznych są skierowane tylko do osób uprawnionych do wystawiania recept lub osób prowadzących obrót produktami leczniczymi — podstawa prawna: Ustawaz dnia 6 września 2001 r. Prawo farmaceutyczne (Dz. U. z 2017 r. poz. 2211, z późn. zm.)



19-0431.001.011

# Doroczna Wrocławska Konferencja Ginekologów i Położników



VIRTUAL MEETING



## 2 października 2020 roku

Przewodniczący Komitetu Naukowego:  
prof. dr hab. n. med. Mariusz Zimmer

ORGANIZATOR



PATRONAT MEDIALNY

tvmed

Szczegółowe informacje oraz rejestracja:

[www.dorocznawroclawska.viamedica.pl](http://www.dorocznawroclawska.viamedica.pl)

PARTNER



Konferencja jest skierowana do wszystkich osób zainteresowanych tematyką. Sesje satelitarne firm farmaceutycznych, sesje firm farmaceutycznych oraz wystawy firm farmaceutycznych są skierowane tylko do osób uprawnionych do wystawiania recept lub osób prowadzących obrót produktami leczniczymi — podstawa prawna: Ustawa z dnia 6 września 2001 r. Prawo farmaceutyczne (Dz. U. z 2017 r. poz. 2211, z późn. zm.)



19-0170.001.011