



OFFICIAL JOURNAL OF THE POLISH SOCIETY OF CLINICAL ONCOLOGY



Oncology

IN CLINICAL PRACTICE

2020, Vol. 16, Number 1

ISSN 2450-1654



*Beata Jagielska, Elżbieta Sarnowska, Tomasz Sarnowski,
Katarzyna Śmiałek-Kania, Janusz Siedlecki, Andrzej Kawecki*
**Contemporary diagnostic and therapeutic possibilities
in patients with adenoid cystic carcinoma of the head
and neck**

Łukasz Kwinta

**Febrile neutropenia prophylaxis with short- and long-acting
granulocyte colony-stimulating factors during treatment
of solid tumours**

Bartłomiej Żerek, Wojciech Straś, Piotr Różga, Elżbieta Pękała
**The evolution of biologics in the context of oncological
therapy**

*Aleksandra Sobiborowicz, Anna M Czarnecka,
Anna Szumera-Ciećkiewicz, Piotr Rutkowski, Tomasz Świtaj*
Diagnosis and treatment of malignant PEComa tumours

*Monika Misztal, Magdalena Krakowska, Monika Ryś-Bednarska,
Mariusz Śliwa, Piotr Potemski*
**Symptoms of nervous system damage in a patient
undergoing anti-PD1 immunotherapy**

Róża Poźniak-Balicka, Dawid Murawa
**Breast implant-associated anaplastic large cell lymphoma
(BIA-ALCL)**

ONCOLOGY IN CLINICAL PRACTICE

Official Journal of the Polish Society of Clinical Oncology

https://journals.viamedica.pl/oncology_in_clinical_practice

Editor-in-Chief

prof. dr hab. med. Maciej Krzakowski

Deputy Editors

prof. dr hab. med. Andrzej Kawecki
prof. dr hab. med. Piotr Potemski
prof. dr hab. med. Piotr Rutkowski
prof. dr hab. med. Krzysztof Składowski
prof. dr hab. med. Piotr Wysocki

Scientific Board

dr Edita Baltruskeviciene (Vilnius, Lithuania)
prof. Tomasz M. Beer (Portland, USA)
prof. Bartosz Chmielowski (Los Angeles, USA)
dr med. Joanna Didkowska
dr hab. med. Renata Duchnowska
dr Rick Haas (Leiden, The Netherlands)
dr med. Beata Jagielska
dr med. Jerzy Jarosz
prof. dr hab. med. Jacek Jassem
prof. dr hab. med. Arkadiusz Jezierski
prof. dr hab. med. Jan Kornafel
prof. dr hab. med. Jan Kulpa
prof. dr hab. med. Radziław Kordek

dr hab. med. Maria Litwiniuk
dr med. Aleksandra Łacko
prof. Ruggero De Maria (Rome, Italy)
dr Mario Mandala (Bergamo, Italy)
dr hab. med. Radosław Mądry
dr med. Janusz Meder
dr hab. med. Sergiusz Nawrocki
prof. dr hab. med. Włodzimierz Olszewski
prof. dr hab. med. Maria Podolak-Dawidziak
dr hab. med. Barbara Radecka
prof. dr hab. med. Tadeusz Robak
prof. dr hab. med. Kazimierz Roszkowski
prof. dr hab. med. Piotr Rutkowski
dr hab. med. Ewa Sierko
dr Silvia Stacchiotti (Milan, Italy)
dr Ryszard Szydło (London, UK)
prof. dr hab. med. Jerzy Walecki
prof. dr hab. med. Jan Walewski
prof. dr hab. med. Krzysztof Warzocha
prof. dr hab. med. Marek Wojtukiewicz
dr Agnieszka Wozniak (Leuven, Belgium)
prof. Christoph Zielinski (Vienna, Austria)

Managing Editor

Izabela Siemaszko

Opinions presented in the articles do not necessarily represent the opinions of the Editors

Oncology in Clinical Practice (ISSN 2450–1654) is published six times a year by

VM Media sp. z o.o. VM Group sp.k.
ul. Świętokrzyska 73, 80–180 Gdańsk, Poland
Phone: (+48 58) 320 94 94, fax: (+48 58) 320 94 60
e-mail: redakcja@viamedica.pl,
<http://www.viamedica.pl>, wap.viamedica.pl



19-0214.012.001

Editorial Address

Klinika Nowotworów Płuca i Klatki Piersiowej
Narodowy Instytut Onkologii im. Marii Skłodowskiej-Curie — Państwowy Instytut Badawczy
ul. Roentgena 5, 02–781 Warszawa, Poland
Phone: (+48 22) 546 21 69
e-mail: sekretariat4@coi.waw.pl

Advertising

For details on media opportunities within this journal please contact the advertising sales department, ul. Świętokrzyska 73, 80–180 Gdańsk, Poland, phone: (+48 58) 326 78 20; e-mail: dsk@viamedica.pl

The Editors accept no responsibility for the advertisement contents.

All rights reserved, including translation into foreign languages. No part of this periodical, either text or illustration, may be used in any form whatsoever. It is particularly forbidden for any part of this material to be copied or translated into a mechanical or electronic language and also to be recorded in whatever form, stored in any kind of retrieval system or transmitted, whether in an electronic or mechanical form or with the aid of photocopying, microfilm, recording, scanning or in any other form, without the prior written permission of the publisher. The rights of the publisher are protected by national copyright laws and by international conventions, and their violation will be punishable by penal sanctions.

Legal note: <http://czasopisma.viamedica.pl/owpk/about/legalNote>

Indexed in **Index Copernicus (ICV 2018 = 84.45)**, **Ulrich's Periodicals Directory** and **CAS**.

According to the statement of the Polish Ministry of Science and Higher Education publication in the journal has been awarded with **20 points**.

Editorial policies and author guidelines are published on journal website: http://journals.viamedica.pl/oncology_in_clinical_practice

The journal "Oncology in Clinical Practice" is financed under Contract No. 790/P-DUNdem/2019 by the funds of the Minister of Science and Higher Education for the science promotion activities.



Ministerstwo Nauki
i Szkolnictwa Wyższego



Copyright © 2020 Via Medica

ONCOLOGY

IN CLINICAL PRACTICE

Official Journal of the Polish Society of Clinical Oncology

https://journals.viamedica.pl/oncology_in_clinical_practice

2020, Vol. 16, Number 1

REVIEW ARTICLES

Contemporary diagnostic and therapeutic possibilities in patients with adenoid cystic carcinoma of the head and neck

Beata Jagielska, Elżbieta Sarnowska, Tomasz Sarnowski, Katarzyna Śmiałek-Kania,
Janusz Siedlecki, Andrzej Kawecki 1

Febrile neutropenia prophylaxis with short- and long-acting granulocyte colony-stimulating factors during treatment of solid tumours

Łukasz Kwinta 9

The evolution of biologics in the context of oncological therapy

Bartłomiej Żerek, Wojciech Straś, Piotr Różga, Elżbieta Pękala..... 14

Diagnosis and treatment of malignant PEComa tumours

Aleksandra Sobiborowicz, Anna M Czarnecka, Anna Szumera-Ciećkiewicz,
Piotr Rutkowski, Tomasz Świtaj..... 22

CASE REPORTS

Symptoms of nervous system damage in a patient undergoing anti-PD1 immunotherapy

Monika Misztal, Magdalena Krakowska, Monika Ryś-Bednarska, Mariusz Śliwa, Piotr Potemski..... 34

Breast implant-associated anaplastic large cell lymphoma (BIA-ALCL)

Róża Poźniak-Balicka, Dawid Murawa 36

Beata Jagielska¹, Elżbieta Sarnowska², Tomasz Sarnowski², Katarzyna Śmiałek-Kania¹,
 Janusz Siedlecki², Andrzej Kawecki³

¹Department of Oncology Diagnostics, Cardioncology and Palliative Medicine, Maria Skłodowska-Curie National Research Institute of Oncology, Warsaw, Poland

²Department of Molecular and Translational Oncology, Maria Skłodowska-Curie National Research Institute of Oncology, Warsaw, Poland

³Department of Head and Neck Cancer, Maria Skłodowska-Curie National Research Institute of Oncology, Warsaw, Poland

Contemporary diagnostic and therapeutic possibilities in patients with adenoid cystic carcinoma of the head and neck

Address for correspondence:

Lek. Katarzyna Śmiałek-Kania
 Klinika Diagnostyki Onkologicznej,
 Kardiopneumologii i Medycyny Paliatywnej
 Narodowy Instytut Onkologii
 im. Marii Skłodowskiej-Curie
 — Państwowy Instytut Badawczy
 ul. Roentgena 5, 02-781 Warszawa
 e-mail: ksmialek86@gmail.com

ABSTRACT

Adenoid cystic carcinoma (SACC, ACC) in the head and neck area, occurring in small and large salivary glands are relatively rare tumors, usually undergoing slow progression. ACC is characterized by a different clinical course compared to other cancers, with a long latency period, a tendency to form late, initially asymptomatic metastases and a small percentage of responses to systemic treatment. This article presents current recommendations for diagnostic procedures and treatment possibilities.

Key words: adenoid cystic carcinoma, ACC, SACC, head and neck

Oncol Clin Pract 2020; 16, 1: 1–8

Oncology in Clinical Practice

2020, Vol. 16, No. 1, 1–8

DOI: 10.5603/OCP.2020.0005

Translation: dr n. med. Dariusz Stencel

Copyright © 2020 Via Medica

ISSN 2450–1654

Introduction

Adenoid cystic carcinomas (ACC) in the head and neck area, occurring in small and large salivary glands (salivary adenoid cystic carcinoma [SACC]), comprise a relatively rare form of cancers, usually of slow progression. This type of cancer was described for the first time by Billroth in 1859 as a “cylindroma”, due to the formation of specific structures resembling cylindromatosis. ACCs are characterised by a different clinical course compared to other cancers, with a long latency period, a tendency to form late, initially asymptomatic metastases, and a low response rate to systemic treatment [1, 2].

Epidemiology

ACCs account for about 1% of all malignant neoplasms of the head and neck region and 10% of all salivary gland tumours. ACCs develop more often in small than in large salivary glands. Locations outside the large salivary glands include the salivary glands of the tongue, paranasal sinuses, the palate, nasopharynx, or lacrimal glands. Adenoid cystic carcinomas extremely rarely develop in the secretory glands such as the bronchial tree, oesophagus, mammary glands, lungs, prostate, cervix, or Bartholin’s glands [2–9]. ACCs in head and neck organs can occur at any age. Some authors indicate that in patients before 40 years of age and over 60 years of

age there are higher relapse rates. Many authors report that ACCs are more often diagnosed in women than in men. According to Dillon, this ratio is 60:40 and may be associated with more favourable prognosis in women, although this is not confirmed by the results of some other studies [1, 3, 9–11].

Pathomorphological characteristics

Originally, ACCs were called “cylindroma” due to their characteristic pathomorphological picture, consisting of cylindrical epithelial cells with the presence of hyaline stroma. ACC cell nuclei are hyperchromatic and contain a small amount of transparent or eosinophilic cytoplasm [1, 3, 4, 12, 13].

In the electron microscope image, two-phase differentiation of elements is visible in immunohistochemical studies — both myoepithelial and glandular secretory, with the former being dominant. Malignant cells can also produce glandular-like structures based on the glycosaminoglycan matrix and basement membrane elements.

Based on pathomorphological examination, three subtypes of cancer are distinguished: cribriform (most common), tubular, and solid (most clinically aggressive). Five-year and 15-year survival rates in patients with high- and medium-differentiated forms of ACC (pathomorphologically corresponding to cribriform and tubular types) are approx. 90% and 40%, respectively.

In the cribriform subtype islands of basaloid cells are visible, surrounded by cystic structures of varying sizes, similar in structure to “Swiss cheese” [14]. The tubular subtype has a cytological appearance similar to that of the cribriform subtype, but the tumour cells are located in nests surrounded by a variable amount of eosinophilic, often hyaline stroma. The cells of solid ACC are characterised by a cluster of basaloid cells without tubules or pseudocystic structures. The solid type is often diagnosed in advanced stage with the presence of distant metastases [3, 14, 15]. ACCs indicate a high tendency to spread along nerve structures [3, 14]. Myoepithelial tumour cells surrounding pseudocysts show a positive response for smooth muscle actin, S100, vimentin, and smooth muscle myosin heavy chains, as well as a strong reaction for c-KIT (CD117) and MYB tyrosine kinase receptors, regardless of the degree of malignancy. It is believed that the expression of c-KIT and vascular endothelial growth factor receptors (VEGFR) may correlate with an aggressive course of the cancer and unfavourable prognosis. It cannot be excluded that the interaction between Beclin-1 and p53 and Bcl-2 may play a role in the pathogenesis of cancer and that P53 expression is particularly pronounced during disease progression [3, 4, 6, 12, 16–18].

Molecular disorders

Many researchers point to the inability to perform detailed analyses of ACC pathogenesis mechanisms due to the lack of verified cell lines. However, the available results of tests using primitive xenografts provide some interesting observations [3, 18]. Analysis of tumour RNA using microarrays revealed that the expression of genes responsible for myoepithelial ACC differentiation is associated with the presence of transcription factor SOX4 [3, 19]. Under physiological conditions, SOX4 regulates embryonic development and probably oncogenesis. Overexpression of casein kinase 1 (CK1), epsilon, and frizzled-7 is also observed, which may induce the Wnt/ β -catenin signalling pathway and thus carcinogenesis. Expression of C-kit protein was also demonstrated in most ACC cells that correlated with the degree of cell proliferation [3, 20].

There was no correlation between bcl-2 protein expression, c-erbB-2 overexpression, transforming growth factor-alpha, epidermal growth factor receptor, and oestrogen and progesterone receptors and the degree of cancer differentiation and clinical progression [22–26]. A significant percentage of ACC patients have been found to have androgen receptor expression, which may be an important pathological marker of the disease [14].

The assessment of risk factors for overall survival (OS) and disease-free survival (DFS) in ACC indicates that one of them is perineural infiltration [9, 22]. There are few studies available explaining the pathomechanism of the molecular causes of this phenomenon. Some of them confirmed in vitro that the adhesion molecule of nerve cell is a basement membrane glycoprotein in ACC cell lines, and ACC cells stain evenly positively for the nerve cell adhesion molecule regardless of the degree of invasion. Kowalski demonstrated the expression of cytoplasmic protein BDNF (brain-derived neurotrophic factor) in ACC cells regardless of the degree of histological malignancy or perineural invasion. BDNF belongs to the neurotrophin family. These proteins have trophic functions and affect the proliferation, migration, differentiation, and integrity of many types of neurons. Neurons transport BDNF retrograde (target towards neuron) and anterograde (neuron to target), providing complex interactions between neurons and target tissues. The effect of BDNF on perineural invasion is attributed to the fact that indirect transport of BDNF protein from peripheral nerves is ultimately taken up by the target tissue, in this case ACC cells. An alternative hypothesis is that ACC may have a reverse function and spontaneously produce BDNF, creating a concentration gradient reached by peripheral nerves. The latter hypothesis undermines the findings to date that peripheral nerves are static entities actively infiltrated by cancer cells, which may be specific for ACC cells [22, 27, 28].

ACC is characterised by the presence of numerous somatic genetic mutations and characteristic chromosomal mutual translocations. One of the most important seems to be the translocation between chromosomes 6q and 9p ([6; 9] [q22–23; p23–24]), which is quite characteristic for this cancer and occurs in about 86% of patients. Persson was the first to demonstrate that this rearrangement results in the combination of *MYB* oncogene and nuclear transcription factor I/B (NFIB), which may result in the activation of MYB targets, affecting apoptosis, cell cycle control, and cell proliferation [3, 29–31]. Another significant demonstrated translocation was t(11; 19) causing the fusion of *CTRC/MAML2* genes. It has specific implications because clinical observations indicate that tumours in which fusions occur are less aggressive than those without fusion. Numerous studies are currently underway using new therapeutic targets, such as transcription factors and cancer fusion proteins [14, 32].

Distant metastases

A characteristic feature of ACC is not only slow local progression, but also relatively rare regional lymph node involvement. It is believed that a significant percentage of local recurrences and distant metastases seen after local treatment are associated with perineural infiltration, which results in a lack of microscopic radicality of surgery and a tendency to form haematopoietic metastases, even at early stages [9, 10, 15, 32, 33].

Adenoid cystic carcinomas have a long latency of distant metastases (up to 15 years), and the main metastatic sites are lungs and bones. In observation of 467 patients treated between 1963 and 2009, Gao reported distant metastases in 45 patients (31.0%); 20% of them had early disease progression and no local recurrence. The incidence of metastases has been shown to be dependent on the histopathological subtype and is 47.7%, 29.9%, and 27.3% in solid, cribriform, and tubular subtypes, respectively (16–35% on average) [34]. Other risk factors associated with unfavourable survival prognosis include the stage at diagnosis, advanced age, and lack of radical resection [4].

Due to the specific clinical course, particularly long-term follow-up is recommended in patients with solid subtype ACC, a significant proportion of whom have distant metastases. In 20-year follow-up, at intervals of 5, 10, 15, and 20 years, the overall survival rate in patients with distant metastases is 69.1%, 45.7%, 26.5%, and 14.3%, respectively, and in metastatic patients 85.6%, 67.4%, 57.6%, and 50.4%, respectively. More than half of patients with distant metastases have been shown to die within 10 years, and more than half without metastases survive for 20 years after diagnosis

of ACC [34]. In a study by Sung, the median survival of ACC patients with distant metastases was 38 months (1–149 months), and in studies by Matsuba and Gao, 48 months and 36 months, respectively [34–36].

The Monterio study found that distant metastases were most often diagnosed in lungs (78.6%) as well as in liver and bones (21%), and less frequently in kidneys and brain (approx. 3.5%). It was observed that patients with limited lung metastases had a better prognosis compared to other patients with metastases [4].

Radical treatment

Surgery is the treatment of choice in the early stages of ACC. Indications for adjuvant radiotherapy include a narrow or positive surgical margin without the possibility of radicalisation, lymph node involvement, significant local advancement, or perineural infiltration. Although no prospective clinical trials have been carried out so far, the results of retrospective analyses indicate that patients benefit from such a procedure. For example, the results of a study by the Dutch Head and Neck Oncology Cooperative Group showed a lower rate of local recurrence after adjuvant radiotherapy [14]. British experience, based on the analysis of 50 cases of patients with salivary gland cancers, also confirmed a high rate of local cure, reaching 96% with adjuvant radiotherapy after surgical treatment with facial nerve sparing. In the Miglanico retrospective study, the percentage of cases without recurrence in the five-year follow-up in patients treated with adjuvant radiation was 78% compared to 44% after surgery alone [40]. In another historical study, Simpson reported that in patients either receiving adjuvant radiation therapy or undergoing surgery alone the 10-year local cure rate was 83% and 25%, respectively [3, 41]. Mendenhall et al. reported local cure rates for radiotherapy alone and surgery with complementary radiotherapy of 56%, 94% and 43%, 91%, respectively, and overall control rates of 77% and 69%, respectively. The five- and 10-year distant metastases-free survival rates were 80% and 73%, respectively. The five- and 10-year OS rates were: 57% and 42% for radiotherapy alone; 77% and 55% for surgery with complementary radiotherapy; and 68% and 49% for the whole observation. Tumour size ($p = 0.0043$) and clinical perineural invasion ($p = 0.0011$) were the most important factors affecting OS in multivariate analysis [42].

In the case of significant local advancement excluding the use of surgery, radiotherapy is the treatment of choice. In many clinical situations, radiation is a palliative method of treatment reducing cancer-related symptoms [14].

Treatment with radiotherapy using fast neutrons produced interesting results in patients with ACC.

In theory, this method has higher biological efficiency compared to conventional radiotherapy with photons or electrons. In a small, phase III study the local cure rate was 56% after neutron treatment and 17% after photon irradiation ($p = 0.009$) [14, 43].

Unfortunately, neutron radiation therapy is associated with more frequent late complications and a higher incidence of distant metastases, although the latter may be the result of longer survival. The results of subsequent studies confirm these reports. Currently, radiation therapy using neutrons is not recommended in ACC [14, 42, 43].

There are scarce data regarding the effectiveness of radiochemotherapy, both as independent treatment and as complementary treatment after surgery. Among others, this results from the limited activity of cisplatin, which is the most commonly used cytostatic in combination with radiation therapy in ACC patients. In a retrospective study evaluating the effectiveness of chemoradiotherapy (RADPLAT) with intra-arterial cisplatin administration, Samant noticed a therapeutic response in 14/16 patients (seven complete and seven partial responses). The overall percentage of responses, relapses, and local cures during the five-year follow-up was 87%, 39%, and 61%, respectively. Progression was found in eight patients, including eight in the form of distant metastases and three in the form of local recurrence [44].

Due to the limited population of patients undergoing chemoradiotherapy using intravenous or intra-arterial cisplatin, data on the effectiveness of this method should be interpreted with caution, especially those regarding the control of distant metastases due to the specific kinetics of ACC cell growth and the long latency period of symptoms observed in this cancer. Nevertheless, it cannot be ruled out that this may be an effective therapeutic method for specific patient populations [43, 44]. There is currently a clinical trial ongoing dedicated to assessing the efficacy of complementary combined therapy compared to radiotherapy alone in patients with high-risk salivary gland cancer after surgery (RTOG 1008 — A Randomized Phase II/III Study of Adjuvant Concurrent Radiation and Chemotherapy Versus Radiation Alone in Resected High-Risk Malignant Salivary Gland Tumors) <https://clinicaltrials.gov/ct2/show/NCT01220583> [45]. It cannot be ruled out that the results of this study will greatly contribute to establishing the standard of adjuvant treatment in patients with ACC.

Chemotherapy

The effectiveness of standard chemotherapy in patients with ACC is limited, among others due to the slow proliferation of cancer cells. Many analyses assessing the activity of classic chemotherapy indicate its low

effectiveness [46–48]. The subject of several studies has been a chemotherapy regimen combining anthracyclines with platinum derivatives (cyclophosphamide, doxorubicin, and cisplatin) [46, 49]. There was no significant advantage of the triple-drug scheme over monotherapy, but it should be noted that so far no large, prospective studies with random patient selection comparing multi- and single-drug regimens have been conducted [46]. In 2016, a summary of research conducted in the years 2001–2015 on the use of chemotherapy in salivary gland tumours, including ACC, adenocarcinoma not otherwise specified (NOS), and mucoepidermoid carcinoma (MEC), was published. This is one of the few large studies concerning the use of chemotherapy in patients with ACC [46]. It has been shown that in most studies, cisplatin or carboplatin was used in multi-drug regimens. Nearly 50% of analyses were dedicated to ACC. It was emphasised that the results of four studies may indicate the potential effectiveness of multi-drug regimens containing platinum derivatives. Airoidi in a small, randomised study reported higher therapeutic response rates in patients treated with cisplatin and vinorelbine compared to vinorelbine alone (44% and 20%, respectively). The objective response rate (ORR) as well as OS showed a trend towards statistical significance in favour of the combination arm [50]. In another analysis presented in this publication, regarding chemotherapy consisting of cisplatin and mitoxantrone, the objective response rate was 14% and median OS was 27 months [51]. In the analysis by the National Cancer Institute of Canada Clinical Trials Group, in patients with advanced salivary gland cancers, including ACC, treated with cisplatin and gemcitabine the objective responses rate was 24%. Four out of eight patients with adenocarcinoma had a partial response, and in one case it was complete response [52, 53]. The results regarding three-drug regimen published by Ross (cisplatin/carboplatin, epirubicin and 5-fluorouracil) in eight ACC patients demonstrated low efficacy, and objective response was reported in a single case. However, the author emphasised the potential benefits in terms of median survival of 27 months. It should be critically noted that the naturally slow cancer course could have had a paramount influence on survival [53, 54].

The reports regarding efficacy of single-agent chemotherapy are also limited. In 2006, the results of the Eastern Cooperative Oncology Group study using paclitaxel showed 18% responses, but only for patients with adenocarcinoma or MEC (29% adenocarcinoma and 21% MEC); no objective responses were observed in patients with ACC. Overall survival was comparable for all subtypes, which only confirmed other observations that the use of systemic therapy does not translate into an increase in overall survival benefit in metastatic salivary gland cancer [46, 55]. No benefit was seen in a study with gemcitabine in patients with ACC.

Based on current knowledge, it is advisable to recommend individual consideration of indications to chemotherapy, taking into account the naturally slow course of ACC in many cases. In asymptomatic patients, the implementation of chemotherapy should be deferred until the onset of symptoms or dynamic tumour progression. There are no reliable data showing the potential for any chemotherapy regimen to affect the survival in ACC patients.

Targeted therapy

The lack of satisfactory efficacy of standard chemotherapy, as well as the use of modern molecular diagnostic techniques, contributed to an increase in experience with the use of molecularly targeted treatment in ACC patients. The premise for the use of this type of therapy is the presence of numerous molecular abnormalities that are potential therapeutic goals. A theoretically attractive target appeared to be C-KIT overexpression occurring in a high percentage of ACC cells (65% to 90%) [3, 14, 46, 53]. Unfortunately, the results of studies using imatinib were unsatisfactory and only two of 42 patients in four phase II studies obtained objective responses. The addition of cisplatin did not increase the number of therapeutic responses. It cannot be excluded that the underlying phenomenon is the lack of molecular activity of C-KIT receptors, despite the overexpression. There was also no evidence of mutations in exon 9 or 11 of *C-KIT* gene in ACC cells, which were found in gastrointestinal stromal tumours [46, 56–59].

Attempts have also been made to use monoclonal antibodies and tyrosine kinase inhibitors such as cetuximab, gefitinib, and lapatinib [46, 60–62, 64–66]. There were no objective therapeutic responses after gefitinib or lapatinib use, but 79% of patients treated with lapatinib had disease stabilization, which in 36% lasted for six months or longer [64]. On the other hand, in a study with cetuximab and cisplatin the percentage of complete responses in patients with positive EGFR receptor was 22% (in 2/9 patients), and the proportion of partial responses was also 22% (2/9 patients) [57]. In patients with distant metastases, partial responses were recorded in 42% of patients (5/9 patients). Compared to gefitinib and lapatinib, cetuximab appears to be more effective, although the small number of treated patients requires caution in these types of claims [46, 64].

Multi-kinase inhibitors such as dovitinib, axitinib, sunitinib, sorafenib, and regorafenib have also been the subject of many studies. There were no complete responses in the study with sunitinib. Three further studies showed a partial response rate of approximately 10% [2/19 patients, 10.5% for dovitinib, 3/33 patients, 9% for axitinib and 2/19 patients (10.5%) in the sorafenib

group] [59]. Sorafenib was evaluated in two studies — one limited to ACC patients and one in a mixed population. Thomson reported 11% of total responses and a median OS of 19.6 months in ACC patients. Similarly, Locati et al. reported an overall response rate of 16% with a difference observed in ACC patients compared to others (11 vs. 22%) [46].

During the American Society of Clinical Oncology (ASCO) Annual Meeting in 2018 the results of two phase II studies assessing the efficacy of another tyrosine kinase inhibitor — lenvatinib — with selective kinase inhibitory activity for VEGFR1–3, FGR 1–4, and PDGF in recurrent/metastatic ACC were presented.

Tchekmdyian showed that 15.6% of patients achieved partial remission, disease stabilisation was achieved in 75%, and the progression-free survival was 16.4 months. [67] In contrast, Locati showed a total percentage of partial and total responses of 27% [68].

Despite the presence a significant percentage of the mutation covering the FGF-PI3K-AKT pathway in the molecular analysis of ACC cells, no patients were found to benefit from treatment with the AKT inhibitor MK-2206 and the mTOR inhibitor everolimus [46]. Similarly, nelfinavir, a proteasome inhibitor that proved effective in inhibiting AKT, did not affect the objective responses in patients with ACC [46]. It cannot be excluded that the reason for this phenomenon is the lack of specific genetic changes on this pathway being the therapeutic target in each cell line.

There was no benefit from the use of vorinostat, a histone deacetylase inhibitor (response rate approx. 3%), although theoretically ACC should have abnormalities in epigenetic regulation [46].

Particularly promising results were related to treatment with an eribulin inhibitor with an objective partial response rate of 10% [46, 65]. It seems that the use of eribulin inhibitors in patients with advanced or metastatic ACC will be a very promising direction for further research. Other potential targets of the experiment are fusion transcripts, such as ETV6-NTRK3 [43, 46, 64, 65], which characterise some malignant tumours of the salivary glands and are likely to be further targets for specific inhibitors (NCT02576431).

Current reports from prospective clinical trials indicating increasingly long disease control in ACC provide the basis for the further search for effective molecularly targeted therapies. This seems to be the most effective direction for clinical experience.

Hormonal therapy

Although no prospective studies have been conducted to assess the efficacy of hormone therapy in ACC patients to date, the presence of androgen receptor expression may be a potential therapeutic target.

Data from a retrospective study using bicalutamide and triptorelin show a therapeutic response of 65% [46]. In the Locati et al. analysis, the percentage of complete responses was 20% [43, 44, 46]. Second-line hormone therapy with abiraterone, a CYP17 inhibitor, has also been shown to be effective after first-line androgen deprivation failure [46]. Currently, EORTC is conducting a randomised, multicentre phase II study in Europe to assess the effectiveness of androgen deprivation in salivary gland cancer with positive androgen receptor expression (NCT01969578) [45].

Immunotherapy

Immunotherapy is one of the most promising trends in the development of systemic treatment in oncology. Clinical trials are also being carried out to assess the effectiveness of immunotherapy in patients with ACC. Previous preclinical experience suggests that programmed death ligand-1 (PD-L1) expression is associated with unfavourable disease-free survival and possibly with overall survival [56]. The preliminary data of the phase 1b KEYNOTE-028 study presented at ASCO 2016, which concerned patients with non-ACC, showed disease stabilisation in 12 patients (46%) and a time to progression of 20.7 months. In ACC patients, anti-cancer vaccines and adoptive immunotherapy using lymphopine-activated cells (LAKs) and cytokines were tested in a small number of clinical studies [59].

An *in vitro* study of immunotherapy on ACC cell line by a Chinese group of researchers confirmed that LAK cells showed cytotoxicity to ACC cells. The authors also concluded that both TNF- α and IFN- γ may enhance this cytotoxic process. It was previously reported that these cytokines induced differentiation and apoptosis. CTLA4 and PD-L1 receptors are other therapeutic targets that are under investigation, but available data are limited. It is necessary to conduct clinical trials dedicated exclusively to ACC [59].

Summary

Surgery combined with radiotherapy remains the standard radical treatment of ACC patients. The unsolved problem is still the management of distant metastases or inoperable relapses, which is associated with ACC resistance to conventional systemic treatment. The application of modern methods of molecular and genomic diagnostics and molecularly targeted therapy to clinical practice has significantly increased the percentage of total cures and has prolonged the survival in patients with cancer. The results of clinical trials obtained so far allow us to believe that also in the case of such

a distinctive cancer as ACC it will be possible to obtain satisfactory clinical responses that will translate into the extension of overall survival in advanced stages. The most promising direction of research seems to be the analysis of the effectiveness of eribulin, an inhibitor of dynamic microtubule instability in ACC. Preliminary results are very encouraging.

Another attractive research direction is the use of immunotherapy in ACC. Due to the rarity of the cancer and its different biology, it is most justified that this group of patients should be treated in reference centres with access to the experimental base, including diagnostic laboratories using high-tech molecular and genomic techniques. Patients with advanced forms of ACC should have an opportunity to participate in clinical trials. In the case of heterogeneous cancers such as ACC, the “unsize” approach must be avoided. When selecting a therapy, one should be guided by stage, performance status, the presence of comorbidities, and, above all, the patient’s preferences regarding optimal management. In classic advanced ACC forms of slow course, especially in cribriform and tubular subtypes, observation may be considered.

Adenoid cystic carcinomas are still a challenge for the oncologist. They require experience and a multidisciplinary approach to the patient. Despite the application of innovative diagnostic methods to clinical practice and progress in treatment, ACC still remains a complex problem for the diagnostician and therapist, often called the “paradox” of oncology. It is hoped that interdisciplinary cooperation using translational medicine will change the face of this rare and still mysterious disease.

References

- Martínez-Rodríguez N, Leco-Berrocal I, Rubio-Alonso L, et al. Epidemiology and treatment of adenoid cystic carcinoma of the minor salivary glands: a meta-analytic study. *Med Oral Patol Oral Cir Bucal*. 2011; 16(7): e884–e889, doi: 10.4317/medoral.17200, indexed in Pubmed: 21743416.
- Rinaldo A, Shaha AR, Pellitteri PK, et al. Management of malignant sublingual salivary gland tumors. *Oral Oncol*. 2004; 40(1): 2–5, indexed in Pubmed: 14662408.
- Dillon P, Chakraborty S, Moskaluk C, et al. Adenoid cystic carcinoma: a review of recent advances, molecular targets, and clinical trials. *Head & Neck*. 2015; 38(4): 620–627, doi: 10.1002/hed.23925.
- Monteiro D, Lino J, Bernardo T, et al. Adenoid cystic carcinoma of the head and neck: epidemiology and predictors of prognosis. *Int J Head Neck Surg*. 2013; 02(05): 165–173, doi: 10.4236/ijohns.2013.25036.
- Spiro RH, Huvos AG. Stage means more than grade in adenoid cystic carcinoma. *Am J Surg*. 1992; 164(6): 623–628, doi: 10.1016/s0002-9610(05)80721-4, indexed in Pubmed: 1334380.
- Khan AJ, DiGiovanna MP, Ross DA, et al. Adenoid cystic carcinoma: a retrospective clinical review. *Int J Cancer*. 2001; 96(3): 149–158, doi: 10.1002/ijc.1013, indexed in Pubmed: 11410883.
- Chummun S, McLean NR, Kelly CG, et al. Adenoid cystic carcinoma of the head and neck. *Br J Plast Surg*. 2001; 54(6): 476–480, doi: 10.1054/bjps.2001.3636, indexed in Pubmed: 11513507.
- Spiro RH, Huvos AG, Strong EW. Adenoid cystic carcinoma of salivary origin. A clinicopathologic study of 242 cases. *Am J Surg*. 1974; 128(4): 512–520, doi: 10.1016/0002-9610(74)90265-7, indexed in Pubmed: 4371368.

9. Prasad AR, Saveria AT, Gown AM, et al. The myoepithelial immunophenotype in 135 benign and malignant salivary gland tumors other than pleomorphic adenoma. *Arch Pathol Lab Med.* 1999; 123(9): 801–806, doi: [10.1043/0003-9985\(1999\)123<0801:TMIIBA>2.0.CO;2](https://doi.org/10.1043/0003-9985(1999)123<0801:TMIIBA>2.0.CO;2), indexed in Pubmed: 10458827.
10. Moskaluk CA. Adenoid cystic carcinoma: clinical and molecular features. *Head Neck Pathol.* 2013; 7(1): 17–22, doi: [10.1007/s12105-013-0426-3](https://doi.org/10.1007/s12105-013-0426-3), indexed in Pubmed: 23463073.
11. Choi Y, Kim SB, Yoon D, et al. Clinical characteristics and prognostic factors of adenoid cystic carcinoma of the head and neck. *Laryngoscope.* 2013; 123(6): 1430–1438, doi: [10.1002/lary.23976](https://doi.org/10.1002/lary.23976).
12. Azumi N, Battifora H. The cellular composition of adenoid cystic carcinoma. An immunohistochemical study. *Cancer.* 1987; 60(7): 1589–1598, doi: [10.1002/1097-0142\(19871001\)60:7<1589::aid-cn-cr2820600729>3.0.co;2-u](https://doi.org/10.1002/1097-0142(19871001)60:7<1589::aid-cn-cr2820600729>3.0.co;2-u), indexed in Pubmed: 2441847.
13. Caselitz J, Schulze I, Seifert G. Adenoid cystic carcinoma of the salivary glands: an immunohistochemical study. *J Oral Pathol.* 1986; 15(6): 308–318, doi: [10.1111/j.1600-0714.1986.tb00631.x](https://doi.org/10.1111/j.1600-0714.1986.tb00631.x).
14. Adelstein DJ, Shlomo A, Koyfman A, et al. Biology and management of salivary gland cancers. *Semin Radiat Oncol.* 2012; 22(3): 245–253, doi: [10.1016/j.semradonc.2012.03.009](https://doi.org/10.1016/j.semradonc.2012.03.009), indexed in Pubmed: 22687949.
15. Piotrowska-Seweryn A, Pietruszka K, Groszkiewicz K, et al. Rak gruczołowo-torbielowy regionu głowy i szyi — trudności diagnostyczne i metody leczenia. *Otolaryngologia.* 2017; 16(3): 88–93.
16. Vila L, Liu H, Al-Quran S, et al. Identification of c-kit gene mutations in primary adenoid cystic carcinoma of the salivary gland. *Mod Pathol.* 2009; 22(10): 1296–1302, doi: [10.1038/modpathol.2009.95](https://doi.org/10.1038/modpathol.2009.95).
17. Frierson H, El-Naggar A, Welsh J, et al. Large scale molecular analysis identifies genes with altered expression in salivary adenoid cystic carcinoma. *Am J Pathol.* 2002; 161(4): 1315–1323, doi: [10.1016/s0002-9440\(10\)64408-2](https://doi.org/10.1016/s0002-9440(10)64408-2).
18. Marcinow A, Ozer E, Teknos T, et al. Clinicopathologic predictors of recurrence and overall survival in adenoid cystic carcinoma of the head and neck: a single institutional experience at a tertiary care center. *Head Neck.* 2014; 36(12): 1705–1711, doi: [10.1002/hed.23523](https://doi.org/10.1002/hed.23523), indexed in Pubmed: 24166847.
19. Dong C, Wilhelm D, Koopman P. Sox genes and cancer. *Cytogenet Genome Res.* 2004; 105(2–4): 442–447, doi: [10.1159/000078217](https://doi.org/10.1159/000078217), indexed in Pubmed: 15237232.
20. Daa T, Kashima K, Kaku N, et al. Mutations in components of the Wnt signaling pathway in adenoid cystic carcinoma. *Mod Pathol.* 2004; 17(12): 1475–1482, doi: [10.1038/modpathol.3800209](https://doi.org/10.1038/modpathol.3800209).
21. Edwards PC, Bhuiya T, Kelsch RD. C-kit expression in the salivary gland neoplasms adenoid cystic carcinoma, polymorphous low-grade adenocarcinoma, and monomorphic adenoma. *Oral Surg Oral Med Oral Pathol Oral Radiol Endod.* 2003; 95(5): 586–593, doi: [10.1067/moe.2003.31](https://doi.org/10.1067/moe.2003.31), indexed in Pubmed: 12738950.
22. Kowalski P, Paulino A. Perineural invasion in adenoid cystic carcinoma: Its causation/promotion by brain-derived neurotrophic factor. *Hum Pathol.* 2002; 33(9): 933–936, doi: [10.1053/hupa.2002.128249](https://doi.org/10.1053/hupa.2002.128249).
23. Cho KJ, Lee SS, Lee YS. Proliferating cell nuclear antigen and c-erbB-2 oncoprotein expression in adenoid cystic carcinomas of the salivary glands. *Head Neck.* 1999; 21(5): 414–419, indexed in Pubmed: 10402521.
24. Gibbons MD, Manne U, Carroll WR, et al. Molecular differences in mucoepidermoid carcinoma and adenoid cystic carcinoma of the major salivary glands. *Laryngoscope.* 2001; 111(8): 1373–1378, doi: [10.1097/00005537-200108000-00011](https://doi.org/10.1097/00005537-200108000-00011), indexed in Pubmed: 11568571.
25. Chiang CP, Chen CH, Liu BY, et al. Expression of transforming growth factor-alpha in adenoid cystic carcinoma of the salivary gland. *J Formos Med Assoc.* 2001; 100(7): 471–477, indexed in Pubmed: 11579613.
26. Dori S, Trougouboff P, David R, et al. Immunohistochemical evaluation of estrogen and progesterone receptors in adenoid cystic carcinoma of salivary gland origin. *Oral Oncol.* 2000; 36(5): 450–453, indexed in Pubmed: 10964052.
27. Altar CA, Cai N, Bliven T, et al. Anterograde transport of brain-derived neurotrophic factor and its role in the brain. *Nature.* 1997; 389(6653): 856–860, doi: [10.1038/39885](https://doi.org/10.1038/39885), indexed in Pubmed: 9349818.
28. Zhou XF, Rush RA. Endogenous brain-derived neurotrophic factor is anterogradely transported in primary sensory neurons. *Neuroscience.* 1996; 74(4): 945–951, doi: [10.1016/0306-4522\(96\)00237-0](https://doi.org/10.1016/0306-4522(96)00237-0).
29. Ho AS, Kannan K, Roy DM, et al. The mutational landscape of adenoid cystic carcinoma. *Nat Genet.* 2013; 45(7): 791–798, doi: [10.1038/ng.2643](https://doi.org/10.1038/ng.2643), indexed in Pubmed: 23685749.
30. Persson F, Fehr A, Sundelin K, et al. Studies of genomic imbalances and the MYB-NFIB gene fusion in polymorphous low-grade adenocarcinoma of the head and neck. *Int J Oncol.* 2012; 40(1): 80–84, doi: [10.3892/ijo.2011.1190](https://doi.org/10.3892/ijo.2011.1190), indexed in Pubmed: 21901247.
31. Persson M, Andrén Y, Moskaluk CA, et al. Clinically significant copy number alterations and complex rearrangements of MYB and NFIB in head and neck adenoid cystic carcinoma. *Genes Chromosomes Cancer.* 2012; 51(8): 805–817, doi: [10.1002/gcc.21965](https://doi.org/10.1002/gcc.21965), indexed in Pubmed: 22505352.
32. Del Negro A, Ichihara E, Tincani AJ, et al. Laryngeal adenoid cystic carcinoma: case report. *Sao Paulo Med J.* 2007; 125(5): 295–296, indexed in Pubmed: 18094899.
33. Singh FM, Mak SY, Bonington SC, et al. Patterns of spread of head and neck adenoid cystic carcinoma. *Clin Radiol.* 2015; 70: 644–653, doi: [10.1016/j.crad.2015.01.013Epub2015Mar11](https://doi.org/10.1016/j.crad.2015.01.013Epub2015Mar11).
34. Gao M, Hao Y, Huang MX, et al. Clinicopathological study of distant metastases of salivary adenoid cystic carcinoma. *Int J Oral Maxillofac Surg.* 2013; 42(8): 923–928, doi: [10.1016/j.ijom.2013.04.006](https://doi.org/10.1016/j.ijom.2013.04.006), indexed in Pubmed: 23706387.
35. Sung MW, Kim K, Kim JW, et al. Clinicopathologic predictors and impact of distant metastasis from adenoid cystic carcinoma of the head and neck. *Arch Otolaryngol Head Neck Surg.* 2003; 129(11): 1193, doi: [10.1001/archotol.129.11.1193](https://doi.org/10.1001/archotol.129.11.1193).
36. Matsuba H, Spector G, Thawley S, et al. Adenoid cystic salivary gland carcinoma: a histopathologic review of treatment failure patterns. *Cancer.* 1986; 57(3): 519–524, doi: [10.1002/1097-0142\(19860201\)57:3<519::aid-cn-cr2820570319>3.0.co;2-v](https://doi.org/10.1002/1097-0142(19860201)57:3<519::aid-cn-cr2820570319>3.0.co;2-v).
37. North C, Lee DJ, Piantadosi S, et al. Carcinoma of the major salivary glands treated by surgery or surgery plus postoperative radiotherapy. *Int J Radiat Oncol Biol Phys.* 1990; 18(6): 1319–1326, doi: [10.1016/0360-3016\(90\)90304-3](https://doi.org/10.1016/0360-3016(90)90304-3).
38. Terhaard CHJ, Lubsen H, Rasch CRN, et al. Dutch Head and Neck Oncology Cooperative Group. The role of radiotherapy in the treatment of malignant salivary gland tumors. *Int J Radiat Oncol Biol Phys.* 2005; 61(1): 103–111, doi: [10.1016/j.ijrobp.2004.03.018](https://doi.org/10.1016/j.ijrobp.2004.03.018), indexed in Pubmed: 15629600.
39. Bissett RJ, Fitzpatrick PJ. Malignant submandibular gland tumors. A review of 91 patients. *Am J Clin Oncol.* 1988; 11(1): 46–51, indexed in Pubmed: 3341274.
40. Miglianico L, Eschwege F, Marandas P, et al. Cervico-facial adenoid cystic carcinoma: study of 102 cases. Influence of radiation therapy. *Int J Radiat Oncol Biol Phys.* 1987; 13(5): 673–678, doi: [10.1016/0360-3016\(87\)90284-7](https://doi.org/10.1016/0360-3016(87)90284-7), indexed in Pubmed: 3032876.
41. Simpson JR, Thawley SE, Matsuba HM. Adenoid cystic salivary gland carcinoma: treatment with irradiation and surgery. *Radiology.* 1984; 151(2): 509–512, doi: [10.1148/radiology.151.2.6324280](https://doi.org/10.1148/radiology.151.2.6324280), indexed in Pubmed: 6324280.
42. Mendenhall W, Morris C, Amdur R, et al. Radiotherapy alone or combined with surgery for adenoid cystic carcinoma of the head and neck. *Head Neck.* 2004; 26(2): 154–162, doi: [10.1002/hed.10380](https://doi.org/10.1002/hed.10380).
43. Laramore GE, Krall JM, Griffin TW, et al. Neutron versus photon irradiation for unresectable salivary gland tumors: final report of an RTOG-MRC randomized clinical trial. *Radiation Therapy Oncology Group. Medical Research Council. Int J Radiat Oncol Biol Phys.* 1993; 27(2): 235–240, doi: [10.1016/0360-3016\(93\)90233-I](https://doi.org/10.1016/0360-3016(93)90233-I), indexed in Pubmed: 8407397.
44. Samant S, Brekel Mv, Kies M, et al. Concurrent chemoradiation for adenoid cystic carcinoma of the head and neck. *Head Neck.* 2011; 34(9): 1263–1268, doi: [10.1002/hed.21905](https://doi.org/10.1002/hed.21905).
45. <https://clinicaltrials.gov/ct2/show/NCT01220583> (29.04.2019).
46. Chintakuntlawar A, Okuno S, Price K. Systemic therapy for recurrent or metastatic salivary gland malignancies. *Cancers Head Neck.* 2016; 1(1), doi: [10.1186/s41199-016-0011-z](https://doi.org/10.1186/s41199-016-0011-z).
47. Lagha A, Chraïet N, Ayadi M, et al. Systemic therapy in the management of metastatic or advanced salivary gland cancers. *Head Neck Oncol.* 2012; 4(1), doi: [10.1186/1758-3284-4-19](https://doi.org/10.1186/1758-3284-4-19).
48. Laurie S, Ho A, Fury M, et al. Systemic therapy in the management of metastatic or locally recurrent adenoid cystic carcinoma of the salivary glands: a systematic review. *Lancet Oncol.* 2011; 12(8): 815–824, doi: [10.1016/s1470-2045\(10\)70245-x](https://doi.org/10.1016/s1470-2045(10)70245-x).
49. Laurie SA, Licitra L. Systemic therapy in the palliative management of advanced salivary gland cancers. *J Clin Oncol.* 2006; 24(17): 2673–2678, doi: [10.1200/JCO.2005.05.3025](https://doi.org/10.1200/JCO.2005.05.3025), indexed in Pubmed: 16763282.
50. Airoidi M, Pedani F, Succo G, et al. Phase II randomized trial comparing vinorelbine versus vinorelbine plus cisplatin in patients with recurrent salivary gland malignancies. *Cancer.* 2001; 91(3): 541–547, doi: [10.1002/1097-0142\(20010201\)91:3<541::aid-cn-cr1032>3.0.co;2-y](https://doi.org/10.1002/1097-0142(20010201)91:3<541::aid-cn-cr1032>3.0.co;2-y).
51. Gedlicka C, Schüll B, Formanek M, et al. Mitoxantrone and cisplatin in recurrent and/or metastatic salivary gland malignancies. *Anticancer Drugs.* 2002; 13(5): 491–495, indexed in Pubmed: 12045460.
52. Laurie S, Siu L, Winquist E, et al. A phase 2 study of platinum and gemcitabine in patients with advanced salivary gland cancer. *Cancer.* 2010; 116(2): 362–368, doi: [10.1002/cncr.24745](https://doi.org/10.1002/cncr.24745).

53. Gilbert J, Li Yi, Pinto HA, et al. Phase II trial of taxol in salivary gland malignancies (E1394): a trial of the Eastern Cooperative Oncology Group. *Head Neck*. 2006; 28(3): 197–204, doi: [10.1002/hed.20327](https://doi.org/10.1002/hed.20327), indexed in Pubmed: [16470745](https://pubmed.ncbi.nlm.nih.gov/16470745/).
54. Holst VA, Marshall CE, Moskaluk CA, et al. KIT protein expression and analysis of c-kit gene mutation in adenoid cystic carcinoma. *Mod Pathol*. 1999; 12(10): 956–960, indexed in Pubmed: [10530560](https://pubmed.ncbi.nlm.nih.gov/10530560/).
55. Ross PJ, Teoh EM, A'hern RP et al. Epirubicin, cisplatin and protracted venous infusion 5-Fluorouracil chemotherapy for advanced salivary adenoid cystic carcinoma. *Clin Oncol (R Coll Radiol)*. 2009; 21(4): 311–314, doi: [10.1016/j.clon.2008.12.009](https://doi.org/10.1016/j.clon.2008.12.009), indexed in Pubmed: [19201585](https://pubmed.ncbi.nlm.nih.gov/19201585/).
56. Hotte SJ, Winquist EW, Lamont E, et al. Imatinib mesylate in patients with adenoid cystic cancers of the salivary glands expressing c-kit: a Princess Margaret Hospital phase II consortium study. *J Clin Oncol*. 2005; 23(3): 585–590, doi: [10.1200/JCO.2005.06.125](https://doi.org/10.1200/JCO.2005.06.125), indexed in Pubmed: [15659505](https://pubmed.ncbi.nlm.nih.gov/15659505/).
57. Pfeffer MR, Talmi Y, Catane R, et al. A phase II study of Imatinib for advanced adenoid cystic carcinoma of head and neck salivary glands. *Oral Oncol*. 2007; 43(1): 33–36, doi: [10.1016/j.oraloncology.2005.12.026](https://doi.org/10.1016/j.oraloncology.2005.12.026), indexed in Pubmed: [16757202](https://pubmed.ncbi.nlm.nih.gov/16757202/).
58. Guigay JM, Bidault F, Temam S, et al. Antitumor activity of imatinib in progressive highly expressing KIT adenoid cystic carcinoma of the salivary glands: a phase II study. *J Clin Oncol*. 2007; 25(18_suppl): 6086, doi: [10.1200/jco.2007.25.18_suppl.6086](https://doi.org/10.1200/jco.2007.25.18_suppl.6086).
59. Chae YK, Chung SuY, Davis AA, et al. Adenoid cystic carcinoma: current therapy and potential therapeutic advances based on genomic profiling. *Oncotarget*. 2015; 6(35): 37117–37134, doi: [10.18632/oncotarget.5076](https://doi.org/10.18632/oncotarget.5076), indexed in Pubmed: [26359351](https://pubmed.ncbi.nlm.nih.gov/26359351/).
60. Agulnik M, Cohen EWE, Cohen RB, et al. Phase II study of lapatinib in recurrent or metastatic epidermal growth factor receptor and/or erbB2 expressing adenoid cystic carcinoma and non adenoid cystic carcinoma malignant tumors of the salivary glands. *J Clin Oncol*. 2007; 25(25): 3978–3984, doi: [10.1200/JCO.2007.11.8612](https://doi.org/10.1200/JCO.2007.11.8612), indexed in Pubmed: [17761983](https://pubmed.ncbi.nlm.nih.gov/17761983/).
61. Jakob JA, Kies MS, Glisson BS, et al. Phase II study of gefitinib in patients with advanced salivary gland cancers. *Head Neck*. 2015; 37(5): 644–649, doi: [10.1002/hed.23647](https://doi.org/10.1002/hed.23647), indexed in Pubmed: [24585506](https://pubmed.ncbi.nlm.nih.gov/24585506/).
62. Jensen A, Nikoghosyan A, Hinke A, et al. Combined treatment of adenoid cystic carcinoma with cetuximab and IMRT plus C12 heavy ion boost: ACCEPT [ACC, Erbitux® and particle therapy]. *BMC Cancer*. 2011; 11(1), doi: [10.1186/1471-2407-11-70](https://doi.org/10.1186/1471-2407-11-70).
63. Locati LD, Bossi P, Perrone F, et al. Cetuximab in recurrent and/or metastatic salivary gland carcinomas: a phase II study. *Oral Oncol*. 2009; 45(7): 574–578, doi: [10.1016/j.oraloncology.2008.07.010](https://doi.org/10.1016/j.oraloncology.2008.07.010).
64. Hitre E, Budai B, Takácsi-Nagy Z, et al. Cetuximab and platinum-based chemoradio- or chemotherapy of patients with epidermal growth factor receptor expressing adenoid cystic carcinoma: a phase II trial. *Br J Cancer*. 2013; 109(5): 1117–1122, doi: [10.1038/bjc.2013.468](https://doi.org/10.1038/bjc.2013.468).
65. Eaton K, Goulart B, Santana-Davila R, et al. Phase II trial of eribulin for recurrent or metastatic salivary gland cancers. *J Clin Oncol*. 2016; 34(15_suppl): 6095, doi: [10.1200/jco.2016.34.15_suppl.6095](https://doi.org/10.1200/jco.2016.34.15_suppl.6095).
66. Skálová A, Vanecek T, Sima R, et al. Mammary analogue secretory carcinoma of salivary glands, containing the ETV6-NTRK3 fusion gene: a hitherto undescribed salivary gland tumor entity. *Am J Surg Pathol*. 2010; 34(5): 599–608, doi: [10.1097/PAS.0b013e3181d9efcc](https://doi.org/10.1097/PAS.0b013e3181d9efcc), indexed in Pubmed: [20410810](https://pubmed.ncbi.nlm.nih.gov/20410810/).
67. Tchekmedyian V, Sherman E, Dunn L, et al. A phase II study of lenvatinib in patients with progressive, recurrent/metastatic adenoid cystic carcinoma. *J Clin Oncol*. 2018; 36(15_suppl): 6022–6022, doi: [10.1200/jco.2018.36.15_suppl.6022](https://doi.org/10.1200/jco.2018.36.15_suppl.6022).
68. Locati L, Galbiati D, Calareso G, et al. Phase II study on lenvatinib (LEN) in recurrent and/or metastatic (R/M) adenoid cystic carcinoma (ACC) of the salivary glands (SG) of the upper aerodigestive tract (NCT02860936). *J Clin Oncol*. 2018; 36(15_suppl): 6086, doi: [10.1200/jco.2018.36.15_suppl.6086](https://doi.org/10.1200/jco.2018.36.15_suppl.6086).

Łukasz Kwinta 

Chair and Clinic of Oncology, Jagiellonian University — *Collegium Medicum*; Department of Oncology, University Hospital in Krakow, Poland

Febrile neutropenia prophylaxis with short- and long-acting granulocyte colony-stimulating factors during treatment of solid tumours

Address for correspondence:

Lek. Łukasz Kwinta
 Katedra i Klinika Onkologii
 Uniwersytet Jagielloński
 — *Collegium Medicum*
 Oddział Kliniczny Onkologii,
 Szpital Uniwersytecki w Krakowie
 ul. Śniadeckich 10, 31–531 Kraków
 e-mail: lukasz.kwinta@uj.edu.pl

Oncology in Clinical Practice
 2020, Vol. 16, No. 1, 9–13
 DOI: 10.5603/OCP.2019.0035

Translation: dr n. med. Dariusz Stencel
 Copyright © 2020 Via Medica
 ISSN 2450–1654

ABSTRACT

Haematological toxicity of chemotherapy is a very important problem in oncology. The introduction of granulocyte colony-stimulating factor (G-CSF) into clinical practice is one of the most important breakthrough moments in supportive care. The use of G-CSF allows to reduce the risk of febrile neutropenia and maintain the intensity of oncological treatment, so increases not only the safety, but also the effectiveness of cancer therapy. The application of biosimilars, including biosimilar filgrastim and pegfilgrastim, was another important step that made it possible to increase access to modern biological medicines.

Key words: neutropenia, febrile neutropenia, short-acting granulocyte colony-stimulating factors, long-acting granulocyte colony-stimulating factors, biosimilars

Oncol Clin Pract 2020; 16, 1: 9–13

Introduction

Haematological toxicity remains one of the most common side-effects of chemotherapy. Neutropaenic fever as a potentially fatal complication is still a very significant problem in cancer patients. The introduction of filgrastim into clinical practice (followed by long-acting granulocyte colony-stimulating factors [G-CSFs]) was one of the most important breakthroughs in oncological supportive care and gave oncologists a tool with which to use systemic treatment safely and more effectively. The introduction of biosimilars, including bioequivalent filgrastim and pegfilgrastim, was another important step that increased the availability of modern biological drugs.

G-CSF in the prevention of neutropaenic fever

Granulocyte colony-stimulating factor (G-CSF) is a natural cytokine that stimulates haematopoietic progenitor cells, leading to increased production and release of neutrophils from the bone marrow and prolonging their survival. The history of clinical studies assessing the activity and safety of filgrastim in cancer patients receiving chemotherapy dates back to 1988 [1]. The main indication for the use of G-CSF preparations is prevention of neutropaenic fever. It is recommended that G-CSF be used for primary prevention in situations where the risk of neutropaenic fever is 20% or higher. This recommendation appears in both national (Polish

Society of Clinical Oncology [2]) and international guidelines, including ESMO (European Society of Medical Oncology [3]), ASCO (American Society of Clinical Oncology [4]), and NCCN (National Comprehensive Cancer Network) [5]. The basic determinant of risk level is the chemotherapy regimen used. When chemotherapy regimens with a 10–20% risk of neutropaenic fever are used, G-CSF in primary prevention may be considered in the presence of other factors predisposing to this complication, which are:

- age \geq 65 years;
- advanced cancer;
- an earlier episode of neutropaenic fever;
- impaired general condition (ECOG \geq 2);
- impaired nutritional status (albumin $<$ 35 g/L);
- concomitant diseases (the risk increases with the number of diseases), in particular cardiovascular diseases;
- response to treatment (the highest risk in patients who did not experience disease remission, the lowest risk if complete response is achieved);
- inflammation of mucous membranes (mucositis) lining the mouth and/or gastrointestinal tract (severity and duration of mucositis impact the risk).

Secondary prophylaxis (after a previous episode of neutropaenic fever) includes the prevention of subsequent episodes as well as a reduction in the time of neutropaenia, which may affect the delay of subsequent chemotherapy cycles. Secondary prophylaxis should be considered, especially if delayed systemic treatment or dose reduction might have a significant impact on the effectiveness of treatment. This situation primarily concerns radical treatment, where maintaining the right dose intensity can affect the probability of cure. Obviously, this does not exclude the use of G-CSF in secondary prevention in patients undergoing palliative treatment. Each decision should be individualised and analysed in the context of a specific clinical situation.

There are a number of clinical studies and several meta-analyses as well as systematic reviews summarising the benefits of using G-CSF in the prevention of neutropaenic fever. The meta-analysis by Kuderer et al. summarised the results of 17 randomised clinical trials (including one assessing the effectiveness of pegylated form), which involved in total 3493 patients. The analysis showed a significant reduction in the risk of neutropaenic fever (RR 0.538, 95% CI 0.430–0.673), infection-related mortality (RR 0.552, 95% CI 0.338–0.902), and early mortality for any reason during chemotherapy (RR 0.599, 95% CI 0.433–0.830). In the group of patients receiving prophylactic G-CSF, it was possible to maintain the assumed dose intensity on average 95.1% (range 71.0–95.0%), while among patients receiving placebo it was 86.7% (91.0–99.0%). This difference was statistically significant ($p < 0.001$) [6].

Another meta-analysis published in 2005 by Clark et al. Included 13 studies (1569 patients). It showed shortening of hospitalisation among patients receiving primary G-CSF prophylaxis (HR 0.63, 95% CI 0.49–0.82, $p = 0.0006$) and shortening of the time to return neutrophil levels to their baseline (HR 0.32, 95% CI 0.23–0.46, $p < 0.0001$). There was a boundary statistical significance regarding risk reduction of infection-related death (OR 0.51, 95% CI 0.26–1.00, $p = 0.05$) and a statistically insignificant reduction in overall mortality (OR 0.68, 95% CI 0.43–1.08, $p = 0.1$) [7].

Long-acting G-CSFs

Given the short half-life of filgrastim and the associated necessity of daily administration, attempts have been made to chemically modify the molecule to extend the elimination time.

Pegfilgrastim is a modified filgrastim molecule. The modification involves the binding of polyethylene glycol (PEG) to the filgrastim molecule at the N-terminus of the polypeptide chain. Modification of the molecule does not affect the interaction with G-CSF receptor and the biological function of the drug. Considering the size of the PEG component (approx. 20 kDa), the drug is practically not subject to renal clearance. Elimination is mainly based on neutrophil clearance (it involves internalising the drug after binding to the G-CSF receptor) [8]. This mechanism is specifically self-regulated; the serum concentration of the drug decreases more slowly during the nadir, while the elimination of the drug is accelerated during the period of increase in neutrophil levels. The bioavailability of the drug is 60–70%. After subcutaneous administration, it is slowly absorbed, and the maximum drug concentration occurs after 1–2 days. Due to the half-life (approx. 15–80 hours vs. 110 minutes for filgrastim), a single drug administration does not have to be repeated in the following days and constitutes full treatment for one cycle of chemotherapy.

Pegfilgrastim was registered by the FDA (Food and Drug Administration) and EMA (European Medicines Agency) in 2002. The drug was the subject of two pivotal phase III studies in which the effectiveness of a single dose of pegfilgrastim was compared with repeated daily administration of filgrastim. In the first study, a group of 310 breast cancer patients receiving chemotherapy based on doxorubicin and docetaxel were analysed. There were no significant differences in reducing the duration of neutropaenia (1.7 days for pegfilgrastim and 1.8 days for filgrastim), while the incidence of neutropaenic fever was lower in the pegfilgrastim group (9% and 18%, respectively) [9]. In the second of these studies, a group of 157 patients receiving a similar chemotherapy regi-

men (doxorubicin with docetaxel) was analysed. Similar duration of grade 4 neutropaenia was observed in both arms (1.8 and 1.6 days), while the incidence of febrile neutropaenia was 13% and 20%, respectively [10]. In a study by Vogel et al. the effectiveness of pegfilgrastim prophylaxis was compared with placebo in a group of 928 patients treated with docetaxel alone. The drug was significantly more effective in the analysis of endpoints such as the frequency of neutropaenic fever (1% vs. 17%, $p < 0.001$), the frequency of hospitalisations associated with neutropaenic fever (1% vs. 14%, $p < 0.001$), and the use of intravenous antibiotics (2% vs. 10%, $p < 0.001$) [11].

Another long-acting form of G-CSF (registered in the European Union but not in the US) is lipegfilgrastim, in which the filgrastim molecule undergoes modification involving binding to methoxypolyethylene glycol via a carbohydrate linker (glycopegylated form of filgrastim). The effectiveness of lipegfilgrastim was assessed in two pivotal phase III studies. In the first study (XM22-03) the drug was used in the prophylaxis of neutropaenia in 202 breast cancer patients undergoing chemotherapy with doxorubicin and docetaxel. There were no significant differences in the incidence of severe neutropaenia ($ANC < 0.5 \times 10^9/L$) and the duration of neutropaenia both in the first and subsequent treatment cycles [12]. Another study (XM22-04) compared the effectiveness of prophylactic lipegfilgrastim with placebo. The study included 375 patients with non-small cell lung cancer receiving chemotherapy according to the EP regimen. The primary endpoint, a statistically significant reduction in the frequency of neutropaenic fever after the first cycle of chemotherapy, was not achieved. The study, however, showed greater effectiveness of the drug in reducing the duration of deep neutropaenia and the depth of nadir [13].

Comparison of effectiveness between short- and long-acting drugs

A number of studies have been published comparing the efficacy of short- and long-acting G-CSF preparations. Available data are conflicting; although some results indicate higher effectiveness of pegfilgrastim, others do not confirm this observation. A meta-analysis by Pinto et al. was aimed at a comparison of the effectiveness of a single dose of pegfilgrastim with the daily dosage of filgrastim (the number of filgrastim doses per chemotherapy cycle was 10–14). Five clinical trials were included in the analysis, in which 617 patients participated. Analysis showed a higher efficacy of pegfilgrastim in the prevention of neutropaenic fever (RR 0.64, 95% CI 0.43–0.97) [14]. Another meta-analysis (Cooper et al.) showed similar results; it evaluated the effectiveness of G-CSFs in patients undergoing chemotherapy for

solid and haematological cancers. In total, 20 studies comparing the effectiveness of primary prevention with a lack of prevention were included in this meta-analysis ($n = 4710$). The meta-analysis showed a statistically significant 49% reduction (95% CI 0.41–0.62) of the relative risk of neutropaenic fever, with relative risk 0.57 (0.48–0.69) for filgrastim and 0.30 for pegfilgrastim (0.14–0.65). In some studies (5) included in the analysis, the effectiveness of pegfilgrastim and filgrastim was compared, which in a combined analysis led to a statistically significant difference in favour of its long-acting form (HR 0.66, 95% CI 0.44–0.98) [15]. In turn, a meta-analysis by Cornes et al. showed no significant difference in preventing febrile neutropaenia between long- and short-acting drugs (although numerically it was a small difference in favour of long-acting molecules [RR 0.86, 95% CI 0.68–1.10]), while it indicated an advantage of long-acting drugs both in preventing the reduction of cytotoxic drug dosage (RR 0.69, 95% CI 0.57–0.83) as well as delays in their administration (RR 0.70, 95% CI 0.62–0.79) [16]. It is difficult to say unequivocally whether these differences are due to the actual higher efficacy of long-acting forms of G-CSF or rather to the use of an overly low total dose of short-acting drugs (it is estimated that a single administration of pegfilgrastim 6 mg is equivalent to 11 administrations of filgrastim [17, 18]). The latter scenario seems more likely.

Adverse events

The most common side effects related to the use of filgrastim (including long-acting forms) are transient flu-like symptoms (osteoarticular and muscle pain, occurrence of low-grade fever, less often fever). These symptoms are usually mild to moderate and resolve without intervention. They can be relieved with the use of painkillers and anti-inflammatory drugs. In the meta-analysis by Kuderer et al. the aforementioned symptoms were reported in 10.4% of patients in the control group (receiving placebo) and in 19.6% of patients in the group receiving G-CSF (RR 4.023, 95% CI 2.156–7.52) [6]. In turn, one of the parameters assessed in the previously mentioned meta-analysis by Pinto et al. was the difference in the frequency of flu-like symptoms among patients receiving short- and long-acting forms of G-CSF. This analysis showed no statistically significant differences between pegfilgrastim and filgrastim with respect to this parameter (RR 0.95, 95% CI 0.76–1.19) [14].

Secondary cancers

There are reports indicating a relationship between the use of G-CSF and an increased risk of secondary

cancers: acute myeloid leukaemia (AML) or myelodysplastic syndrome (MDS). A meta-analysis by Lyman et al. in 2018 included 68 clinical trials comparing the effects of using filgrastim with no G-CSF supportive treatment. An increased risk of secondary cancers (AML, MDS) was shown in patients receiving G-CSF (RR 1.85, 95% CI 1.19–2.88). However, the use of G-CSF translated into an extension of overall survival for the entire analysed population (RR 0.92, 95% CI 0.90–0.95). An even greater benefit was found in the group of patients receiving dose-dense regimens (RR 0.86, 95% CI 0.80–0.92) [19]. The authors highlighted that the risk of secondary cancer induced by cytostatics exceeds the values found for G-CSF, and the potential risk is balanced by improved survival (probably resulting from maintaining higher intensity of cytostatics doses among patients receiving G-CSF).

Biosimilars

G-CSF preparations belong to the group of biological drugs (biopharmaceuticals) manufactured with the use of biotechnology. The main difference between biopharmaceuticals and “classic” drugs is the way they are produced. Biopharmaceuticals are most often macromolecular proteins of high complexity and complicated spatial structure. They are produced in bioreactors by genetically modified organisms or cell lines, e.g. *Escherichia coli* (like G-CSF), yeast *Saccharomyces cerevisiae*, or modified mammalian cell lines (e.g. Chinese hamster ovary [CHO] cells).

As in the case of small molecules, the expiry of the patent protection for innovative biotechnological drugs gives the possibility to market of their counterparts — biosimilars. With respect to classic small molecule drugs that are products of chemical synthesis, the situation is definitely easier because the generic drugs are the molecules with identical structure and properties. Considering the production method, the situation is much more complicated for biopharmaceuticals and biosimilars. Therefore, the registration requirements set by authorities for manufacturers of biosimilars are more complex than for generic medicines.

The first biosimilar preparations of filgrastim (bioequivalent to the reference drug Neupogen®) were registered by the European Medicines Agency in 2008 and found a permanent place in everyday clinical practice. There are currently seven biosimilar filgrastim preparations registered in Europe (Accofil®, Filgrastim Hexal®, Grastofil®, Nivesitim®, Ratiograstim®, Tevagrastim®, and Zarzio®).

A completely new phenomenon is the appearance of biosimilar preparations of pegfilgrastim (the original drug Neulasta®). The first drugs were registered in Europe in September 2018. Currently, six drugs from this group are registered (Fulphila®, Grasustek®, Pelgraz®,

Pelmeg®, Udenyca®, and Ziextenzo®). Some of these drugs were registered on the basis of studies involving healthy volunteers. However, there are four phase III studies assessing the efficacy and safety (bioequivalence) of pegfilgrastim biosimilars in the population of patients treated with cytostatics due to breast cancer.

The biosimilar drug MYL-1401H (Fulphila®) was evaluated in a phase III study of breast cancer patients receiving combination chemotherapy (docetaxel, doxorubicin, and cyclophosphamide) in the first-line treatment. Patients were randomly assigned in a 2:1 ratio to study arms (MYL-1401H vs. the reference drug Neulasta®). There were no significant differences in the primary endpoint (mean duration of neutropenia $< 0.5 \times 10^9/L$ after the first chemotherapy cycle), which was 1.2 days (± 0.93) and 1.2 days (± 1.10), respectively. The analysis of secondary endpoints (including the frequency of adverse events) also showed bioequivalence of both drugs [20].

The bioequivalence of Grasustek® (RGB-02) was evaluated in a randomised, double-blind phase III study in a group of 239 breast cancer patients receiving chemotherapy based on doxorubicin and docetaxel. The efficacy of the study drug was compared with the reference drug (Neulasta®), and patients were assigned to both arms in a 1:1 ratio. There were no differences in the primary endpoint, which was the duration of neutropenia $< 0.5 \times 10^9/L$ after the first treatment cycle (1.7 vs. 1.6 days). Similarly, no statistically significant differences were found in the secondary endpoints (e.g. duration of neutropenia after subsequent treatment cycles and frequency of neutropaenic fever) [21].

Ziextenzo® (LA-EP2006) was evaluated in two phase III studies: PROTECT-1 and PROTECT-2 [22, 23]. Both studies showed bioequivalence to the reference drug (Neulasta®). Furthermore, Blackwell et al. published a pooled analysis of both studies confirming the conclusions of each of them. Both studies included 624 breast cancer patients receiving neoadjuvant or adjuvant chemotherapy according to the TAC regimen (docetaxel, doxorubicin, and cyclophosphamide). Patients were randomised in a 1:1 ratio. Regarding the primary endpoint (duration of neutropenia $< 0.5 \times 10^9/L$ after the first treatment cycle), there were no significant differences between the two drugs (1.05 ± 1.055 days for LA-EP2006 and 1.01 ± 0.958 days for Neulasta®). Bioequivalence was also demonstrated in the analysis of secondary endpoints (regarding both efficacy and safety in the first and subsequent chemotherapy cycles) [24].

Conclusions

The use of G-CSF allows the reduction of the risk of neutropaenic fever, as well as maintenance of the intensity of treatment by sustaining scheduled chemo-

therapy, which directly affects not only the safety but also the effectiveness of cancer therapy. The high cost of biopharmaceuticals has become one of the drivers of the biosimilar drug industry. As in the case of “classic” drugs, where the introduction of generic preparations has reduced their prices, biosimilars have decreased the cost of cancer treatment using biopharmaceuticals. As a result, it has increased the availability of modern biological medicines obtained thanks to innovative technologies.

References

- Morstyn G, Campbell L, Souza LM, et al. Effect of granulocyte colony stimulating factor on neutropenia induced by cytotoxic chemotherapy. *Lancet*. 1988; 1(8587): 667–672, doi: [10.1016/s0140-6736\(88\)91475-4](https://doi.org/10.1016/s0140-6736(88)91475-4), indexed in Pubmed: [2895212](https://pubmed.ncbi.nlm.nih.gov/2895212/).
- http://onkologia.zalecenia.med.pl/pdf/zalecenia_PTOK_tom1_16_Leczenie_wspomagajace_20150226.pdf (dostęp 28.06.2019).
- Klastersky J, de Na, Rolston K, et al. Management of febrile neutropenia: ESMO Clinical Practice Guidelines. *Ann Oncol*. 2016; 27: v111–v118.
- Smith TJ, Bohlke K, Lyman GH, et al. American Society of Clinical Oncology. Recommendations for the Use of WBC Growth Factors: American Society of Clinical Oncology Clinical Practice Guideline Update. *J Clin Oncol*. 2015; 33(28): 3199–3212, doi: [10.1200/JCO.2015.62.3488](https://doi.org/10.1200/JCO.2015.62.3488), indexed in Pubmed: [26169616](https://pubmed.ncbi.nlm.nih.gov/26169616/).
- <https://www.nccn.org> (dostęp 28.06.2019).
- Kuderer NM, Dale DC, Crawford J, et al. Impact of primary prophylaxis with granulocyte colony-stimulating factor on febrile neutropenia and mortality in adult cancer patients receiving chemotherapy: a systematic review. *J Clin Oncol*. 2007; 25(21): 3158–3167, doi: [10.1200/JCO.2006.08.8823](https://doi.org/10.1200/JCO.2006.08.8823), indexed in Pubmed: [17634496](https://pubmed.ncbi.nlm.nih.gov/17634496/).
- Clark OAC, Lyman GH, Castro AA, et al. Colony-stimulating factors for chemotherapy-induced febrile neutropenia: a meta-analysis of randomized controlled trials. *J Clin Oncol*. 2005; 23(18): 4198–4214, doi: [10.1200/JCO.2005.05.645](https://doi.org/10.1200/JCO.2005.05.645), indexed in Pubmed: [15961767](https://pubmed.ncbi.nlm.nih.gov/15961767/).
- Yang BB, Kido A. Pharmacokinetics and pharmacodynamics of pegfilgrastim. *Clin Pharmacokinet*. 2011; 50(5): 295–306, doi: [10.2165/11586040-000000000-00000](https://doi.org/10.2165/11586040-000000000-00000), indexed in Pubmed: [21456630](https://pubmed.ncbi.nlm.nih.gov/21456630/).
- Holmes FA, O’Shaughnessy JA, Vukelja S, et al. Blinded, randomized, multicenter study to evaluate single administration pegfilgrastim once per cycle versus daily filgrastim as an adjunct to chemotherapy in patients with high-risk stage II or stage III/IV breast cancer. *J Clin Oncol*. 2002; 20(3): 727–731, doi: [10.1200/JCO.2002.20.3.727](https://doi.org/10.1200/JCO.2002.20.3.727), indexed in Pubmed: [11821454](https://pubmed.ncbi.nlm.nih.gov/11821454/).
- Green MD, Koelbl H, Baselga J, et al. International Pegfilgrastim 749 Study Group. A randomized double-blind multicenter phase III study of fixed-dose single-administration pegfilgrastim versus daily filgrastim in patients receiving myelosuppressive chemotherapy. *Ann Oncol*. 2003; 14(1): 29–35, doi: [10.1093/annonc/mdg019](https://doi.org/10.1093/annonc/mdg019), indexed in Pubmed: [12488289](https://pubmed.ncbi.nlm.nih.gov/12488289/).
- Vogel CL, Wojtukiewicz MZ, Carroll RR, et al. First and subsequent cycle use of pegfilgrastim prevents febrile neutropenia in patients with breast cancer: a multicenter, double-blind, placebo-controlled phase III study. *J Clin Oncol*. 2005; 23(6): 1178–1184, doi: [10.1200/JCO.2005.09.102](https://doi.org/10.1200/JCO.2005.09.102), indexed in Pubmed: [15718314](https://pubmed.ncbi.nlm.nih.gov/15718314/).
- Bondarenko I, Gladkov OA, Elsaesser R, et al. Efficacy and safety of lipegfilgrastim versus pegfilgrastim: a randomized, multicenter, active-control phase 3 trial in patients with breast cancer receiving doxorubicin/docetaxel chemotherapy. *BMC Cancer*. 2013; 13: 386–397, doi: [10.1186/1471-2407-13-386](https://doi.org/10.1186/1471-2407-13-386), indexed in Pubmed: [23945072](https://pubmed.ncbi.nlm.nih.gov/23945072/).
- Volovat C, Bondarenko IM, Gladkov OA, et al. Phase III, randomized, double-blind, placebo-controlled, multicenter study of lipegfilgrastim in patients with non-small cell lung cancer receiving myelosuppressive therapy. *SpringerPlus*. 2015; 4: 316–326, doi: [10.1186/s40064-015-1067-7](https://doi.org/10.1186/s40064-015-1067-7), indexed in Pubmed: [26155455](https://pubmed.ncbi.nlm.nih.gov/26155455/).
- Pinto L, Liu Z, Doan Q, et al. Comparison of pegfilgrastim with filgrastim on febrile neutropenia, grade IV neutropenia and bone pain: a meta-analysis of randomized controlled trials. *Curr Med Res Opin*. 2007; 23(9): 2283–2295, doi: [10.1185/030079907X219599](https://doi.org/10.1185/030079907X219599), indexed in Pubmed: [17697451](https://pubmed.ncbi.nlm.nih.gov/17697451/).
- Cooper KL, Madan J, Whyte S, et al. Granulocyte colony-stimulating factors for febrile neutropenia prophylaxis following chemotherapy: systematic review and meta-analysis. *BMC Cancer*. 2011; 11: 404–504, doi: [10.1186/1471-2407-11-404](https://doi.org/10.1186/1471-2407-11-404), indexed in Pubmed: [21943360](https://pubmed.ncbi.nlm.nih.gov/21943360/).
- Comes P, Gascon P, Chan S, et al. Systematic review and meta-analysis of short- versus long-acting granulocyte colony-stimulating factors for reduction of chemotherapy-induced febrile neutropenia. *Adv Ther*. 2018; 35(11): 1816–1829, doi: [10.1007/s12325-018-0798-6](https://doi.org/10.1007/s12325-018-0798-6), indexed in Pubmed: [30298233](https://pubmed.ncbi.nlm.nih.gov/30298233/).
- Aapro M, Boccia R, Leonard R, et al. Refining the role of pegfilgrastim (a long-acting G-CSF) for prevention of chemotherapy-induced febrile neutropenia: consensus guidance recommendations. *Support Care Cancer*. 2017; 25(11): 3295–3304, doi: [10.1007/s00520-017-3842-1](https://doi.org/10.1007/s00520-017-3842-1), indexed in Pubmed: [28842778](https://pubmed.ncbi.nlm.nih.gov/28842778/).
- Sienna S, Piccart MJ, Holmes FA, et al. A combined analysis of two pivotal randomized trials of a single dose of pegfilgrastim per chemotherapy cycle and daily Filgrastim in patients with stage II–IV breast cancer. *Oncol Rep*. 2003; 10(3): 715–724, indexed in Pubmed: [12684649](https://pubmed.ncbi.nlm.nih.gov/12684649/).
- Lyman GH, Yau L, Nakov R, et al. Overall survival and risk of second malignancies with cancer chemotherapy and G-CSF support. *Ann Oncol*. 2018; 29(9): 1903–1910, doi: [10.1093/annonc/mdy311](https://doi.org/10.1093/annonc/mdy311), indexed in Pubmed: [30099478](https://pubmed.ncbi.nlm.nih.gov/30099478/).
- Waller C, Blakeley C, Pennella E, et al. Phase 3 efficacy and safety trial of proposed pegfilgrastim biosimilar MYL-1401H vs EU-Neulasta® in the prophylactic treatment of chemotherapy-induced neutropenia. *Eur J Cancer*. 2017; 72: S42, doi: [10.1016/s0959-8049\(17\)30217-4](https://doi.org/10.1016/s0959-8049(17)30217-4).
- Kahan Z, Grecea D, Smakal M, et al. Efficacy and safety of RGB-02, a pegfilgrastim biosimilar to prevent chemotherapy-induced neutropenia: results of a randomized, double-blind phase III clinical study vs. reference pegfilgrastim in patients with breast cancer receiving chemotherapy. *BMC Cancer*. 2019; 19(1): 122–131, doi: [10.1186/s12885-019-5329-6](https://doi.org/10.1186/s12885-019-5329-6), indexed in Pubmed: [30727980](https://pubmed.ncbi.nlm.nih.gov/30727980/).
- Harbeck N, Lipatov O, Frolova M, et al. Randomized, double-blind study comparing proposed biosimilar LA-EP2006 with reference pegfilgrastim in breast cancer. *Future Oncol*. 2016; 12(11): 1359–1367, doi: [10.2217/fo-2016-0016](https://doi.org/10.2217/fo-2016-0016), indexed in Pubmed: [27020170](https://pubmed.ncbi.nlm.nih.gov/27020170/).
- Blackwell K, Donskih R, Jones CM, et al. A comparison of proposed biosimilar LA-EP2006 and reference pegfilgrastim for the prevention of neutropenia in patients with early-stage breast cancer receiving myelosuppressive adjuvant or neoadjuvant chemotherapy: pegfilgrastim randomized oncology (supportive care) trial to evaluate comparative treatment (PROTECT-2), a phase III, randomized, double-blind trial. *Oncologist*. 2016; 21(7): 789–794, doi: [10.1634/theoncologist.2016-0011](https://doi.org/10.1634/theoncologist.2016-0011), indexed in Pubmed: [27091420](https://pubmed.ncbi.nlm.nih.gov/27091420/).
- Blackwell K, Gascon P, Jones CM, et al. Pooled analysis of two randomized, double-blind trials comparing proposed biosimilar LA-EP2006 with reference pegfilgrastim in breast cancer. *Ann Oncol*. 2017; 28(9): 2272–2277, doi: [10.1093/annonc/mdx303](https://doi.org/10.1093/annonc/mdx303), indexed in Pubmed: [28637287](https://pubmed.ncbi.nlm.nih.gov/28637287/).

Bartłomiej Żerek¹, Wojciech Straś², Piotr Rózga¹, Elżbieta Pękala³

¹Innovation Department Adamed Pharma, Warsaw, Poland

²Commercial Operations Area Adamed Pharma, Warsaw, Poland

³Department of Biochemistry, *Collegium Medicum* of Jagiellonian University, Krakow, Poland

The evolution of biologics in the context of oncological therapy

Address for correspondence:

Mgr Bartłomiej Żerek

Departament Innowacji Adamed Pharma

Warszawa

e-mail: bartlomiej.zerek@adamed.com

Oncology in Clinical Practice

2020, Vol. 16, No. 1, 14–21

DOI: 10.5603/OCP.2020.0001

Copyright © 2020 Via Medica

ISSN 2450–1654

ABSTRACT

Progress in the field of pharmacy, closely related with the mutual stimulation of natural sciences and new technologies available to researchers, has been so rapid over the last few decades that it has begun to cause problems at the level of definitions and classifications. This phenomenon refers also to the term of biologics or, more widely, to biopharmaceuticals (in Polish terminology). The first associations with the above terms lead our thoughts to recombinant proteins, such as insulin used in the treatment of diabetes or monoclonal antibodies with wide, in terms of therapeutic areas, applications. It is generally believed that the above category of drugs is not associated with preparations invented long before the discovery of nucleic acids, let alone before the invention of an ordinary bulb. Importantly, the connotation of the term biopharmaceuticals is undergoing a very rapid reconstruction before our eyes, and the set of referents is expanding with newer, previously unknown types of therapies. Technological progress is one of the driving forces of these changes. Unmet medical needs, including the ones in the area of oncology, constitute another driving force.

Key words: biologics, biopharmaceuticals, recombinant proteins, monoclonal antibodies, CAR-T, gene therapy

Oncol Clin Pract 2020; 16, 1: 14–21

A brief history of biopharmaceuticals

In the broadest sense, the history of biopharmaceuticals, although uncaptured and unclassified as part of meta-science for many years, begins as early as the second half of the 18th century. Its beginning is synonymous with the bold achievements of Edward Jenner, an English physician, who believed in underestimated folk wisdom, according to which the history of cowpox (a contagious viral disease of domestic cattle and pigs) gave immunity to smallpox. Thus, Jenner used material from people infected with animal smallpox to develop the first effective vaccine against deadly smallpox [1]. As a matter of fact, there are reports indicating that the first vaccination was made by a farmer named Jesty, 22 years before Jenner himself. However, it was Jenner who is, due to his striving for the spread of his discovery and his approach based on a scientific method, widely recognised as the inventor and precursor of the application of products of biological origin [2].

Another great breakthrough occurred in the 1940s when the development of technology was driven by the world-engaging war. The needs of the front and the necessity to gain an advantage on it involved huge investments in research based on the observations of Alexander Fleming. Although he discovered bactericidal mould as early as in 1928, the interest in his work first by Ernst Chain and Howard Florey, and later also by Norman Heatley, an English biochemist, came in the late 1930s [3]. After presenting the research results of the team of these scientists at the University of Oxford, American pharmaceutical companies became interested in penicillin. However, after internal evaluation, none of these companies continued studying the issue. It is only the interest from the American War Production Board that changed the course of history. Contracts for mutual exchange of information between Merck, Squibb, Pfizer, Midwest, Abbott Laboratories, Upjohn, Parke, and Davis were signed. The method of production in milk cans was replaced by a large-scale

manufacturing process based on a highly effective fungal strain selected during the development. By the end of 1944, penicillin demonstrated its usefulness in military use, and in March 1945 it entered the domestic and foreign markets [4].

The beginning of the rapid development of biological therapies is, however, associated with a completely different therapeutic area than infectious diseases. It refers to the application of insulin in the therapy of diabetes. Scientific intuition led researchers to discover insulin from the second half of the 19th century, when Paul Langerhans characterised a group of pancreatic cells of distinct structure as compared to the remaining ones. This group was later named the islets of Langerhans, in honour of its discoverer, by Gustaw Laguesse, a French pathologist [5]. Edward Albert Sharpey-Schäfer, an English physiologist, observed afterwards that they produced a substance capable of lowering blood sugar levels. Consequently, in line with the emerging terminology, he used the name applied in 1909 by Jean de Meyer and introduced the term of insulin to medicine (Latin: *Insula* — island). The newly discovered molecule began to gain medical and commercial significance only as a result of the work of scientists from Toronto: Frederick Banting, Charles Best, and James Collip. They developed a method of insulin extraction from the pancreas of animals based on optimised alcohol concentration. Even before clinical trials were completed, Eli Lilly's production facilities started to manufacture the protein, and then to introduce the innovative therapy to the pharmaceutical market in 1922 and revolutionise the approach to diabetes treatment. In the subsequent decades, it was possible to sequence and synthesise insulin, which, combined with the discoveries attributed to Watson and Crick, caused another revolution at the end of the 1970s. In 1978, the company Genentech, originating in California, a pioneer in the field of pharmaceutical biotechnology, in cooperation with the City of Hope National Medical Centre, developed the first insulin using recombinant DNA technology. Thanks to this, as early as in 1982, the above-mentioned Eli Lilly, as a licensee, implemented the first recombinant drug called Humulin, produced in a bacterial expression system, opening a new era in the development of pharmacy [6].

The era of DNA recombination

Almost immediately after insulin, recombinant human growth hormone (Protropin; 1985) and interferon-alpha variants (Roferon A, Intron A; 1986) were introduced. Production of recombinant vaccines was started as well (Recombivax; 1985). The 1980s and 1990s were the times of the so-called first-generation biopharmaceuticals — recombinant proteins identi-

cal in structure to native human proteins, mainly hormones, cytokines, enzymes, growth factors, and blood coagulation factors. In the second half of the 1990s, excluding several previous cases, the so-called second-generation biopharmaceuticals entered the market, i.e. molecules with a modified sequence, exchanged sugar residues, surface modified molecules through a covalent bond with polyethylene glycol, and so-called fusion proteins, being the combination of two or more sequences. The objective of the above variations was to improve efficiency, reduce the number of side effects, and achieve better pharmacokinetic parameters. Exemplary molecules are fast-acting (Humalog; 1996) and long-acting (Lantus; 2000) types of insulin, and pegylated interferons alpha (Peg-Intron; 2000 and Pegasys; 2002). The instances of even more technologically complex solutions include etanercept, i.e. the fusion of the crystallisable fragment (Fc) of the IgG1 antibody (immunoglobulin) with fragments of the tumour necrosis factor (TNF) receptor (Enbrel; 1998) and the fusion of diphtheria toxin with interleukin-2 (IL-2) (Ontak; 1999) [7].

Initially, prokaryotic expression systems based mainly on *E. coli* strains were used to produce biopharmaceuticals based on recombinant DNA technologies. They enabled, in a relatively inexpensive way, the acquisition of so-called high-density cell cultures, from which, after disintegration of bacterial cells, most often using chromatographic techniques, the target therapeutic proteins were purified. Although the *E. coli* system has been successfully applied to produce numerous molecules to this day, over the years, with the increase in complexity of the drug structure (molecular weight, post-translational modifications, complex fusions) and attempts to eliminate the problem of immunogenicity, more demanding methods in the form of the eukaryotic expression systems have started to be used. These were strains of *S. cerevisiae* (e.g. lutropin — Luveris), BHK cell lines, i.e. Baby Hamster Kidney (e.g. blood coagulation factor VIII — Kogenate), and, above all, CHO cell lines, i.e. Chinese Hamster Ovary, which is of utmost significance for development of antibody production methods (few examples of mAbs molecules are based on the hybridoma system).

Thus, progress in molecular biology and biotechnology generated over 200 biologics by 2015. Their sales reached an incredible value of 196 billion USD in 2015, which accounted for 29% of the market for all drugs. This value exceeded the estimates of market analysts — in the report '*Global Protein Therapeutics Market Forecast to 2015*' published in 2012 by RNCOS, it was estimated that the biopharmaceuticals market would reach 143 billion USD in 2015 [8]. *Kelly Scientific Research* estimates from 2015 point to further increases

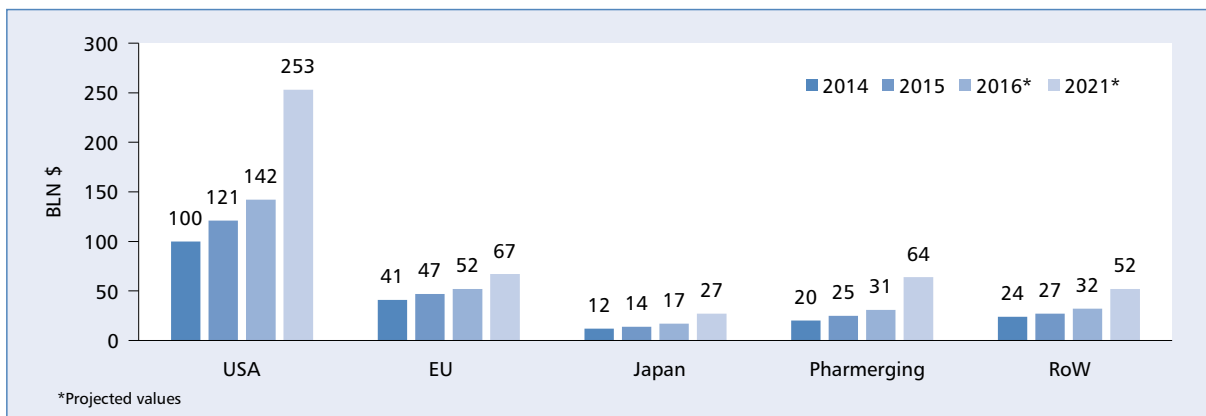


Figure 1. Value of the market of biologics in particular regions (based on [9])

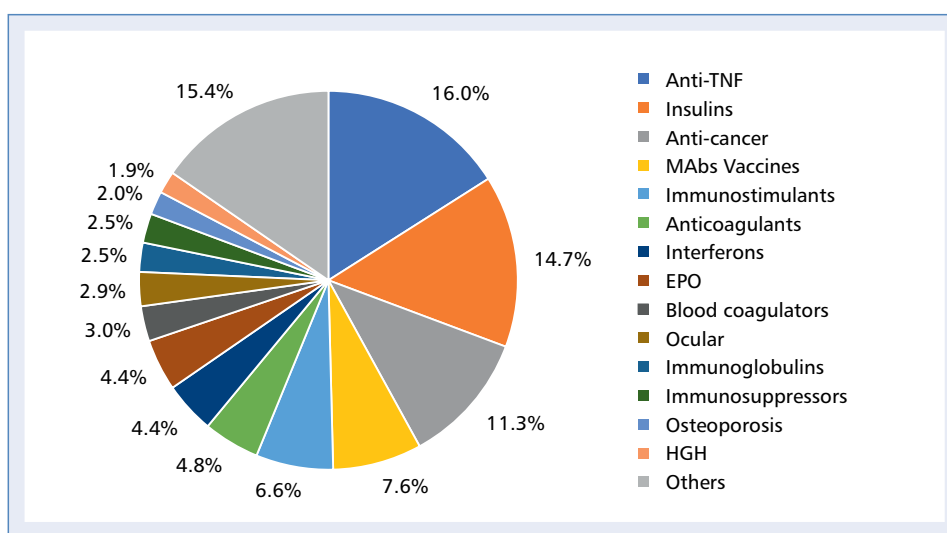


Figure 2. Structure of the market of biologics by therapeutic areas (based on [10])

— the value of the biological drug market is expected to reach 463 billion USD in 2021, accounting for 32% of the entire drug market (Fig. 1) [9]. Importantly, at the end of 2015, over 900 new biopharmaceuticals in the form of protein molecules and antibodies, cellular therapies, as well as gene and antisense therapies were under development. Over 5000 subsequent projects were subject to early laboratory evaluations at that time. It cannot be disputed that the discussed field is still developing very rapidly. However, biologics have already found their application in many therapeutic areas and individual indications, including the following: diabetes, neutropaenia, thrombocytopaenia, anaemia, hepatitis, growth deficiency, myocardial infarction and heart failure, strokes, and a number of autoimmune diseases. Their application in cancer treatment is also growing (Fig. 2).

Definition of biopharmaceuticals as well as benefits and problems associated with their use

According to the FDA, biopharmaceuticals (biologics, biopharmaceuticals, biological medical products) are products generated by and isolated from living organisms. They can be of natural origin (human, animal, or microorganism) or produced with the application of biotechnological methods. They include the following: vaccines, blood components, tissues, cells, gene therapies, and therapeutic proteins (including antibodies). They can have a structure based on proteins and peptides, sugars, nucleic acids, or their complexes or combinations. They can also be living structures, such as tissues and cells. Due to the development of the technology of producing recombinant molecules over the past 30 years, the definition has been reduced

to therapeutic recombinant proteins and monoclonal antibodies. From the point of view of both the system and the physician, as well as the patient, these solutions are not free from defects. The complicated manufacturing process affects both the cost of drug development and the treatment itself. According to data provided by *Kelly Scientific Research*, in 2015 the average cost of the treatment of a patient with biologics was 20–55 times higher than the cost of treatment based on so-called conventional therapy (small chemical molecules) [9]. In addition, biopharmaceuticals, due to lower stability than conventional medicines, usually require compliance with more stringent storage procedures and preparation for administration to the patient. Hospitalisation and observation are more frequently required. However, their market success is not unfounded. In many cases, as a rule, when the molecular target of the drug is a structure that does not require penetration through the cell membrane (most often the surface receptor or its soluble ligand), biologics are the best tool to achieve this goal by eliminating the non-specific interactions that can cause a whole range of adverse effects. These are, by definition, targeted drugs. What is more, due to their natural structure, despite a longer, usually favourable half-life period associated with molecular weight, they are degraded and eliminated from the body without the risk of accumulation and long-term deposition in the body's tissues. Also, they do not penetrate the normal blood-brain barrier. However, the latest scientific knowledge and technology that allows the manipulation of sugar residues in the production process, enable the development of the molecules burdened with the problem of immunogenicity to a significantly lesser extent.

Cytokines and immunotoxins

The first biopharmaceuticals used in oncology were the above-mentioned recombinant variants of alpha interferons. Roferon A and Intron A have been applied in the treatment of specific leukaemias, lymphomas, sarcomas, melanomas, and kidney tumours. By the end of the 1990s, interferons and erythropoietins constituted the largest share of the recombinant drug market. However, over the years, as existing therapies were improved and new therapies were introduced, particularly in well-developed countries, it was not possible to maintain this dominance. As interferons are a group of proteins from the cytokine family involved in numerous processes related to the activation of elements of the immune system, their application is associated with an average number of side effects that are very burdensome for the patient. Thus, despite high dynamics of the entire market and the fact that the market value of interferons alone increased (from 5.7 billion USD in 2002 to

8.6 billion USD in 2009), their total share in the market of biologics is systematically falling. In 2002, it was over 17% [11], in 2009 only 7% [8], and in 2015 less than 5% [10]. These calculations should also take into account the fact that they apply to all interferons (including beta and gamma) and the fact that more than half of the sales of alpha interferons is associated with treatment of viral infections (mainly hepatitis and AIDS). In terms of these indications, subsequent generations of alpha interferons, such as Peg-Intron and Pegasys (pegylated forms of alpha interferons) were developed.

Another example of cytokines in oncological therapy, developed in the 1990s and approved for the first time in 1992, is interleukin-2. A molecule called aldesleukin has found application in the treatment of metastatic kidney cancer and melanoma [12]. Recombinant IL-2 also became part of the structure of a product called Ontak (Denileukin Diftitox) constituting the recombinant fusion of a cytokine with the diphtheria toxin-related domain approved by the FDA in 1999 in the treatment of primary cutaneous lymphomas [13]. The same product was withdrawn by the FDA in 2014.

In the context of attempts to implement the concept as closely as possible to the ideal of targeted therapy, on the wave of achievements in the area of so-called small molecules and development of Gleevec, subsequent research projects were less frequently directed towards non-specific immunotherapy. From the perspective of today's researchers, this approach was relatively brutal. The subsequent programs required both completely different molecular goals and ways of their accomplishment.

Cluster of differentiation

Rituximab was the first representative of the new direction. As part of the mechanism of action of this molecule, the idea of targeting is implemented by using a cluster of differentiation antigens and hits the CD20 present on B lymphocytes. Hence, next to autoimmune diseases, the huge potential of rituximab is noticed in the treatment of non-Hodgkin's lymphoma and lymphocytic leukaemia. What is very important is that structurally this molecule is a monoclonal antibody capable of inducing antibody-dependent cell cytotoxicity (ADCC), due to the presence of the crystallisable fragment (Fc domain) [14]. According to IgeaHub estimates for 2018, the total annual sales value of rituximab (Rituxan and Mabther) was to be about 8.1 billion USD. In 2017, under the name of Biogen and Genentech, Rituxan Hycela with recombinant hyaluronidase enabling rapid subcutaneous administration, reached the market.

At the same time as the first rituximab was under development, cluster of differentiation met with inter-

est from other groups active in the drug discovery field. CD52 was applied as a molecular target for the drug Campath (alemtuzumab) used to treat B-CLL (B-cell chronic lymphocytic leukaemia). It was launched on the market in 2001 [15]. The next examples, however, represent an even higher level of structural engineering. Catumaxomab (Removab), in addition to the CD3 antigen present on T-lymphocytes, binds the EpCAM (epithelial cell adhesion molecule) protein — a molecular target present on the cell surface of many types of neoplasms. Catumaxomab is a trifunctional antibody for which each of the antigen binding fragments (Fab) have an affinity for a different molecular target [16]. Blinatumomab (Blinicyto) constitutes an even more unusual construction. This molecule is a representative of Bi-specific T-cell engagers (BiTE) antibodies and consists of two single-chain variable fragments (scFv) of antibodies linked by a peptide linker. This molecule does not have a crystallisable fragment (Fc) of the antibody. One of the variable fragments is responsible for binding of the CD19 antigen that is subject to expression on the surface of B lymphocytes in acute lymphoblastic leukaemia, and the other for recruitment of T-lymphocytes by direct interaction with the CD3 antigen [17]. An interesting example of attempts to increase the potential of antibodies targeting cell differentiation antigens is the product Adcetris (brentuximab vedotin) manufactured by Seattle Genetics. This drug belongs to the group of ADCs (antibody drug conjugates). It is a monoclonal antibody directed against CD30 (an antigen present on Hodgkin lymphoma cells, cutaneous T-cell lymphoma, and anaplastic lymphoma) conjugated by maleimide with monomethylated auristatin E [18].

Growth factors

Almost in parallel with the concept of molecules targeting clusters of differentiation, attention was paid to the possibility of using monoclonal antibody technology against a completely different group of molecular targets, elements of the growth factor signalling pathways available outside the cell receptors or their ligands. As signal transmitters, these pathways constitute an important stimulus in the emergence and progression of numerous neoplastic diseases. The flagship example of a drug developed in accordance with this concept is Herceptin (trastuzumab) used for 20 years for breast cancer with expression of the gene encoding HER2 (human epidermal growth factor receptor 2). It is a murine humanised antibody directed against HER2 — one of the receptors of the EGFR family (epidermal growth factor receptor). In 2013, a bioconjugate that was structurally based on Herceptin, in which the crystallisable fragment (Fc) of the same antibody was combined with thiol groups with

a small molecule inhibitor of the mitotic cell division, mertansine, was launched on the market. The new ADC is available under the trade name Kadcyla. The activity of the next molecule, which can be used in combination with trastuzumab in breast cancer, is directed to the same HER2 receptor, but to a different epitope. Pertuzumab (Perjeta), first introduced in 2013, blocks a fragment of the HER2 receptor responsible for interaction and dimerisation with HER3, therefore preventing the formation of the most active form of the complex capable of transmitting the pro-survival signal [19]. Other instances of exploration of the EGF family of ligand pathways are cetuximab (Erbix) and panitumumab (Vectibix). Both molecules are anti-EGFR monoclonal antibodies. The first is a chimeric molecule; the other one is fully human. They are applied in metastatic colorectal cancer with overproduction of EGFR and *KRAS* wild type.

An example of implementation of the slightly different strategy for monoclonal antibodies is bevacizumab (Avastin) developed by a team from Napoleon Ferrara. For many years, it was one of the blockbusters among drugs in general. In addition to broad indications in oncology, it is applicable in ophthalmology, in age-related macular degeneration (AMD). Unlike the previously indicated examples, Avastin, according to the postulated mechanism of action, does not target growth factor receptors, but rather their ligands — specifically, vascular endothelial growth factor A (VEGF-A). It was marketed in 2004 as the first angiogenesis inhibitor. It was approved in the treatment of rectal and colorectal cancer, non-small cell lung cancer (NSCLC), kidney cancer, glioblastoma multiforme, and breast cancer. It was withdrawn from the last indication by the FDA in 2010 [20]. Another example of the molecule targeting the VEGF pathway is ramucirumab (Cyramza), a fully human anti-KDR (kinase insert domain receptor) antibody. This quite new angiogenesis inhibitor was approved for the treatment of some gastrointestinal cancers and NSCLC in 2014.

Significantly, two angiogenesis inhibitors applied in oncology have registered indications for treatment of age-related macular degeneration (wet AMD). Bevacizumab and Ziv-Aflibercept (Zaltrap) are present on the market in this way. The second one on the ophthalmic drug market is known as Eylea. It is a fusion protein consisting of the IgG1 Fc domain combined with two soluble receptor fragments. It is a VEGF-Trap type construction, additionally capable of interacting with PGF (placental growth factor). In oncology, Zaltrap is applied to treat metastatic colorectal cancer [21].

Immune checkpoints

A completely new, ground-breaking, and currently intensively explored strategy in oncology is the applica-

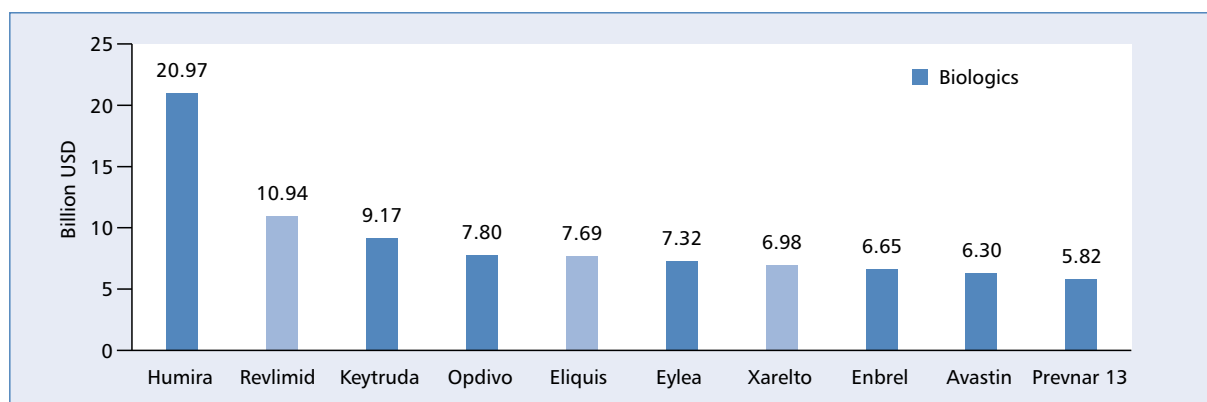


Figure 3. Biologics among the 10 drugs with the highest forecast sales value in 2019 (based on [25])

tion of immune checkpoint inhibitors for therapy. It is thanks to them that the neoplasm, in the development process, creates an immunosuppressive environment around itself in which the immune system becomes inactive towards it. Therefore, blocking the checkpoints by turning off receptors or ligands that negatively regulate immune cell function should, by definition, make the neoplasm visible and vulnerable again [22].

Ipilimumab (Yervoy), which constitutes an antibody directed against CTLA-4 (CD152; cytotoxic T-lymphocyte-associated protein 4), a protein present on the surface of T-lymphocytes, which have been activated by contact with an antigen, is the first recombinant molecule approved in 2011, striking a completely new type of molecular target. Ipilimumab, by blocking CTLA-4, prevents the lymphocytes from transmitting a negative feedback signal by APC (antigen presenting cells), due to which neoplastic cells are not recognised as their own. Thus, lymphocyte deactivation does not occur. Ipilimumab is approved in the treatment of inoperable melanoma and kidney cancer [23].

PD-1 (programmed cell death protein 1) signal inhibitors function on the basis of a simpler mechanism. Nivolumab (Opdivo), pembrolizumab (Keytruda) and cemiplimab (Libtayo) are directed at the PD-1 receptor, present on the surface of the activated lymphocytes. This receptor is responsible for negative regulation of the immune response. Inactivation of the receptor by antibodies prevents recognition of the neoplastic cells as their own, by blocking the interaction with the PD-L1 ligand present on them [24]. By the time cemiplimab was approved in 2018, the other two molecules had already broadened their indications and were intensively conquering the market. As estimated by Evaluate, Keytruda, and Opdivo, sales are expected to reach 9.17 billion USD and 7.8 billion USD, respectively, in 2019 (Fig. 3).

The most intuitive approach in the group of checkpoint inhibitors, based on targeting the neoplasm itself, and not directly the cells of the immune system of the

patient, is represented by atezolizumab (Tecentriq), durvalumab (Imfinzi), and avelumab (Bavencio). These particles are targeted at PD-L1. They prevent its interaction with PD-1 and CD80.

Thus, in just a few years, the market for immune checkpoint inhibitors filled with as many as seven molecules. Subsequent players are forced to make difficult business decisions related to the selection of indications. It should be noted that PD-1 and CTLA-4 are not the only molecular targets under this approach to treatment of neoplasms. May the next molecules based on LAG-3, TIM-3, B7-H3/4, and BTLA signalling constitute another breakthrough.

Table 1 shows selected representatives of various classes of oncological biologics. Figure 4 presents oncological biologics with the highest sales value in 2017.

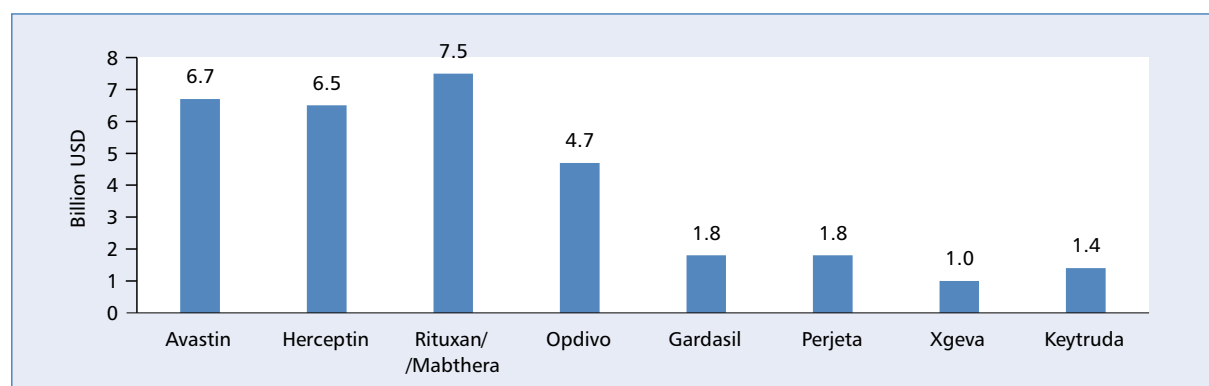
CAR-T and the future of oncological treatment

In 2017, the FDA issued an approval in B lymphoblastic leukaemia derived from B lymphocytes for the first Novartis (Kymriah) therapy based on CAR-T technology. As part of the treatment, the patient's T-lymphocytes are collected and genetically modified so that additional receptors (Chimeric antigen receptors) appear on their surface, in this particular case directed at CD19. Afterwards, the cells return to the patient. In the Evaluate's 2018 report on the list of the most promising research programs, two further CAR-T projects in the Celgene pipeline in the third phase of clinical development are mentioned: bb2121 (anti-BCMA) and JCAR017 (anti-CD19). There are many more similar programs in preclinical development, and the interest in CAR technology is growing [25].

We are certainly at a very interesting point in the history of oncological biologics. The achievements of

Table 1. Selected representatives of specific classes of biologics for cancer treatment in chronological order. Source: Authors' own compilation

First approval	Molecule	Trade name	Structure	Molecular objective	Company
1986	IFN alfa 2a	Roferon A	Rh-interferon alfa 2a	IFN-alfa receptor	Roche
1986	IFN alfa 2b	Intron A	Rh-interferon alfa 2b	IFN-alfa receptor	MSD
1992	Aldesleukin	Proleukin	rIL-2	IL-2 receptor	Chiron/Novartis
1994	Filgrastim	Neupogen	rhG-CSF	G-CSF receptor	Roche
1997	Rituximab	Rituxan	mAb	CD20	Roche
1998	Trastuzumab	Herceptin	mAb	HER2	Roche
1998	Thyreotropin alfa	Thyrogen	rhTSH alfa	TSH receptor	Genzyme
1999	Denileukin diftitox	Ontak	rIL-2-diphtheria toxin	IL-2 receptor, EF-2	Eisai
2001	Alemtuzumab	Campath	mAb	CD52	Bayer
2002	Peg-filgrastim	Neulasta	PEG-rhG-CSF	G-CSF receptor	Amgen
2004	Bevacizumab	Avastin	mAb	VEGF-A	Roche
2004	Cetuximab	Erbix	mAb	EGFR	Merck
2006	Panitumumab	Vectibix	mAb	EGFR	Amgen
2009	Catumaxomab	Removab	mAb	CD3, EpCAM	Fresenius
2011	Ipilimumab	Yervoy	mAb	CTLA-4	Bristol-Myers Squibb
2011	Brentuximab vedotin	Adcetris	ADC	CD30	Seattle Genetics
2012	Ziv-aflibercept	Zaltrap	Fc(IgG1)-VEGF-Trap	VEGF-A, VEGF-B, PGF	Sanofi
2013	Pertuzumab	Perjeta	mAb	HER2	Roche
2013	Trastuzumab emtansine	Kadcyla	ADC	HER2	Roche
2014	Nivolumab	Opdivo	mAb	PD-1	Bristol-Myers Squibb
2014	Pembrolizumab	Keytruda	mAb	PD-1	MSD
2014	Ramucirumab	Cyramza	mAb	VEGFR2	Lilly
2014	Blinatumomab	Blinicyto	BiTE	CD19, CD3	Amgen
2016	Atezolizumab	Tecentriq	mAb	PD-L1	Roche
2017	Durvalumab	Imfinzi	mAb	PD-L1	AstraZeneca
2017	Rituximab hyaluronidase	Rituxan Hycela	mAb + rh-hyaluronidase	CD20	Biogen/Genentech
2017	Avelumab	Bavencio	mAb	PD-L1	Pfizer/Merck
2018	Cemiplimab	Libtayo	mAb	PD-1	Regeneron/Sanofi

**Figure 4. Biologics in oncology with the highest sales value in 2017 (based on [26])**

scientist in recent years have given birth to new drug delivery technologies and have pointed to completely new, previously underestimated or unknown molecular targets. Improvement as part of the development of the so-called 'biobetters' will also apply to already tested drugs. From the point of view of the cost of therapy and availability for the patient, approvals of biosimilar drugs should be important. Unfortunately, in oncology, only three molecules have appeared on the European market: trastuzumab (Ontruzant) from Samsung Bioepis, rituximab (Rixathon) from Sandoz, and rituximab (Truxima) from Celltrion. Thus, the market is still within a very narrow group of manufacturers who care about their interests.

References

- Baxby D. Edward Jenner's Inquiry; a bicentenary analysis. *Vaccine*. 1999; 17(4): 301–307, doi: [10.1016/s0264-410x\(98\)00207-2](https://doi.org/10.1016/s0264-410x(98)00207-2), indexed in Pubmed: [9987167](https://pubmed.ncbi.nlm.nih.gov/9987167/).
- Jesty R. Who invented vaccination? *Malta Medical Journal*. 2011; 23(02): 29–32.
- Jakubiak M. Historia pędzłaka, czyli początek antybiotyków. *Gazeta Lekarska*. 2014; 11(12): 16–18.
- Quinn R. Rethinking antibiotic research and development: World War II and the penicillin collaborative. *Am J Public Health*. 2013; 103(3): 426–434, doi: [10.2105/AJPH.2012.300693](https://doi.org/10.2105/AJPH.2012.300693), indexed in Pubmed: [22698031](https://pubmed.ncbi.nlm.nih.gov/22698031/).
- Bose B, Katikireddy KR, Shenoy PS. Regenerative medicine for diabetes: differentiation of human pluripotent stem cells into functional β -cells in vitro and their proposed journey to clinical translation. *Vitam Horm*. 2014; 95: 223–248, doi: [10.1016/B978-0-12-800174-5.00009-0](https://doi.org/10.1016/B978-0-12-800174-5.00009-0), indexed in Pubmed: [24559920](https://pubmed.ncbi.nlm.nih.gov/24559920/).
- Rosenfeld L. Insulin: discovery and controversy. *Clin Chem*. 2002; 48(12): 2270–2288, indexed in Pubmed: [12446492](https://pubmed.ncbi.nlm.nih.gov/12446492/).
- Jarecka M, Borowicz P. Terapeutyczne i rynkowe perspektywy rekombinowanych leków. *Biotechnologia*. 2005; 4(71): 7–27.
- Global Protein Therapeutics Market Forecast to 2015. RNCOS. 2012.
- Global & USA Biosimilar Market Analysis to 2021. KellySciPub. 2015.
- Perspectives on the evolving biosimilars landscape. IMS Health. 2015.
- The Therapeutic Proteins Outlook to 2007: An Analysis of Leading Products and Late-Stage Pipeline Developments. Research and Markets. 2003.
- Dutcher JP. Current status of interleukin-2 therapy for metastatic renal cell carcinoma and metastatic melanoma. *Oncology (Williston Park)*. 2002; 16(11 Suppl 13): 4–10, indexed in Pubmed: [12469934](https://pubmed.ncbi.nlm.nih.gov/12469934/).
- Kaminetzky D, Hymes KB. Denileukin difitox for the treatment of cutaneous T-cell lymphoma. *Biologics*. 2008; 2(4): 717–724, doi: [10.2147/btt.s3084](https://doi.org/10.2147/btt.s3084), indexed in Pubmed: [19707452](https://pubmed.ncbi.nlm.nih.gov/19707452/).
- Dotan E, Aggarwal C, Smith MR. Impact of rituximab (Rituxan) on the treatment of beta-cell non-Hodgkin's lymphoma. *Pharmacy and Therapeutics*. 2010; 35(3): 148–157, indexed in Pubmed: [20442809](https://pubmed.ncbi.nlm.nih.gov/20442809/).
- Robak T. Alemtuzumab for B-cell chronic lymphocytic leukemia. *Expert Review of Anticancer Therapy*. 2014; 8(7): 1033–1051, doi: [10.1586/14737140.8.7.1033](https://doi.org/10.1586/14737140.8.7.1033).
- Liu H, Saxena A, Sidhu SS, et al. Fc engineering for developing therapeutic bispecific antibodies and novel scaffolds. *Front Immunol*. 2017; 8(38): 1–15, doi: [10.3389/fimmu.2017.00038](https://doi.org/10.3389/fimmu.2017.00038), indexed in Pubmed: [28184223](https://pubmed.ncbi.nlm.nih.gov/28184223/).
- Topp MS, Gökbuğet N, Stein AS, et al. Safety and activity of blinatumomab for adult patients with relapsed or refractory B-precursor acute lymphoblastic leukaemia: a multicentre, single-arm, phase 2 study. *Lancet Oncol*. 2015; 16(1): 57–66, doi: [10.1016/S1470-2045\(14\)71170-2](https://doi.org/10.1016/S1470-2045(14)71170-2), indexed in Pubmed: [25524800](https://pubmed.ncbi.nlm.nih.gov/25524800/).
- Gravanis I, Tzogani K, van Hennik P, et al. The European Medicines Agency Review of Brentuximab Vedotin (Adcetris) for the Treatment of Adult Patients With Relapsed or Refractory CD30+ Hodgkin Lymphoma or Systemic Anaplastic Large Cell Lymphoma: Summary of the Scientific Assessment of the Committee for Medicinal Products for Human Use. *Oncologist*. 2016; 21(1): 102–109, doi: [10.1634/theoncologist.2015-0276](https://doi.org/10.1634/theoncologist.2015-0276), indexed in Pubmed: [26621039](https://pubmed.ncbi.nlm.nih.gov/26621039/).
- Albanell J. Mechanisms of action of the HER dimerization inhibitor pertuzumab alone or with trastuzumab. *Cancer and Chemotherapy Reviews*. 2013; 8(1): 24–32.
- Braghiroli M, Sabbaga J, Hoff PM. Bevacizumab: overview of the literature. *Expert Rev Anticancer Ther*. 2012; 12(5): 567–580, doi: [10.1586/era.12.13](https://doi.org/10.1586/era.12.13), indexed in Pubmed: [22594892](https://pubmed.ncbi.nlm.nih.gov/22594892/).
- Stanel SC, Sjöberg J, Salmonson T, et al. European Medicines Agency approval summary: Zaltrap for the treatment of patients with oxaliplatin-resistant metastatic colorectal cancer. *ESMO Open*. 2017; 2(2): e000190, doi: [10.1136/esmoopen-2017-000190](https://doi.org/10.1136/esmoopen-2017-000190), indexed in Pubmed: [28761750](https://pubmed.ncbi.nlm.nih.gov/28761750/).
- Swatler J, Kozłowska E. Immune checkpoint-targeted cancer immunotherapies. *Postępy Hig Med. Dosw*. 2016; 70: 25–42, doi: [10.5604/17322693.1192926](https://doi.org/10.5604/17322693.1192926).
- Lipson EJ, Drake CG. Ipilimumab: an anti-CTLA-4 antibody for metastatic melanoma. *Clin Cancer Res*. 2011; 17(22): 6958–6962, doi: [10.1158/1078-0432.CCR-11-1595](https://doi.org/10.1158/1078-0432.CCR-11-1595), indexed in Pubmed: [21900389](https://pubmed.ncbi.nlm.nih.gov/21900389/).
- Fessas P, Lee H, Ikemizu S, et al. A molecular and preclinical comparison of the PD-1-targeted T-cell checkpoint inhibitors nivolumab and pembrolizumab. *Semin Oncol*. 2017; 44(2): 136–140, doi: [10.1053/j.seminoncol.2017.06.002](https://doi.org/10.1053/j.seminoncol.2017.06.002), indexed in Pubmed: [28923212](https://pubmed.ncbi.nlm.nih.gov/28923212/).
- Brown A, Gardner J, Elmhirst E. Vantage 2019 Preview. *Evaluate* 2018.
- Top 20 Blockbuster Cancer Drugs. *The Balance*. 2018, <https://www.thebalance.com/top-cancer-drugs-2663234>.

Aleksandra Sobiborowicz^{1, 2} , Anna M. Czarnecka^{1, 3} , Anna Szumera-Ciećkiewicz^{4, 5} ,
Piotr Rutkowski¹ , Tomasz Świtaj¹ 

¹Department of Soft Tissue/Bone, Sarcoma and Melanoma, Maria Skłodowska-Curie National Research Institute of Oncology, Warsaw, Poland

²Medical Faculty, Medical University of Warsaw, Warsaw, Poland

³Department of Experimental Pharmacology, Mossakowski Medical Research Centre, Polish Academy of Sciences Warsaw, Poland

⁴Department of Pathology and Laboratory Diagnostics, Maria Skłodowska-Curie National Research Institute of Oncology, Warsaw, Poland

⁵Department of Diagnostic Hematology, Institute of Hematology and Transfusion Medicine, Warsaw, Poland

Diagnosis and treatment of malignant PEComa tumours

Address for correspondence:

Dr n. med. Tomasz Świtaj
Klinika Nowotworów Tkankę Miękkich,
Kości i Czerniaków
Narodowy Instytut Onkologii
im. Marii Skłodowskiej-Curie
— Państwowy Instytut Badawczy
ul. Roentgena 5, 02-781 Warszawa
Phone: 22 546 20 31, fax: 22 643 93 75
e-mail: tomasz.switaj@coi.pl

ABSTRACT

PEComa (PEC tumours; perivascular epithelioid cell tumours) is a family of rare tumours of mesenchymal origin, consisting of epithelial perivascular cells expressing melanocytic and myoid markers. This group includes benign tumours — such as angiomyolipoma (AML) of the kidney, and poorly differentiated malignant PEComa tumours with potential for an aggressive clinical course, which is the main focus of this review. PEComas are most often diagnosed in middle-aged women as extensive tumours located in the abdominal cavity or pelvis, manifesting as pain and complaints related to pressure on nearby organs. PEComa tumours should be differentiated from gastrointestinal stromal tumours (GIST), leiomyosarcoma, melanoma metastasis, chromophobic renal cell carcinoma, clear cell sarcoma, and other clear cell component tumours. Somatic inactivating mutations within the *TSC1/TSC2* genes, resulting in excessive activation of the mTORC1 complex, are characteristic for this group of tumour. Recently, a separate PEComa subgroup has been distinguished, characterised by the presence of the *TFE3* gene fusion, which also causes increased activity of the mTOR signalling pathway. Negative prognostic factors that indicate an increased risk of PEComa malignant biology are most often: tumour size > 5 cm, increased cytological and nuclear atypia, infiltration of surrounding tissues and blood vessels, presence of necrosis, and high mitotic activity. Radical resection remains the primary treatment method for PEComas because these tumours are characterised by high resistance to radiation and chemotherapy. In the case of locally advanced or metastatic disease, only single reports of short-term responses to palliative chemotherapy containing doxorubicin, gemcitabine, or ifosfamide are available in the literature. There are an increasing number of reports, in the form of several case reports and a few retrospective analyses, about the potential effectiveness of using mTOR inhibitors in unresectable cases. These drugs result in a reduction in primary tumour size and metastasis, as well as symptom relief, with controllable side effects. Unfortunately, case reports of complete resistance to mTOR inhibitor therapy are also available.

Key words: PEComa, perivascular epithelioid cell, mTOR

Oncology in Clinical Practice
2020, Vol. 16, No. 1, 22–33
DOI: 10.5603/OCP.2020.0003
Translation: prof. Ewa Bartnik
Copyright © 2020 Via Medica
ISSN 2450-1654

Oncol Clin Pract 2020; 16, 1: 22–33

Introduction

PEComa (PEC tumours; perivascular epithelioid cell tumours) is a family of rare tumours of mesenchymal origin composed of perivascular epithelioid cells (PEC) [1]. This group includes angiomyolipomas (AML), clear-cell sugar tumours (CCST) — pulmonary and extrapulmonary (PEST, primary extrapulmonary sugar tumour), lymphangioliomyomatosis (LAM), clear-cell

myomelanocytic tumours (CCMMT), and primary cutaneous PEComas (CCCMT, cutaneous clear cell myomelanocytic tumours). PEComa NOS (not otherwise specified) is a joint term for a broad group of tumours with perivascular epithelioid differentiation, not qualifying for the remaining subgroups of the PEComa family (AML, LAM, CCST, CCMMT). According to the WHO classification, in the PEComa NOS both benign PEComa NOS as well as clinically challenging tumours with

a higher degree of malignancy are included (malignant PEComa NOS). A malignant PEComa encountered by clinical oncologists in their practice is abdominopelvic perivascular epithelioid cell sarcoma — the so-called malignant PEComa [2, 3]. In the largest analysis performed so far encompassing 234 PEComa NOS cases described in the literature, epithelioid AML subtypes occurring outside the kidneys were also qualified [3]. In a collective analysis of 100 cases of PEComa-NOS, 38 cases were locally advanced with an infiltration of surrounding organs, and four patients developed metastases — these patients were qualified into the malignant PEComa group (Figure 1) [4]. Altogether fewer than 100 cases of malignant PEComa have been described in the literature [3, 5], and 13 of them concerned changes within bones [6].

Epidemiology

The age of the patients at the time of PEComa diagnosis is most commonly in the range of 38.9–56 years [7, 8], but PEComa cases in children have also been described [9, 10]. All reviews indicate more common PEComa occurrence in women (54–86.9% of cases) [11, 12], also after exclusion of sex-specific locations from the analysis [3].

Anatomical location

Among the most common locations for PEComa development are the uterus, skin, the liver, and the colon [3, 13]. Moreover, large malignant PEComas are diagnosed especially in the extraperitoneal space [14]. Many anatomical locations have been described for PEComas. In a large analysis 24 pancreatic PEComa cases were presented, of which half were localised in the head of the pancreas [12] and numerous PEComas of the digestive tract [11, 15], including the stomach [16], the ileus [17] and the colon [18]. Moreover, single cases in various locations have been described: the greater omentum [19], the gall bladder [20], the common bile duct [21], the breast [22], the thigh bone [6], rib [23], skull base [24], heart [25], pericardium [26], the prostate [27, 28], ovary [29], nasal cavity [30], throat [31], eye socket [10], urinary bladder [32], lung [33], and the groin [34].

Diagnosis

PEComa is quite often (approx. 20% of the cases) diagnosed by chance in an imaging examination performed for other indications [12]. The symptomatic form, most commonly locally advanced, manifests by pain and discomfort in the area of the tumour and by

weight loss [12, 35], and in the case of PEComa localised in the uterus by a bloody discharge [36]. A biopsy is required for the diagnosis.

Metastases are most commonly described in the lungs — cases of pneumothorax caused by tumour infiltration [37], and in the liver and bones. Metastases to the extraperitoneal space have also been described as well as the central nervous system, ovary, adrenal glands, peritoneum, intestinal wall, skin, stomach, and lymph nodes [3, 4, 35, 37, 38]. For this reason, the diagnosis of malignant PEComa requires a complete evaluation of the staging as in the case of other sarcomas [39]. Dissemination in patients with primary tumours in the pelvis or lower limb first takes place to the lung (90%); 77.8% of tumours encompassing the kidneys and the mesentery first metastasise to the liver, and in turn tumours in the adrenal glands and extraperitoneal tissues initially give metastases to the peritoneum and lungs [40]. As metastases often occur after many years and predictive markers for their development are not known, patients after PEComa resection, especially of tumours > 8 cm, require observation for many years after surgical treatment [4]. Metastases in patients with PEComa can develop even up to 10 years after resection of the primary tumour [41].

Pathomorphology

PEC (perivascular epithelioid cells) do not have a corresponding normal cell type and simultaneously express differentiation markers for muscle cells and melanocytes. PEComas are composed of epithelioid and spindle-shaped cells with a light and eosinophilic cytoplasm with a sporadic presence of granularities. Cell nuclei are small and cylindrical; the nucleolus is rarely visible. The cells form nests or bands, often radially surrounding blood vessels [42]. In PEComa cells from the colon obtained by thin needle biopsy the presence of eosinophilic cytoplasmic inclusions has been described [43]. Elongated fusiform cells in PEComas are characterised by distinct fibres specific for smooth muscle, while the epithelioid component in general does not contain a large amount of such fibres. A PEComa may thus be composed of fusiform cells with elongated nuclei and thus present a myoid phenotype, or it may contain cells with a clearly eosinophilic cytoplasm and a more visible epithelioid phenotype; both these types of cells occur next to each other in the tumour (Fig. 1) [4].

In immunohistochemical staining typically co-expression of melanocytic markers is observed:

- HMB-45 in 92–100% [36, 44, 45];
- Melan A/Mart1 in 23–88% [36, 46];
- transcriptional factor MITF; nuclear expression in 50–92% [36, 44];

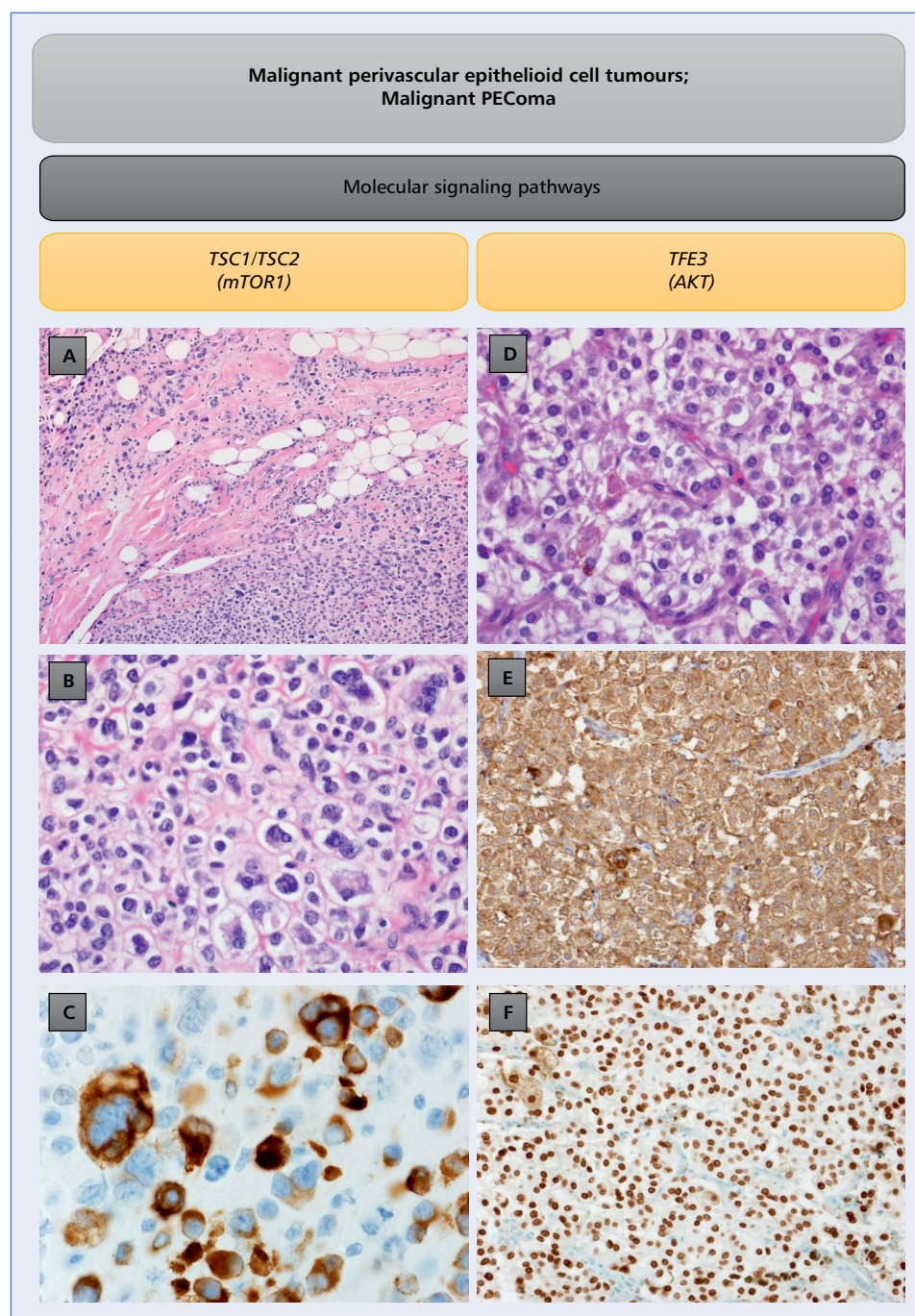


Figure 1. Malignant tumors of the PEComa family. **A.** As per definition, malignant PEComas is characterized by infiltrative growth type (HE, 40×); **B.** In addition, they PEComas characterized by high grade cytological atypia (HE, 400×); **C.** Tumor cells express HMB-45, which, together with SMA and Cathepsin K, are typical immunohistochemical markers (600×); **D.** Malignant PEComa with the presence of cells with pale and granular abundant cytoplasm (HE, 400×); **E.** Strong expression of Cathepsin K (200×); **F.** Strong nuclear expression of TFE3 (200×) — rearrangement of the TFE3 gene confirmed by fluorescence *in situ* hybridization and next generation sequencing

- S100; rare nuclear and cytoplasmic expression in 8–33% [44, 46];
and smooth muscle:
- desmin 36–100% [36, 44];
- smooth muscle actin (SMA) 59–93% [4, 44, 46];
- caldesmon 75–92% [36, 45].

Among additional PEComa markers cathepsin K is mentioned; its expression was observed in all analysed cases [45, 47], and transcriptional factor TFE3 (transcription factor binding to IGHM enhancer 3) was observed in 29–38% of cases regardless of the rearrangement of the *TFE3* gene [36, 44]. PNL2 has been

proposed as a new marker with high sensitivity and specificity in the differentiation of PEComa and AML (expression described in 89% of cases) from other neoplasms derived from kidneys, which do not express this marker [48]. In immunohistochemical analysis PEComas also stain positive for vimentin, CD-31, and CD-34 and are negative for CgA (chromogranin A), Syn (synaptophysin), CK (creatin kinase), CD117, CD10, AFP (alpha-fetoprotein), and EMA (epithelial membrane antigen). There are single reports about positive results of staining for progesterone receptor [49]. Cytoplasmic expression of CD10, a marker used in differential diagnosis of renal cell carcinoma metastases to the skin, has also been detected in skin PEComas [50]. In four cases of malignant-PEComa-NOS formed in the colon, the thigh, elbow, and bladder a strong nuclear overexpression of cyclin D1 was observed [51].

Macroscopically PEComa tumours are pink, yellow-brown, or white in cross section, with a differentiated consistency. In about 20% of cases, bleeding into the tumour or the presence of necrosis are observed [45]. The tumour capsule, typical for sarcomas, is absent, but the tumours are described as well limited from surrounding tissue [11, 35]. PEComa tumours are characterised by a rich vascularisation from branching capillaries to thicker arterioles, often with a hyalinised wall [42]. In 13–19% of PEComa cases an increased hyalinisation of the stroma is observed and the lack of the rich vascularisation typical for classical cases; this

variant has been described as the sclerosing variant [36, 46]. Malignant PEComa is characterised by a high degree of histological malignancy, high cellularity, a high mitotic index ($> 1/50$ HPF), the presence of necrosis, and the possibility of infiltration of surrounding tissues and blood and lymphatic vessels [44].

The basic pathological differential diagnosis for PEComa NOS (summarised in Table 1) encompasses: gastrointestinal stromal tumours (GIST), melanoma, renal cell, and adrenocortical carcinoma, especially the chromophobic type, clear cell sarcoma of tendon and aponeurosis — melanoma of the soft parts (CCS), alveolar soft part sarcoma (ASPS) [8, 52], paraganglioma, angiomyolipoma, and also gynaecological tumours such as endometrial stromal sarcoma with clear cell features or uterine tumour resembling sex cord tumour and other tumours with a clear cell component [4]. It is also important to distinguish them from tumours derived from smooth muscle (epithelioid leiomyosarcoma — LMS and epithelioid leiomyoma).

The diffuse and multimarker expression of proteins of melanocytic differentiation, which does not occur in other sarcomas, is highly indicative for the diagnosis of PEComas. Focal or weakly positive results of staining do not justify a PEComa diagnosis. Diagnosis of an angiomyolipoma can be excluded if neither lipid elements nor a biphasic cell population are present. However, PEComa and a monophasic epithelioid angiomyolipoma are probably very close diagnoses. An endometrial stromal

Table 1. Pathological differential diagnosis of PEComa NOS

Unit	Morphology	Immunohistochemical markers						Other characteristic properties
		HMB-45, Melan A	CD117	S100	CD10	SMA	TFE3	
PEComa	Perivascular proliferation of epithelioid and fusiform cells with light eosinophilic cytoplasm with granularities, nucleoli are visible	+	±	±	±	+	±	
GIST	Epithelioid and fusiform cells with light eosinophilic cytoplasm without granularities	-	+	-	-	-	-	<i>c-kit</i> and <i>PDGFA</i> mutations
Melanoma	Cells of different shapes. No clear nucleoli	+	-	+	-	-	-	<i>BRAF</i> mutations in approx. 50% of patients
Chromophobic RCC	Richly vascularised; epithelioid cells	-	+	-	+	-	-	
CCS	Nests of spherical or epithelioid cells, giant multinuclear cells present	+	-	+	-	-	-	Gene fusions: t(2:22)(q34;q12)(EWS-CREB11) t(12;22)(q13;q13)(EWS-ATF1)
ASPS	Cytoplasmic granularities, no epithelioid cells	-	-	-	-	±	+	Translocations t(X; 17)
LMS	Epithelioid and fusiform cells	-	±	±	+	+	-	

ASPS — alveolar soft part sarcoma; CCS — clear cell sarcoma; GIST — gastrointestinal stromal tumour; RCC — renal cell carcinoma; SMA — smooth muscle actin

sarcoma can be excluded due to the presence of a clear perivascular distribution of tumour cells and a diffuse, and not focal, positive staining HMB-45. PEComa can be distinguished from paraganglioma because the former is negative for staining for chromogranin A, synaptophysin, and protein S100, and the latter more commonly grows in the form of organoids. The expression of melanocyte markers (HMB-45 and MART-1/Melan-A) and the lack of immunoreactivity to cytokeratins and renal cell carcinoma counter a diagnosis of cancer and help to recognise a PEComa [51].

Genetics

In approx. 80% of PEComa cases deletions and/or loss of heterozygosity (LOH) are observed in the 16p13.3 region, at locus *TSC2*, leading to the loss of tuberin activity [7, 53]. Sporadically LOH is observed in the 9q34 region, locus *TSC1*, encoding hamartin [54]. Both proteins participate in forming a complex with GTPase activity, acting as an inhibitor of the mTOR (mTOR/S6K1/4E-BP1) signal pathway. Activation of the mTOR pathway leads to increased proliferation of cells and their differentiation into myocytes. The loss of the function of tuberin and/or hamartin leads to an excessive activity of the mTOR serine/threonine kinase, which is a target for the use of mTOR inhibitors in the therapy of patients with advanced PEComa [55]. These perturbations are often accompanied by mutations of the *TP53* gene, which is described in 63% of the cases in which this was analysed [7].

In spite of the frequent presence of *TSC2* somatic mutations, the occurrence of PEComa NOS/malignant PEComa is less tightly connected to tuberous sclerosis — a genetic syndrome caused by a germ-line mutation inactivating the *TSC1* or *TSC2* genes — in comparison to the remaining tumours from this family, e.g. LAM or AML. In the literature tuberous sclerosis occurred only among 0–6.25% of patients with PEComa [36, 44].

In recent years, taking into consideration molecular investigations, a second form of PEComa, characterised by rearrangements of the *TFE3* gene (Xp11.23) has been distinguished [7]. *TFE3* rearrangements were described earlier in renal cell carcinoma [56] and are also characteristic for alveolar soft part sarcoma [57]. Its product is a transcription factor of the MiTF/TFE family regulating the expression of genes dependent on the signal pathway of transforming growth factor β (TGF- β) [58]. Moreover, TFE3 takes part in the regulation of cellular metabolism via stimulation of lysosome formation and modification of the response to oxidative stress and increasing autophagy processes, resulting in activation of the mTORC1 signal pathway [59, 60]. For PEComa *SFPQ/PSF-TFE3* and *DVL2-TFE3* fusions have been described [7, 61].

TSC2 mutations and *TFE3* gene rearrangements are mutually exclusive [7]. PEComa with a *TFE3* gene rearrangement has been described as differing in morphology, with a preponderance of epithelioid cells with a vesicular architecture and the lack of fusiform cells and no characteristic vascularisation. Lack of expression of smooth muscle actin (SMA) and desmin have also been observed [62]. However, the analysis only encompassed four cases, and in the literature there is also a case of a PEComa with a *TFE3* gene fusion with morphological properties typical for the classical form [42].

Among rare gene rearrangements described in PEComas are two cases of *RAD51B* fusions with *RRAGB/OPHN1* in a uterine PEComa and two cases of *HTR4-ST3GAL1* and *RASSF1-PDZRN3* fusions [7]. One case of malignant PEComa has been described in which next generation sequencing indicated a nonsense mutation (E1413*) in the *ATRX* gene (alpha thalassaemia-mental retardation, X linked) as the only genetic perturbation [63]. The loss of ATRX protein expression had been observed earlier in poorly differentiated soft tissue sarcomas [64] and was correlated with the phenomenon of alternative telomere elongation in leiomyosarcoma [65].

Treatment of locally advanced and metastatic disease

Radical resection is the mainstay of PEComa treatment because these tumours are characterised by resistance to chemotherapy and radiotherapy [3, 66]. In the described cases also the mastectomy of metastatic foci (lung, kidney, liver) permitted long-term control of the disease [4]. Because of the overarching importance of surgical treatment in order to obtain long-term survival, patients with initially recognised advanced disease have unfavourable prognoses because so far the importance and/or significance of adjuvant or neoadjuvant chemotherapeutic treatment has not been proven and it is currently not recommended, with the exception of clinical research protocols and application in reference centres [67]. A response to neoadjuvant stereotactic radiotherapy (SBRT; eight fractions of 7.5 Gy each) has also been observed in the case of a non-resectable liver PEComa. A decrease in the tumour size enabled radical resection, and the patient was disease-free after 21 months [68]. Chemotherapy has also been described as strongly decreasing the vascularisation but not the tumour size for PEComa (ifosfamide + vincristine + dactinomycin), which gives less blood loss during subsequent resection [51]. Three-component chemotherapy (epirubicin with cisplatin and ifosfamide) applied as a neoadjuvant allowed a decrease of tumour mass and resectability of a mass in the pelvis [69].

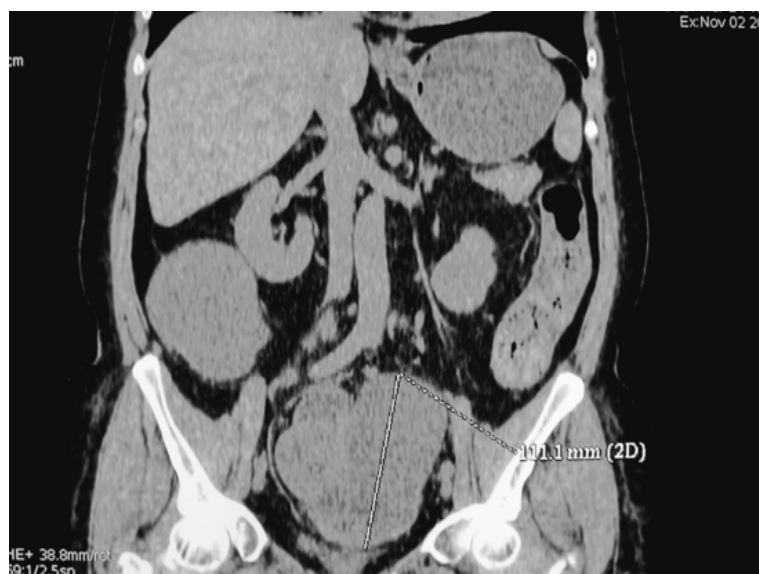


Figure 2. CT scan of PEComa — large pelvic and intraperitoneal tumours

Classical palliative chemotherapy yields few objective responses, although the use of Adriamycin in monotherapy has been described, as well as high dose ifosfamide, gemcitabine with docetaxel, and dacarbazine [67]. In a retrospective analysis of 53 patients with locally advanced or metastatic PEComa, the objective response rate (ORR) to chemotherapy based on gemcitabine or anthracyclines was only obtained in a small percentage of the patients (respectively, ORR = 20% and 13%), and progression-free survival (PFS) was: 3.4 and 3.2 months [70]. Moreover, only single cases of a response to doxorubicin and ifosfamide treatment were observed, e.g. a nine-month stabilisation of the disease obtained in a patient with a colon PEComa with metastases to the liver and a response in the form of a diminished mass of an upper limb PEComa by 80% after six cycles (PR, partial response) [71, 72]. Partial responses (PR) were also noted for dacarbazine treatment, complete responses (CR) for vincristine, and progression when imatinib treatment was used [51].

Because of frequent genetic perturbations causing an increase in the activity of the mTOR signalling pathway, similarly as in other subgroups of this family of tumours, long-term response to treatment with mTOR inhibitors is observed [73]. Benson et al. (from the Royal Marsden Hospital) published a retrospective analysis of mTOR inhibitors in the treatment of advanced PEComas with metastases for 10 cases (eight women, two men, median age 47.5 years). Nine patients received sirolimus (median dose 4 mg/d *p.o.*) and one temsirolimus, at a dose of 25 mg/week intravenously. The reaction was evaluated according RECIST in 7/10 patients, PR was observed in 50% of cases, SD in 10%, and PD in 10%. In the three remaining patients, rapid progression took place in the

first days of the treatment. Among the nine patients receiving sirolimus, the drug dose was decreased in five, and in four the treatment was intermittently stopped because of undesirable effects. Treatment was stopped in seven patients, in six of them because of disease progression. The one-year survival rate was 78.8%, and the survival time median was 2.4 years, with median observation time of 1.9 years [74]. In a retrospective analysis, application of mTOR inhibitors in patients with locally advanced or metastatic PEComa was demonstrated (ORR: 41%, PFS: 9 months), compared to classical chemotherapy based on gemcitabine or anthracyclines (ORR: 20% and 13%, PFS: 3.4 and 3.2 months) [70]. In another analysis encompassing five patients with PEComa metastases in the digestive tract, treated with sirolimus or everolimus, a clinical response was obtained in four (observation period 1 to 47 months), and in one patient progression and death occurred 23 months after diagnosis [11]. The remaining data about the use of mTOR inhibitors in this group of patients are from descriptions of cases. A 20-month disease stabilisation (SD) was observed in a patient with a disseminated form of kidney PEComa treated with sirolimus [75]. The therapy was complicated by strong undesirable effects during the first month of treatment, linked to the level of the drug in the blood of 156.8 ng/ml; this disappeared during five weeks after adjusting the dose. A pancreatic PEComa has been described in which resection was not performed and therapy with sirolimus was introduced, obtaining a partial response, which was maintained for 42 months [76]. A case of a patient with an advanced colon PEComa with metastases to the liver is known — after radical resection he received sirolimus as an adjuvant. In spite of treatment, local relapse occurred

Table 2. Cases of PEComa treated with mTOR inhibitors available in the literature

Author	Sex	Age	Tumour location	Metastases	Drug	Dose	Best outcome	Time to progression (months)	Follow-up (months)	Effect
Wagner et al. [79]	M	65	Extraperitoneal space	Lungs	Sirolimus	8 mg/d	PR	16	16	AWD
	M	70	Kidney	-	Sirolimus	1-4 mg/d	PR	12	12	AWD
	F	61	Uterus	Lungs	Sirolimus; sorafenib + sirolimus	2-8 mg/d	PR	3	7	DOD
Italiano et al. [78]	F	55	Uterus	Lungs, heart, liver	Temsirolimus	25 mg/week IV	PR	5.5	ND	AWD
	F	69	Uterus	Lungs	Neo. temsirolimus, adj. temsirolimus	25 mg/week IV	CR	ND	9	NED
Gennatas et al. [80]	F	63	Extraperitoneal space	Lungs, abdominal cavity	Everolimus	10 mg/d	PR	10	37	AWD
Dickson et al. [81]	F	24	Extraperitoneal space	-	Sirolimus	4 mg/d	CR	NR	22	NED
	F	40	Extraperitoneal space	Pelvic lymph nodes	Sirolimus	3-4 mg/d	CR	NR	16	NED
	M	57	Small intestine	Abdominal cavity	Sirolimus	4 mg/d	PR	NR	14	AWD
	F	37	Liver	-	Neo. everolimus	5 mg/d	PR	NR	6	NED
	M	65	Adrenal glands	Lungs, soft tissues	Sirolimus	1-4 mg/d	SD	ND	36	DOD
Scheppach et al. [72]	M	23	Colon	Liver	Sirolimus	2 mg/d	PD	4	23	DOD
Bergamo et al. [82]	F	31	Liver	-	Neo. sirolimus	2-3 mg/d	PR	NR	10	NED
Nakanishi et al. [83]	F	51	Extraperitoneal space	Liver	Temsirolimus	ND	SD	ND	5	DOD
Bunch et al. [84]	F	19	Uterus	-	Temsirolimus	25 mg/week IV	PR	NR	15	NED
Ghosh et al. [85]	F	57	Pelvis	Pleura, lymph nodes extraperitoneal space	Temsirolimus, sirolimus	25 mg/week IV; 2 mg/d	PR	NR; 3	10	DOD
Chen et al. [86]	F	71	Pelvis	-	Temsirolimus, everolimus	25 mg/week IV, 10 mg/d	SD	NR; 4	7	DOD
Weeber et al. [87]	M	56	Greater omentum	Liver, adrenal glands, extraperitoneal space	Everolimus	10 mg/d	CR	36	48	AWD
Sun et al. [88]	F	46	Uterus	Lungs, kidneys	Sirolimus	ND	PR	NR	7	AWD
Gao et al. [89]	F	47	Uterus	Lungs	Sirolimus + sorafenib	200-300 mg/d	CR	NR	7	NED



Table 2 cont. Cases of PEComa treated with mTOR inhibitors available in the literature

Author	Sex	Age	Tumour location	Metastases	Drug	Dose	Best outcome	Time to progression (months)	Follow-up (months)	Effect
Liu et al. [90]	F	60	Small intestine	–	Sunitinib	2 mg/d	PD	1	ND	AWD
Binyamin et al. [91]	F	56	Kidney	Pubic bone, surgical scar	Everolimus	BD	PD	2	ND	AWD
Starbuck et al. [92]	F	30	Uterus	–	Temsirolimus, sirolimus	25 mg/week IV; 3 mg/d	PR	NR	36	AWD
Flechter et al. [93]	F	43	Uterus	–	Temsirolimus	25 mg/week IV	CR	NR	12	NED
	F	64	Uterus	Abdominal cavity	Temsirolimus	25 mg/week IV	PD	3	18	DOD
	F	35	Small intestine	Lungs, central nervous system	Everolimus	10 mg/d	SD	18	30	DOD
Batareau et al. [94]	F	26	Colon	Abdominal cavity, ovaries, bladder	Sunitinib	ND	PR	NR	36	AWD
Shaikh et al. [95]	F	20	Extrapleural space	Pleura	Everolimus	ND	PR	7	8	DOD
Rao et al. [96]	F	49	Pelvis	Periaortic lymph nodes	Sunitinib	ND	CR	NR	12	NED
	F	6	Heart	–	Neo. sirolimus	ND	SD	NR	24	NED
Varan et al. [97]	M	7	Eye cavity	–	Sunitinib	ND	PD	1	6	AWD
Tang et al. [98]	M	50	Abdominal cavity wall	Mediastinal lymph nodes, lungs, bones	Sunitinib	2–3 mg/d	PD	ND	ND	DOD
Machado et al. [67]	F	33	Greater omentum, small intestine	Liver	Temsirolimus	ND	SD	5	30	DOD
Westaby et al. [29]	F	54	Ovary	–	Sunitinib	ND	PD	1	6	DOD
Kwon et al. [99]	F	62	Uterus and vagina	Lungs, bones	Everolimus	25 mg/week IV	SD	NR	18	AWD
Hulova et al. [77]	F	28	Kidney	–	Everolimus	ND	SD	30	104	DOD
Saluja et al. [100]	F	28	Throat	–	Neo. everolimus	ND	PD	NR	6	NED
Raimondi et al. [75]	M	61	Kidney	Lungs	Sunitinib	1–5 mg/d	PR	NR	20	AWD
Gondran et al. [76]	M	17	Pancreas	–	Sunitinib	4–6 mg/d	PR	NR	42	AWD

Adj. — adjuvant treatment; AWD — alive with disease; ND — no data; DOD — dead of disease; NED — no evidence of disease; NR — not reached; Neo. — neoadjuvant treatment; CR — complete response; PD — progressive disease; PR — partial response; SD — stable disease

Table 3. Classification of PEComa NOS after [44]

Tumour size greater than 5 cm	Benign < 2 high risk characteristics and size < 5 cm
High degree of histological malignancy and high cellularity	Uncertain malignancy potential Size > 5 cm and no other high-risk characteristics OR nuclear pleomorphism/multinuclear giant cells
High mitotic index (> 1/50 HPF)	Malignant
Presence of necrosis	2 or more high-risk characteristics
Infiltration of blood vessels	

along with new liver metastases [72]. A 36-month stabilisation of the disease has also been described in a patient with kidney PEComa with metastases to the lung as a response to everolimus [77]. Italiano et al. described a response to temsirolimus treatment in a patient after resection of a uterine PEComa with a single lung metastasis. A decrease in tumour size by 35% was observed with a subsequent lobectomy. The patient remained disease free for nine months after the surgery with continued temsirolimus therapy [78].

In spite of promising responses, cases of resistance to mTOR inhibitors have also been described in combination with resistance to chemotherapy or without it. Machado et al. described a case of resistance to both Adriamycin and ifosfamide in high doses as well as temsirolimus (SD for a period of five months), leading to the patient's death 30 months after the diagnosis [67]. As markers of expected response to sirolimus and everolimus, the following are indicated: the presence of *TSC1/TSC2* gene mutations and overexpression of ribosomal protein pS6-S235/236 [67]. Single cases of the use of this group of drugs in patients with PEComas described in the literature are summarised in Table 2.

Regarding new drugs, recently a case of a one-year disease stabilisation in response to pazopanib combined with nivolumab has been described in an advanced PEComa of the lower limb with metastases to bones and lungs [63]. Potential benefits of using angiogenesis inhibitors in patients with advanced PEComa have been described, but only a very small percentage of objective responses have been achieved, mainly in the form of disease stabilisation: ORR = 8.3%, PFS = 5.4 months [70].

Survival — prognostic factors for PEComa-NOS

Among PEComa-NOS tumours, both clinically benign tumours as well as rapidly progressing tumours with disease dissemination are observed. Folpe et al. proposed the division of PEComas into three categories of risk: benign tumours, tumours with an uncertain malignancy potential, and malignant tumours, on the

basis of the presence of the high-risk characteristics presented in Table 3 [44].

The prognostic suitability of the above-mentioned criteria was evaluated in a large review, encompassing 234 PEComa NOS cases available in the literature [3]. Among tumours classified as benign according to the Folpe criteria no relapses of the disease were observed. However, among cases in which a relapse did occur, tumours classified as malignant constituted 81.6% (median time to relapse 23 months). In about 30% of all cases the tumours were malignant (local relapse or disease dissemination took place), and tumours evaluated as malignant according to Folpe constituted 51% of these tumours [3]. 10.6% of cases led to death because of the disease, and seven of them were diagnosed at the moment of dissemination or in a non-resectable stage, and in 13 relapse occurred after resection [3]. In the same paper a significant correlation was demonstrated between tumour size over 5 cm ($p = 0.04$, RR = 6.16, 95% CI: 1.04–117.4), a high mitotic index (> 1/50 HPS) ($p < 0.01$, RR = 6.96, 95% CI: 2.2–26.7), low degree of cellular differentiation — Grade 3 ($p = 0.03$, RR = 3.35, 95% CI: 1.17–9.42), and a higher risk of PEComa relapse after resection [3]. The primary location in skin was linked to a lower risk of local relapse after resection. In 20 of the described cases not one relapsed ($p = 0.002$, RR = 6.2×10^{-7} , 95% CI: not calculable), whereas relapse occurred in 11.1% of cases located in the liver and in 33.3% of cases concerning extraperitoneal space [3].

In another analysis concerning PEComas localised in female sex organs, the following were among factors significantly correlated with a risk of recurrence or metastases: size greater than 5 cm ($p = 0.0048$), presence of necrosis ($p = 0.0014$), infiltration of lymph vessels ($p = 0.0006$), pronounced nuclear atypia ($p = 0.0192$), and mitotic activity > 1/50 HPF ($p = 0.011$) [36]. In an investigation focused on digestive tract PEComas, there were distant metastases in 37% of patients, and a higher risk of their occurrence was correlated with the following: pronounced nuclear atypia ($p = 0.0033$), disseminated pleomorphism ($p = 0.02$), and the presence of ≥ 2 mitoses/10 HPF ($p = 0.0002$) [11]. In another

analysis concerning digestive tract PEComa, local relapse did not occur, and the presence of distant metastases after resection was observed in 37.1% of patients, with a median of time to occurrence of metastases of six months [35].

In an analysis encompassing PEComas localised in female sex organs, 66% of cases were treated by surgery alone, and the average OS after resection was 24.8 months. The age of the patient was a negative OS predictor. In patients with disseminated disease treated by surgery with adjuvant chemotherapy or radiotherapy the average OS was 17.8 months, and in those treated only systemically or by radiotherapy it was 20.7 months. Patients with initial disseminated disease had a shorter OS regardless of the selected treatment method [35].

Summary

Malignant PEComa tumours are most frequently diagnosed in middle-aged women as extensive tumours localised in the abdominal cavity or pelvis, presenting as pain from the tumour progression and problems linked to pressure on surrounding organs. These tumours, because of expression of melanocyte and myoid markers and the presence of poorly differentiated epithelioid cells, should be differentiated from stromal neoplasms of the digestive tract, leiomyosarcoma, melanoma metastases, chromophobic type of renal cell carcinoma, clear cell sarcoma, and other neoplasms with a clear cell component. Somatic inactivating mutations within the *TSC1/TSC2* genes and fusions of the *TFE3* gene resulting in excessive activation of the mTORC1 complex are characteristic for these tumours. Among negative prognostic factors indicating an increased risk of malignant PEComa biology the most commonly included are: tumour size > 5 cm, pronounced cytological and nuclear atypia, infiltration of surrounding tissues and blood vessels, the presence of necrosis and high mitotic activity. Radical resection remains the main method of PEComa treatment because these tumours show a high resistance to radiotherapy and chemotherapy. There are increasing numbers of reports about the potential effectiveness of using mTOR inhibitors in non-resectable cases. These drugs cause a decrease in the size of the primary tumours and metastases and a decrease in the ailments, and the undesirable actions can be controlled. Unfortunately, cases have also been described of complete resistance to treatment with mTOR inhibitors.

References

1. Klimczak A, Pękuł M, Wiater K, Rutkowski P. PEComa — grupa rzadkich nowotworów pochodzenia mezenchymalnego. *Nowotwory Journal of Oncology* 2011; 61(1): 52–56.

2. Liegl B, Hornick JL, Fletcher CDM. Primary cutaneous PEComa: distinctive clear cell lesions of skin. *Am J Surg Pathol*. 2008; 32(4): 608–614, doi: [10.1097/PAS.0b013e31815604ab](https://doi.org/10.1097/PAS.0b013e31815604ab), indexed in Pubmed: [18277881](https://pubmed.ncbi.nlm.nih.gov/18277881/).
3. Bleeker JS, Quevedo JF, Folpe AL. "Malignant" perivascular epithelioid cell neoplasm: risk stratification and treatment strategies. *Sarcoma*. 2012; 541626, doi: [10.1155/2012/541626](https://doi.org/10.1155/2012/541626), indexed in Pubmed: [22619565](https://pubmed.ncbi.nlm.nih.gov/22619565/).
4. Armah HB, Parwani AV. Malignant perivascular epithelioid cell tumor (PEComa) of the uterus with late renal and pulmonary metastases: a case report with review of the literature. *Diagn Pathol*. 2007; 2: 45.
5. Wagner AJ, Ravi V, Ganjoo KN, et al. ABI-009 (nab-sirolimus) in advanced malignant perivascular epithelioid cell tumors (PEComa): Preliminary efficacy, safety, and mutational status from AMPECT, an open label phase II registration trial. *J Clin Oncol*. 2019; 11005–11005.
6. Sadigh S, Shah P, Weber K, et al. Primary malignant perivascular epithelioid cell neoplasm (PEComa) of the bone mimicking granular cell tumor in core biopsy: A case report and literature review. *Oncol Lett*. 2018; 15(3): 2946–2952, doi: [10.3892/ol.2017.7662](https://doi.org/10.3892/ol.2017.7662), indexed in Pubmed: [29435023](https://pubmed.ncbi.nlm.nih.gov/29435023/).
7. Agaram NP, Sung YS, Zhang L, et al. Dichotomy of Genetic Abnormalities in PEComas With Therapeutic Implications. *Am J Surg Pathol*. 2015; 39(6): 813–825, doi: [10.1097/PAS.0000000000000389](https://doi.org/10.1097/PAS.0000000000000389), indexed in Pubmed: [25651471](https://pubmed.ncbi.nlm.nih.gov/25651471/).
8. Chen Z, Han S, Wu J, et al. A systematic review: perivascular epithelioid cell tumor of gastrointestinal tract. *Medicine (Baltimore)*. 2016; 95(28): e3890, doi: [10.1097/MD.00000000000003890](https://doi.org/10.1097/MD.00000000000003890), indexed in Pubmed: [27428182](https://pubmed.ncbi.nlm.nih.gov/27428182/).
9. Niu H, Wang FW, Zhang PJ, et al. Cardiac epithelioid PEComa: report of two cases and review of the literature. *Case Rep Med*. 2012; 2012: 521678, doi: [10.1155/2012/521678](https://doi.org/10.1155/2012/521678), indexed in Pubmed: [22973317](https://pubmed.ncbi.nlm.nih.gov/22973317/).
10. Nair AG, Gore SS, Ganvir AY, et al. Giant perivascular epithelioid cell tumor of the orbit: a clinicopathological analysis and review of the literature. *Ocul Oncol Pathol*. 2018; 4(5): 272–279, doi: [10.1159/000484425](https://doi.org/10.1159/000484425), indexed in Pubmed: [30320097](https://pubmed.ncbi.nlm.nih.gov/30320097/).
11. Doyle LA, Hornick JL, Fletcher CDM. PEComa of the gastrointestinal tract: clinicopathologic study of 35 cases with evaluation of prognostic parameters. *Am J Surg Pathol*. 2013; 37(12): 1769–1782, doi: [10.1097/PAS.0b013e31829caab3](https://doi.org/10.1097/PAS.0b013e31829caab3), indexed in Pubmed: [24061520](https://pubmed.ncbi.nlm.nih.gov/24061520/).
12. Zizzo M, Ugoletti L, Tumiati D, et al. Primary pancreatic perivascular epithelioid cell tumor (PEComa): A surgical enigma. A systematic review of the literature. *Pancreatol*. 2018; 18(3): 238–245, doi: [10.1016/j.pan.2018.02.007](https://doi.org/10.1016/j.pan.2018.02.007), indexed in Pubmed: [29478828](https://pubmed.ncbi.nlm.nih.gov/29478828/).
13. Sikora-Szczeńsiak D. PEComa of the uterus — a case report. *Ginekol Pol*. 2013; 84(3): 234–236, doi: [10.17772/gp/1570](https://doi.org/10.17772/gp/1570).
14. D'Andrea D, Hanspeter E, D'Elia C, et al. Malignant perivascular epithelioid cell neoplasm (PEComa) of the Pelvis: a case report. *Urol Case Rep*. 2016; 6: 36–38, doi: [10.1016/j.eucr.2016.02.004](https://doi.org/10.1016/j.eucr.2016.02.004), indexed in Pubmed: [27169023](https://pubmed.ncbi.nlm.nih.gov/27169023/).
15. Lu B, Wang C, Zhang J, et al. Perivascular epithelioid cell tumor of gastrointestinal tract: case report and review of the literature. *Medicine (Baltimore)*. 2015; 94(3): e393, doi: [10.1097/MD.0000000000000393](https://doi.org/10.1097/MD.0000000000000393), indexed in Pubmed: [25621681](https://pubmed.ncbi.nlm.nih.gov/25621681/).
16. Xu J, Yan Yu, Xiang X, et al. Gastric perivascular epithelioid cell tumor (PEComa). *Am J Clin Pathol*. 2019; 152(2): 221–229, doi: [10.1093/ajcp/aqz040](https://doi.org/10.1093/ajcp/aqz040), indexed in Pubmed: [31141597](https://pubmed.ncbi.nlm.nih.gov/31141597/).
17. Yanai H, Matsuura H, Sonobe H, et al. Perivascular epithelioid cell tumor of the jejunum. *Pathol Res Pract*. 2003; 199(1): 47–50, doi: [10.1078/0344-0338-00353](https://doi.org/10.1078/0344-0338-00353), indexed in Pubmed: [12650518](https://pubmed.ncbi.nlm.nih.gov/12650518/).
18. Ryan P, Nguyen VH, Gholoum S, et al. Polypoid PEComa in the rectum of a 15-year-old girl: case report and review of PEComa in the gastrointestinal tract. *Am J Surg Pathol*. 2009; 33(3): 475–482, doi: [10.1097/PAS.0b013e31819003d1](https://doi.org/10.1097/PAS.0b013e31819003d1), indexed in Pubmed: [19092636](https://pubmed.ncbi.nlm.nih.gov/19092636/).
19. Okamoto K, Okada Y, Ohno K, et al. A rare case of perivascular epithelioid cell tumor (PEComa) of the greater omentum. *World J Surg Oncol*. 2018; 16(1): 113, doi: [10.1186/s12957-018-1407-5](https://doi.org/10.1186/s12957-018-1407-5), indexed in Pubmed: [29921303](https://pubmed.ncbi.nlm.nih.gov/29921303/).
20. Zhao L, Anders KH. Malignant perivascular epithelioid cell tumor of the gallbladder: a case report and review of literature. *Arch Pathol Lab Med*. 2014; 138(9): 1238–1241, doi: [10.5858/arpa.2013-0092-CR](https://doi.org/10.5858/arpa.2013-0092-CR), indexed in Pubmed: [25171708](https://pubmed.ncbi.nlm.nih.gov/25171708/).
21. Sadeghi S, Krigman H, Maluf H. Perivascular epithelioid clear cell tumor of the common bile duct. *Am J Surg Pathol*. 2004; 28(8): 1107–1110, doi: [10.1097/01.pas.0000116831.81882.d0](https://doi.org/10.1097/01.pas.0000116831.81882.d0), indexed in Pubmed: [15252321](https://pubmed.ncbi.nlm.nih.gov/15252321/).
22. Kim H, Kim J, Lee SeK, et al. TFE3-Expressing perivascular epithelioid cell tumor of the breast. *J Pathol Transl Med*. 2019; 53(1): 62–65, doi: [10.4132/jptm.2018.08.30](https://doi.org/10.4132/jptm.2018.08.30), indexed in Pubmed: [30269476](https://pubmed.ncbi.nlm.nih.gov/30269476/).
23. Torii I, Kondo N, Takuwa T, et al. Perivascular epithelioid cell tumor of the rib. *Virchows Arch*. 2008; 452(6): 697–702, doi: [10.1007/s00428-008-0612-y](https://doi.org/10.1007/s00428-008-0612-y), indexed in Pubmed: [18437415](https://pubmed.ncbi.nlm.nih.gov/18437415/).

24. Lehman NL. Malignant PEComa of the skull base. *Am J Surg Pathol*. 2004; 28(9): 1230–1232, doi: [10.1097/O1.pas.0000128668.34934.81](https://doi.org/10.1097/O1.pas.0000128668.34934.81), indexed in Pubmed: [15316324](https://pubmed.ncbi.nlm.nih.gov/15316324/).
25. Tai Y, Wei L, Shi H. Perivascular epithelioid cell tumor of the heart in a child. *Pediatr Dev Pathol*. 2010; 13(5): 412–414, doi: [10.2350/09-10-0726-CR.1](https://doi.org/10.2350/09-10-0726-CR.1), indexed in Pubmed: [20085497](https://pubmed.ncbi.nlm.nih.gov/20085497/).
26. Mollazadeh R, Moaref A, Ghazinoor M, et al. Pericardial PEComa: echocardiographic features. *International Journal of Cardiology*. 2009; 132(1): e5–e7, doi: [10.1016/j.ijcard.2007.07.088](https://doi.org/10.1016/j.ijcard.2007.07.088).
27. Pan CC, Yang AH, Chiang H. Malignant perivascular epithelioid cell tumor involving the prostate. *Arch Pathol Lab Med*. 2003; 127(2): E96–98.
28. Sbröllini G, Conti A, Galosi AB, et al. Perivascular epithelioid cell tumor (PEC-ome) of the prostate: ultrasound feature in case report. *Arch Ital Urol Androl*. 2014; 86(4): 393–394, doi: [10.4081/aiua.2014.4.393](https://doi.org/10.4081/aiua.2014.4.393), indexed in Pubmed: [25641481](https://pubmed.ncbi.nlm.nih.gov/25641481/).
29. Westaby JD, Magdy N, Fisher C, et al. Primary ovarian malignant PEComa: a case report. *Int J Gynecol Pathol*. 2017; 36(4): 400–404, doi: [10.1097/PGP.0000000000000331](https://doi.org/10.1097/PGP.0000000000000331), indexed in Pubmed: [27684885](https://pubmed.ncbi.nlm.nih.gov/27684885/).
30. Kuroda N, Goda M, Kazakov DV, et al. Perivascular epithelioid cell tumor of the nasal cavity with TFE3 expression. *Pathol Int*. 2009; 59(10): 769–770, doi: [10.1111/j.1440-1827.2009.02443.x](https://doi.org/10.1111/j.1440-1827.2009.02443.x), indexed in Pubmed: [19788626](https://pubmed.ncbi.nlm.nih.gov/19788626/).
31. Huai-yin S, Li-xin W, Lu S, et al. Perivascular epithelioid cell tumors of the laryngopharynx: three case reports and literature review. *Pathol Res Pract*. 2009; 205(9): 595–600, doi: [10.1016/j.prp.2009.02.003](https://doi.org/10.1016/j.prp.2009.02.003), indexed in Pubmed: [19409723](https://pubmed.ncbi.nlm.nih.gov/19409723/).
32. Palleschi G, Pastore AL, Evangelista S, et al. Bone metastases from bladder perivascular epithelioid cell tumor — an unusual localization of a rare tumor: a case report. *J Med Case Rep*. 2014; 8: 227, doi: [10.1186/1752-1947-8-227](https://doi.org/10.1186/1752-1947-8-227), indexed in Pubmed: [24965209](https://pubmed.ncbi.nlm.nih.gov/24965209/).
33. Chakrabarti A, Bandyopadhyay M, Purkayastha B. Malignant perivascular epithelioid cell tumour (PEComa) of the lung — a rare entity. *Innov Surg Sci*. 2017; 2(1): 39–42, doi: [10.1515/iss-2016-0032](https://doi.org/10.1515/iss-2016-0032), indexed in Pubmed: [31579733](https://pubmed.ncbi.nlm.nih.gov/31579733/).
34. Tynski Z, Chiang W, Barrett A. An inguinal perivascular epithelioid cell tumor metastatic to the orbit. *Case Rep Pathol*. 2018; 2018: 5749421, doi: [10.1155/2018/5749421](https://doi.org/10.1155/2018/5749421), indexed in Pubmed: [30002939](https://pubmed.ncbi.nlm.nih.gov/30002939/).
35. Zekry N, Rettenmaier MA, Abaid LN, et al. Perivascular epithelioid cell neoplasms: a systematic review of prognostic factors. *J Minim Invasive Gynecol*. 2009; 16(5): 527–532, doi: [10.1016/j.jmig.2009.04.017](https://doi.org/10.1016/j.jmig.2009.04.017), indexed in Pubmed: [19596216](https://pubmed.ncbi.nlm.nih.gov/19596216/).
36. Schoolmeester JK, Howitt BE, Hirsch MS, et al. Perivascular epithelioid cell neoplasm (PEComa) of the gynecologic tract: clinicopathologic and immunohistochemical characterization of 16 cases. *Am J Surg Pathol*. 2014; 38(2): 176–188, doi: [10.1097/PAS.0000000000000133](https://doi.org/10.1097/PAS.0000000000000133), indexed in Pubmed: [24418852](https://pubmed.ncbi.nlm.nih.gov/24418852/).
37. Okamoto S, Komura M, Terao Y, et al. Pneumothorax caused by cystic and nodular lung metastases from a malignant uterine perivascular epithelioid cell tumor (PEComa). *Respir Med Case Rep*. 2017; 22: 77–82, doi: [10.1016/j.rmcr.2017.06.011](https://doi.org/10.1016/j.rmcr.2017.06.011), indexed in Pubmed: [28706850](https://pubmed.ncbi.nlm.nih.gov/28706850/).
38. Parra-Medina R, Morales SD. Cutaneous perivascular epithelioid cell tumor of gynecologic origin metastatic to skin, lung, stomach, and brain. *Am J Dermatopathol*. 2017; 39(2): 157–159, doi: [10.1097/DAD.0000000000000624](https://doi.org/10.1097/DAD.0000000000000624), indexed in Pubmed: [27149334](https://pubmed.ncbi.nlm.nih.gov/27149334/).
39. Casali PG, Abecassis N, Aro HT, et al. Soft tissue and visceral sarcomas: ESMO–EURACAN Clinical Practice Guidelines for diagnosis, treatment and follow-up. *Ann Oncol*. 2018; 29(Supplement_4): iv268–iv269, doi: [10.1093/annonc/mdy321](https://doi.org/10.1093/annonc/mdy321).
40. Tirumani SH, Shinagare AB, Hargreaves J, et al. Imaging features of primary and metastatic malignant perivascular epithelioid cell tumors. *AJR Am J Roentgenol*. 2014; 202(2): 252–258, doi: [10.2214/AJR.13.10909](https://doi.org/10.2214/AJR.13.10909), indexed in Pubmed: [24450662](https://pubmed.ncbi.nlm.nih.gov/24450662/).
41. Parfitt JR, Bella AJ, Izawa JI, Wehrli BM. Malignant neoplasm of perivascular epithelioid cells of the liver. *Arch Pathol Lab Med*. 2006; 130(8): 1219–1222.
42. Maloney N, Giannikou K, Leferts J, Bridge JA, Linos K. Expanding the Histomorphologic Spectrum of TFE3 Rearranged PEComas. *Hum Pathol*. 2018.
43. Iwa N, Yutani C, Kobayashi TK. Presence of eosinophilic intracytoplasmic inclusions diagnosed by fine needle aspiration cytology in perivascular epithelioid cell tumor (PEComa) arising from the cecum. *Diagn Cytopathol*. 2019; 47(4): 359–361, doi: [10.1002/dc.24086](https://doi.org/10.1002/dc.24086), indexed in Pubmed: [30499191](https://pubmed.ncbi.nlm.nih.gov/30499191/).
44. Folpe AL, Mentzel T, Lehr HA, et al. Perivascular epithelioid cell neoplasms of soft tissue and gynecologic origin: a clinicopathologic study of 26 cases and review of the literature. *Am J Surg Pathol*. 2005; 29(12): 1558–1575, doi: [10.1097/O1.pas.0000173232.22117.37](https://doi.org/10.1097/O1.pas.0000173232.22117.37), indexed in Pubmed: [16327428](https://pubmed.ncbi.nlm.nih.gov/16327428/).
45. Bennett JA, Braga AC, Pinto A, et al. Uterine PEComas: a morphologic, immunohistochemical, and molecular analysis of 32 tumors. *Am J Surg Pathol*. 2018; 42(10): 1370–1383, doi: [10.1097/PAS.0000000000001119](https://doi.org/10.1097/PAS.0000000000001119), indexed in Pubmed: [30001237](https://pubmed.ncbi.nlm.nih.gov/30001237/).
46. Hornick JL, Fletcher CDM. Sclerosing PEComa: clinicopathologic analysis of a distinctive variant with a predilection for the retroperitoneum. *Am J Surg Pathol*. 2008; 32(4): 493–501, doi: [10.1097/PAS.0b013e318161dc34](https://doi.org/10.1097/PAS.0b013e318161dc34), indexed in Pubmed: [18223480](https://pubmed.ncbi.nlm.nih.gov/18223480/).
47. Martignoni G, Bonetti F, Chilosi M, et al. Cathepsin K expression in the spectrum of perivascular epithelioid cell (PEC) lesions of the kidney. *Mod Pathol*. 2012; 25(1): 100–111, doi: [10.1038/modpathol.2011.136](https://doi.org/10.1038/modpathol.2011.136), indexed in Pubmed: [21874011](https://pubmed.ncbi.nlm.nih.gov/21874011/).
48. Gulavita P, Fletcher CDM, Hirsch MS. PNL2: an adjunctive biomarker for renal angiomyolipomas and perivascular epithelioid cell tumours. *Histopathology*. 2018; 72(3): 441–448, doi: [10.1111/his.13369](https://doi.org/10.1111/his.13369), indexed in Pubmed: [28837273](https://pubmed.ncbi.nlm.nih.gov/28837273/).
49. Abhirup B, Kaushal K, Sanket M, et al. Malignant hepatic perivascular epithelioid cell tumor (PEComa) — case report and a brief review. *J Egypt Natl Canc Inst*. 2015; 27(4): 239–242, doi: [10.1016/j.jnci.2015.05.004](https://doi.org/10.1016/j.jnci.2015.05.004), indexed in Pubmed: [26071321](https://pubmed.ncbi.nlm.nih.gov/26071321/).
50. Fernandez-Flores A, Nguyen CM, Cassarino DS. Cutaneous PEComas Express CD10: Implications for the Classification of PEComas and the Differential Diagnosis With Metastatic Renal Cell Carcinoma. *Am J Dermatopathol*. 2016; 38(9): 645–652, doi: [10.1097/DAD.0000000000000475](https://doi.org/10.1097/DAD.0000000000000475), indexed in Pubmed: [26909587](https://pubmed.ncbi.nlm.nih.gov/26909587/).
51. Armah HB, Parwani AV. Perivascular epithelioid cell tumor. *Arch Pathol Lab Med*. 2009; 133(4): 648–654.
52. Sangiorgio V, Daniele L, Gallo T, et al. Ultrasound-guided fine needle aspiration cytology in the diagnosis of hepatic and pancreatic perivascular epithelioid cell tumors: A case series. *Diagn Cytopathol*. 2019; 47(4): 315–319, doi: [10.1002/dc.24111](https://doi.org/10.1002/dc.24111), indexed in Pubmed: [30417984](https://pubmed.ncbi.nlm.nih.gov/30417984/).
53. Pan CC, Jong YJ, Chai CY, et al. Comparative genomic hybridization study of perivascular epithelioid cell tumor: molecular genetic evidence of perivascular epithelioid cell tumor as a distinctive neoplasm. *Hum Pathol*. 2006; 37(5): 606–612, doi: [10.1016/j.humpath.2006.01.008](https://doi.org/10.1016/j.humpath.2006.01.008), indexed in Pubmed: [16647959](https://pubmed.ncbi.nlm.nih.gov/16647959/).
54. Pan CC, Chung MY, Ng KF, et al. Constant allelic alteration on chromosome 16p (TSC2 gene) in perivascular epithelioid cell tumour (PEComa): genetic evidence for the relationship of PEComa with angiomyolipoma. *J Pathol*. 2008; 214(3): 387–393, doi: [10.1002/path.2289](https://doi.org/10.1002/path.2289), indexed in Pubmed: [18085521](https://pubmed.ncbi.nlm.nih.gov/18085521/).
55. Kenerson H, Folpe AL, Takayama TK, et al. Activation of the mTOR pathway in sporadic angiomyolipomas and other perivascular epithelioid cell neoplasms. *Hum Pathol*. 2007; 38(9): 1361–1371, doi: [10.1016/j.humpath.2007.01.028](https://doi.org/10.1016/j.humpath.2007.01.028), indexed in Pubmed: [17521703](https://pubmed.ncbi.nlm.nih.gov/17521703/).
56. Sukov WR, Hodge JC, Lohse CM, et al. TFE3 rearrangements in adult renal cell carcinoma: clinical and pathologic features with outcome in a large series of consecutively treated patients. *Am J Surg Pathol*. 2012; 36(5): 663–670, doi: [10.1097/PAS.0b013e31824dd972](https://doi.org/10.1097/PAS.0b013e31824dd972), indexed in Pubmed: [22498819](https://pubmed.ncbi.nlm.nih.gov/22498819/).
57. Jaber OI, Kirby PA. Alveolar soft part sarcoma. *Arch Pathol Lab Med*. 2015; 139(11): 1459–1462, doi: [10.5858/arpa.2014-0385-RS](https://doi.org/10.5858/arpa.2014-0385-RS), indexed in Pubmed: [26516944](https://pubmed.ncbi.nlm.nih.gov/26516944/).
58. Hua X, Liu X, Ansari DO, et al. Synergistic cooperation of TFE3 and smad proteins in TGF-beta-induced transcription of the plasminogen activator inhibitor-1 gene. *Genes Dev*. 1998; 12(19): 3084–3095, doi: [10.1101/gad.12.19.3084](https://doi.org/10.1101/gad.12.19.3084), indexed in Pubmed: [9765209](https://pubmed.ncbi.nlm.nih.gov/9765209/).
59. Jones E, Inoki K. Microphthalmia-associated transcription factors activate mTORC1 through RagD GTPase gene expression. *Transl Cancer Res*. 2017; 6(Suppl 7): S1234–S1238, doi: [10.21037/tpcr.2017.09.31](https://doi.org/10.21037/tpcr.2017.09.31), indexed in Pubmed: [31187024](https://pubmed.ncbi.nlm.nih.gov/31187024/).
60. Slade L, Pulinilkunnit T. The MITF/TFE family of transcription factors: master regulators of organelle signaling, metabolism, and stress adaptation. *Mol Cancer Res*. 2017; 15(12): 1637–1643, doi: [10.1158/1541-7786.MCR-17-0320](https://doi.org/10.1158/1541-7786.MCR-17-0320), indexed in Pubmed: [28851811](https://pubmed.ncbi.nlm.nih.gov/28851811/).
61. Rao Q, Shen Q, Xia Qy, et al. PSF/SFPQ is a very common gene fusion partner in TFE3 rearrangement-associated perivascular epithelioid cell tumors (PEComas) and melanotic Xp11 translocation renal cancers: clinicopathologic, immunohistochemical, and molecular characteristics suggesting classification as a distinct entity. *Am J Surg Pathol*. 2015; 39(9): 1181–1196, doi: [10.1097/PAS.0000000000000502](https://doi.org/10.1097/PAS.0000000000000502), indexed in Pubmed: [26274027](https://pubmed.ncbi.nlm.nih.gov/26274027/).
62. Argani P, Aulmann S, Illei PB, et al. A distinctive subset of PEComas harbors TFE3 gene fusions. *Am J Surg Pathol*. 2010; 34(10): 1395–1406, doi: [10.1097/PAS.0b013e3181f17ac0](https://doi.org/10.1097/PAS.0b013e3181f17ac0), indexed in Pubmed: [20871214](https://pubmed.ncbi.nlm.nih.gov/20871214/).
63. Alnajjar H, Brickman A, Buckingham L, et al. Metastatic malignant PEComa of the leg with identification of ATRX mutation by next-

- generation sequencing. *Virchows Arch.* 2018; 472(3): 499–503, doi: [10.1007/s00428-017-2208-x](https://doi.org/10.1007/s00428-017-2208-x), indexed in Pubmed: 28755029.
64. Koelsche C, Renner M, Johann P, et al. Differential nuclear ATRX expression in sarcomas. *Histopathology.* 2016; 68(5): 738–745, doi: [10.1111/his.12812](https://doi.org/10.1111/his.12812), indexed in Pubmed: 26291601.
 65. Liao JY, Tsai JH, Jeng YM, et al. Leiomyosarcoma with alternative lengthening of telomeres is associated with aggressive histologic features, loss of ATRX expression, and poor clinical outcome. *Am J Surg Pathol.* 2015; 39(2): 236–244, doi: [10.1097/PAS.0000000000000324](https://doi.org/10.1097/PAS.0000000000000324), indexed in Pubmed: 25229770.
 66. Rutkowski PL, Mullen JT. Management of the “Other” retroperitoneal sarcomas. *J Surg Oncol.* 2018; 117(1): 79–86, doi: [10.1002/jso.24893](https://doi.org/10.1002/jso.24893), indexed in Pubmed: 29127695.
 67. Machado I, Cruz J, Lavernia J, et al. Malignant PEComa with metastatic disease at diagnosis and resistance to several chemotherapy regimens and targeted therapy (m-TOR inhibitor). *Int J Surg Pathol.* 2017; 25(6): 543–549, doi: [10.1177/1066896917701245](https://doi.org/10.1177/1066896917701245), indexed in Pubmed: 28459168.
 68. Kirste S, Kayser G, Zipfel A, et al. Unresectable hepatic PEComa: a rare malignancy treated with stereotactic body radiation therapy (SBRT) followed by complete resection. *Radiat Oncol.* 2018; 13(1): 28, doi: [10.1186/s13014-018-0974-5](https://doi.org/10.1186/s13014-018-0974-5), indexed in Pubmed: 29463266.
 69. Liu JL, Lin YM, Lin MC, et al. Perivascular epithelioid cell tumor (PEComa) of the uterus with aggressive behavior at presentation. *Hematol Oncol Stem Cell Ther.* 2009; 2(3): 426–430, doi: [10.1016/s1658-3876\(09\)50013-1](https://doi.org/10.1016/s1658-3876(09)50013-1).
 70. Sanfilippo R, Jones RL, Blay J-Y, et al. Role of chemotherapy, VEGFR inhibitors and mTOR Inhibitors in advanced Perivascular Epithelioid Cell Tumours (PEComas). *Clinical Cancer Research: clincanres.0288.2019.*
 71. Osei DA, Alvandi F, Brooks JS, et al. PEComa of the upper extremity: a unique case and description of an initial response to neoadjuvant chemotherapy. *Sarcoma.* 2007; 2007: 53056, doi: [10.1155/2007/53056](https://doi.org/10.1155/2007/53056), indexed in Pubmed: 18274609.
 72. Scheppach W, Reissmann N, Sprinz T, et al. PEComa of the colon resistant to sirolimus but responsive to doxorubicin/ifosfamide. *World J Gastroenterol.* 2013; 19(10): 1657–1660, doi: [10.3748/wjg.v19.i10.1657](https://doi.org/10.3748/wjg.v19.i10.1657), indexed in Pubmed: 23539498.
 73. Rutkowski P, Przybyl J, Świtaj T. Genetics of rare mesenchymal tumors: implications for targeted treatment in DFSP, ASPS, CCS, GCTB and PEComa. *Int J Biochem Cell Biol.* 2014; 53: 466–474, doi: [10.1016/j.biocel.2014.03.024](https://doi.org/10.1016/j.biocel.2014.03.024), indexed in Pubmed: 24704529.
 74. Benson C, Vitell-Rasmussen J, Maruzzo M, et al. A retrospective study of patients with malignant PEComa receiving treatment with sirolimus or temsirolimus: the Royal Marsden Hospital experience. *Anticancer Res.* 2014; 34(7): 3663–3668, indexed in Pubmed: 24982384.
 75. Raimondi A, Colombo F, Pintarelli G, et al. Prolonged activity and toxicity of sirolimus in a patient with metastatic renal perivascular epithelioid cell tumor: a case report and literature review. *Anticancer Drugs.* 2018; 29(6): 589–595, doi: [10.1097/CAD.0000000000000634](https://doi.org/10.1097/CAD.0000000000000634), indexed in Pubmed: 29668485.
 76. Gondran H, Thebaud E, Moreau A, et al. First pancreatic perivascular epithelioid cell tumor (PEComa) treated by mTOR inhibitor. *Pancreatol.* 2019.
 77. Hulová S, Sycova-Mila Z, Macák D, et al. Diagnostic challenges and extraordinary treatment response in rare malignant PEComa tumor of the kidney. *Klin Onkol.* 2018; 31(6): 448–452, doi: [10.14735/amko2018448](https://doi.org/10.14735/amko2018448), indexed in Pubmed: 30545225.
 78. Italiano A, Delcambre C, Hostein I, et al. Treatment with the mTOR inhibitor temsirolimus in patients with malignant PEComa. *Ann Oncol.* 2010; 21(5): 1135–1137, doi: [10.1093/annonc/mdq044](https://doi.org/10.1093/annonc/mdq044), indexed in Pubmed: 20215136.
 79. Wagner AJ, Malinowska-Kolodziej I, Morgan JA, et al. Clinical activity of mTOR inhibition with sirolimus in malignant perivascular epithelioid cell tumors: targeting the pathogenic activation of mTORC1 in tumors. *J Clin Oncol.* 2010; 28(5): 835–840, doi: [10.1200/JCO.2009.25.2981](https://doi.org/10.1200/JCO.2009.25.2981), indexed in Pubmed: 20048174.
 80. Gennatas C, Michalaki V, Kairi PV, et al. Successful treatment with the mTOR inhibitor everolimus in a patient with perivascular epithelioid cell tumor. *World J Surg Oncol.* 2012; 10: 181, doi: [10.1186/1477-7819-10-181](https://doi.org/10.1186/1477-7819-10-181), indexed in Pubmed: 22943457.
 81. Dickson MA, Schwartz GK, Antonescu CR, et al. Extrarenal perivascular epithelioid cell tumors (PEComas) respond to mTOR inhibition: clinical and molecular correlates. *Int J Cancer.* 2013; 132(7): 1711–1717, doi: [10.1002/ijc.27800](https://doi.org/10.1002/ijc.27800), indexed in Pubmed: 22927055.
 82. Bergamo F, Maruzzo M, Basso U, et al. Neoadjuvant sirolimus for a large hepatic perivascular epithelioid cell tumor (PEComa). *World J Surg Oncol.* 2014; 12: 46, doi: [10.1186/1477-7819-12-46](https://doi.org/10.1186/1477-7819-12-46), indexed in Pubmed: 24575738.
 83. Nakanishi S, Miyazato M, Yonemori K, et al. Perirenal malignant perivascular epithelioid cell tumor originating from right retroperitoneum: a case report. *Hinyokika Kyo.* 2014; 60(12): 627–630.
 84. Bunch K, Sunde J. Fertility sparing treatment of a malignant uterine perivascular epithelioid cell tumor: A case report. *Gynecol Oncol Case Rep.* 2014; 8: 14–16, doi: [10.1016/j.gynor.2014.01.001](https://doi.org/10.1016/j.gynor.2014.01.001), indexed in Pubmed: 24567888.
 85. Ghosh I, Arun I, Sen S, et al. Metastatic perivascular epithelioid cell tumor responding to mammalian target of rapamycin inhibition. *Indian J Med Paediatr Oncol.* 2014; 35(1): 99–102, doi: [10.4103/0971-5851.133733](https://doi.org/10.4103/0971-5851.133733), indexed in Pubmed: 25006296.
 86. Chen S-C, Yang C-W, Yen C-C, Tseng C-H, Chao T-C. Perivascular epithelioid cell tumors (PEComas) refractory to mTOR inhibitors. *Journal of Cancer Research and Practice.* 2014; 1(2): 128–133.
 87. Weeber F, Koudijs MJ, Hoogstraat M, et al. Effective therapeutic intervention and comprehensive genetic analysis of mTOR signaling in PEComa: A Case Report. *Anticancer Res.* 2015; 35(6): 3399–3403.
 88. Sun Lu, Sun X, Li Y, et al. The role of (18)F-FDG PET/CT imaging in patient with malignant PEComa treated with mTOR inhibitor. *Oncotargets Ther.* 2015; 8: 1967–1970, doi: [10.2147/OTT.S85444](https://doi.org/10.2147/OTT.S85444), indexed in Pubmed: 26257526.
 89. Gao F, Huang C, Zhang Y, et al. Combination targeted therapy of VEGFR inhibitor, sorafenib, with an mTOR inhibitor, sirolimus induced a remarkable response of rapid progressive Uterine PEComa. *Cancer Biol Ther.* 2016; 17(6): 595–598, doi: [10.1080/15384047.2016.1167290](https://doi.org/10.1080/15384047.2016.1167290), indexed in Pubmed: 27030639.
 90. Liu TH, Liang CW, Lu LC. Perivascular epithelioid cell tumor of the gastrointestinal tract. *Journal of Cancer Research and Practice.* 2016; 3(1): 14–18, doi: [10.1016/j.jcrpr.2015.10.001](https://doi.org/10.1016/j.jcrpr.2015.10.001).
 91. Binyamin K, Mecz Y, Stein A, et al. An Aggressive Case of Malignant Renal Pecoma Non-Responsive to Motor Inhibition: A Case Report. *Journal of Clinical Case Reports.* 2016; 6(10), doi: [10.4172/2165-7920.1000880](https://doi.org/10.4172/2165-7920.1000880).
 92. Starbuck KD, Drake RD, Budd GT, et al. Treatment of advanced malignant uterine perivascular epithelioid cell tumor with mTOR inhibitors: single-institution experience and review of the literature. *Anticancer Res.* 2016; 36(11): 6161–6164, doi: [10.21873/anticancer.11208](https://doi.org/10.21873/anticancer.11208), indexed in Pubmed: 27793946.
 93. Flechter E, Zohar Y, Guralnik L, et al. Long-lasting stable disease with mTOR inhibitor treatment in a patient with a perivascular epithelioid cell tumor: A case report and literature review. *Oncol Lett.* 2016; 12(6): 4739–4743, doi: [10.3892/ol.2016.5231](https://doi.org/10.3892/ol.2016.5231), indexed in Pubmed: 28105182.
 94. Batereau C, Knösel T, Angele M, et al. Neoadjuvant or adjuvant sirolimus for malignant metastatic or locally advanced perivascular epithelioid cell tumors. *Anti-Cancer Drugs.* 2016; 27(3): 254–258, doi: [10.1097/cad.0000000000000324](https://doi.org/10.1097/cad.0000000000000324).
 95. Shaikh AJ. Malignant Pervascular Epithelioid Cell Tumor (PEComa), Presenting as a Large Intra-Abdominal Mass in a Young Woman: A Case Report and Review of Literature. *Journal of Cancer Prevention & Current Research.* 2016; 4(6), doi: [10.15406/jcpcr.2016.04.00142](https://doi.org/10.15406/jcpcr.2016.04.00142).
 96. Rao S, Pavithra P, Bhat S, et al. Cardiac perivascular epithelioid cell tumor. *World J Pediatr Congenit Heart Surg.* 2017 [Epub ahead of print]: 2150135116682452, doi: [10.1177/2150135116682452](https://doi.org/10.1177/2150135116682452), indexed in Pubmed: 28415905.
 97. Varan A, Bayhan T, Kiratli H, et al. An orbital perivascular epithelioid cell tumor in a 7-year-old boy: case report and review of the literature. *JAAPOS.* 2017; 21(4): 325–328.e1, doi: [10.1016/j.jaapos.2017.05.022](https://doi.org/10.1016/j.jaapos.2017.05.022), indexed in Pubmed: 28576480.
 98. Tang SH, Liu YC, Hsiao HH, et al. Huge soft tissue PEComa with aggressive lung and bone metastases. *Journal of Cancer Research and Practice.* 2017; 4(3): 115–118, doi: [10.1016/j.jcrpr.2017.04.001](https://doi.org/10.1016/j.jcrpr.2017.04.001).
 99. Kwon BSu, Suh DS, Lee NK, et al. Two cases of perivascular epithelioid cell tumor of the uterus: clinical, radiological and pathological diagnostic challenge. *Eur J Med Res.* 2017; 22(1): 7, doi: [10.1186/s40001-017-0248-y](https://doi.org/10.1186/s40001-017-0248-y), indexed in Pubmed: 28270196.
 100. Saluja K, Thomas J, Zhang S, et al. Malignant perivascular epithelioid cell tumor of the oropharynx with strong TFE3 expression mimicking alveolar soft part sarcoma: a case report and review of the literature. *Hum Pathol.* 2018; 76: 149–155, doi: [10.1016/j.humpath.2017.11.016](https://doi.org/10.1016/j.humpath.2017.11.016), indexed in Pubmed: 29208563.

Monika Misztal¹, Magdalena Krakowska¹, Monika Ryś-Bednarska¹, Mariusz Śliwa¹, Piotr Potemski^{1, 2}

¹Copernicus Memorial Multidisciplinary Centre for Oncology and Traumatology, Lodz, Poland

²Chemotherapy Clinic, Oncology Department, Medical University of Lodz, Poland

Symptoms of nervous system damage in a patient undergoing anti-PD1 immunotherapy

Address for correspondence:

Lek. Monika Misztal
WWCOiT im. M. Kopernika w Łodzi
e-mail: misztalmon@gmail.com

Oncology in Clinical Practice
2020, Vol. 16, No. 1, 34–35
DOI: 10.5603/OCP.2020.0006
Translation: dr n. med. Dariusz Stencel
Copyright © 2020 Via Medica
ISSN 2450–1654

ABSTRACT

Symptoms of nervous system damage during immunotherapy with anti-PD1 antibodies occur in approximately 6% of patients. The most commonly reported neurological adverse reactions are Guillain-Barre syndrome, polyneuropathy, demyelinating diseases, myasthenia gravis, and encephalitis.

In the presented patient with disseminated skin melanoma, after four administrations of nivolumab, paraesthesia hindering walking and weakness of the lower limbs appeared. Based on Doppler ultrasound, venous thrombosis was excluded. Computed tomography of the head did not show metastases or signs of intracranial ischaemia or bleeding. The patient was consulted neurologically several times. Steroid therapy, gabapentin, duloxetine, and painkillers were used. Despite the temporary improvement due to implemented treatment, the patient died. No definitive diagnosis could be made, but the symptoms suggest Guillain-Barre syndrome.

Key words: melanoma, nervous system damage, anti-PD1, nivolumab, side effects

Oncol Clin Pract 2020; 16, 1: 34–35

Introduction

Immunotherapy with checkpoint inhibitors is a valuable treatment for various cancers. With the more frequent use of this group of drugs, the frequency of observed side effects also increases. They result from excessive stimulation of the immune system. The most common symptoms affect the skin, digestive system, endocrine organs, and lungs. Neurological disorders and myocarditis are less commonly diagnosed [1]. Nervous system side effects affect approximately 6% of patients treated with anti-PD1 antibodies. The most commonly described are: Guillain-Barre syndrome, polyneuropathy, demyelinating diseases, myasthenia gravis, and encephalitis. Symptoms usually appear between 6 and 13 weeks of treatment [2]. The following is a description of a skin melanoma patient who experienced neurotoxicity symptoms during nivolumab treatment.

Case report

In May 2018, a 68-year-old patient diagnosed with melanoma of the chest skin with metastases to the right axillar and lung lymph nodes, without a mutation in the *BRAF V600* codon, began treatment with nivolumab at the Chemotherapy Clinic in Lodz. The patient was in a good general condition, did not report any complaints, and denied any comorbidities. The physical examination revealed a 7-cm ulcerative skin tumour of the sternal area.

In July, after four antibody administrations, the patient reported paraesthesia in the lower extremities not responding to painkillers, and weakness in the right lower limb, which hindered walking. In laboratory tests and ultrasound Doppler of the lower limbs performed at that time, no abnormalities could be found that could explain the reported symptoms. Due to the severity of

the symptoms, nivolumab treatment was discontinued and steroid therapy with prednisone 1 mg/kg was started, resulting in temporary improvement.

In August, the patient reported worsening of pain. Computed tomography of the head excluded metastases to the central nervous system, ischaemic stroke, and bleeding were. To assess the effectiveness of treatment, computed tomography of the chest, abdomen, and pelvis was performed, which showed the progression of the disease in the lungs and lymph nodes; the picture of the remaining organs remained normal. The patient was consulted neurologically, but apart from a slight paresis of the right lower limb, no abnormalities were found. According to the neurologist's recommendations, magnetic resonance imaging of the lumbosacral spine was planned and gabapentin and duloxetine were added. The prednisone dose was also increased to 2 mg/kg. The drugs used once again allowed for a short-term improvement.

The ailments intensified again in September 2018. The man could barely get up from a chair. In addition, paraesthesia occurred in the upper limbs. The patient was referred to the neurological ward in which he died on October 1, 2018.

Discussion

Guillain-Barré syndrome is an acquired peripheral nerve disease of autoimmune aetiology. The main symptoms are paraesthesia and progressive paresis with abolition or weakness of deep reflexes. These ailments are usually of an ascending nature and are characterised by rapid growth over several days or weeks. The diag-

nosis is based on the clinical picture and abnormalities in EMG (slowdown in conduction in the peripheral nerves) and cerebrospinal fluid test results (characteristic increase in protein concentration with normal cell number). Clinical signs usually precede the changes seen in EMG. In severe cases, with possible biting and swallowing disorders as well as respiratory and circulatory abnormalities, the treatment consists of securing basic life functions. Other patients use plasmapheresis or intravenous immunoglobulin preparations [3]. In the case of idiopathic Guillain-Barré syndrome, the use of glucocorticosteroids is not recommended; however, 1–2 mg/kg of prednisone is indicated in Guillain-Barré syndrome caused by anti-PD1 antibodies [2].

The wide spectrum of side effects of immunotherapy is a challenge for clinicians. In this patient, the symptoms were differentiated from a neurological disease not related to cancer and treatment, paraneoplastic syndrome, venous thrombosis, stroke, and disease progression in the form of central nervous system metastases. Despite the neurological consultation, no diagnosis could be established. As recommended, steroid therapy was used. These symptoms suggest Guillain-Barré syndrome.

References

1. Barquín-García A, Molina-Cerrillo J, Garrido P, et al. New oncologic emergencies: What is there to know about immunotherapy and its potential side effects? *Eur J Intern Med.* 2019; 66: 1–8, doi: [10.1016/j.ejim.2019.05.020](https://doi.org/10.1016/j.ejim.2019.05.020), indexed in Pubmed: 31130304.
2. Haanen J, Carbone F, Robert C, et al. Management of toxicities from immunotherapy: ESMO Clinical Practice Guidelines. *Ann Oncol.* 2017; 28(suppl 4): iv119–iv142.
3. Szczeklik A. *Interna Szczeklika 2012 Podręcznik chorób wewnętrznych.* Kraków 2012.

Róża Poźniak-Balicka^{id}, Dawid Murawa^{id}

University Hospital Karol Marcinkowski in Zielona Góra, Faculty of Medicine and Health Sciences, University of Zielona Góra, Poland

Breast implant-associated anaplastic large cell lymphoma (BIA-ALCL)

Address for correspondence:

Dr n. med. Róża Poźniak-Balicka
 Kliniczny Oddział Radioterapii
 Szpital Uniwersytecki
 im. K. Marcinkowskiego
 ul. Zyty 26, 65-001 Zielona Góra
 e-mail: rozap@interia.pl

Oncology in Clinical Practice
 2020, Vol. 16, No. 1, 36–39
 DOI: 10.5603/OCP.2020.0007

Translation: dr n. med. Dariusz Stencel
 Copyright © 2020 Via Medica
 ISSN 2450-1654

ABSTRACT

Breast implant-associated anaplastic large cell lymphoma (BIA-ALCL) has recently been recognised, and so far approximately 200 cases have been described worldwide. From a histopathological and molecular perspective, it does not differ from classical breast anaplastic large cell lymphoma without ALK kinase expression. However, it has a different clinical course and prognosis, with a five-year survival rate about 92% as compared to 20–50% in patients with the classic form. A 60-year-old female patient had undergone bilateral mastectomy at the age of 45 years due to fibrocystic mastopathy and frequent breast cancer in her family history. Her implants were changed twice due to rupture. In 2018 the patient noticed a growing swelling of the right breast and fluid accumulation in the implant pouch; in September 2018 both implants were removed together, with the pouch also thoroughly removed during the procedure, and other PolyTech implants were inserted. Histological examination revealed the following: breast implant-associated anaplastic large cell lymphoma, immunophenotype: CD30+, ALK–, CD68, PGM–, CKAE1/AE3–, Ki 67 in 90% of cell nuclei. The patient was in very good general condition and without abnormalities in haematological tests. In PET-CT with 18F-FDG (13/12/2018), areas of slightly increased 18F-FDG activity were found in the vicinity of the implants on the right side (SUV max = 1.9) and on the left side (SUV max = 2.3), in addition to left axillary lymph node 12 × 7 × 8 mm (SUV max = 2.0). The patient did not decide to go ahead with the proposed removal of the implants, and a suspicious node was taken for examination — no cancer architecture was found. A control PET-CT test was performed after four months, the result of which was comparable to the previous one. The patient is under observation.

Key words: anaplastic breast lymphoma, breast implant, textured implant

Oncol Clin Pract 2020; 16, 1: 36–39

Introduction

Due to the constantly increasing number of breast reconstructions after mastectomy for breast cancer or other reasons, more and more is being said about the complications of such a procedure. At this point, breast implant-associated anaplastic large cell lymphoma should be remembered. The number of women in whom this malignancy could develop is small. Nevertheless, due to the lack of the possibility to identify women at highest risk, it should be considered as a potential danger for all women with implants. In the US breast anaplastic large cell lymphoma (ALCL) develops in about three out of 100 million women without implants. According to FDA representatives, as many as 60 cases of ALCL

have been identified among women with implants, with their global population estimated at 5–10 million [1].

Breast implant-associated anaplastic large cell lymphoma (BIA-ALCL) was described only recently. The first patient with BIA-ALCA was described in the US in 1997 [2]. In 2011, the US Food and Drug Administration officially issued a warning that breast implants increase the risk of developing ALCL [3]. To date, around 200 cases have been described worldwide [1]. BIA-ALCL belongs to the group of non-Hodgkin's lymphomas (NHLs), which account for only 0.01–0.5% of all malignant breast cancers [5]. Primary NHL of the breast includes primarily B-cell lymphomas, such as diffuse large B-cell lymphoma (DLBCL) or extra-nodal marginal zone lymphoma (MZL) [6]. T-cell lymphomas,

which include BIA ALCL, represent only about 10% of primary NHL of the breast, and ALCL alone accounts for about 3% of all NHL of the breast [7].

From a histopathological and molecular perspective, it does not differ from classical breast anaplastic large cell lymphoma without ALK kinase expression. However, it has a different clinical course and prognosis, with a five-year survival rate of about 92% as compared to 20–50% in patients with the classic form [8].

The disease is not associated with implants from a particular manufacturer or the type of implant filling: silicone or saline. BIA ALCL only accompanies implants with a textured surface. This could be related to a more intense productive as well as inflammatory reaction than with implants with a smooth surface, but the aetiopathogenesis of the disease has not yet been clarified [9]. It is also possible that the cause of the inflammatory reaction and clonal T lymphocyte expansion is the silicone itself or other substances used in the production of the outer shell of the breast implant, e.g. diaminotoluene [7]. Recently, it has been postulated that textured implants act only a passive potentiating factor, and the real aetiological factor of BIA ALCL is the bacterial biofilm around the implant. This biofilm is not detectable by traditional microbiological culture. Texturing of implant surface increases the area on which a biofilm layer can form, which is responsible for the T lymphocyte activation and productive reactions, e.g. capsular contracture [1, 10].

The incidence does not seem to depend on the time elapsed since the implant placement — in the analysed cases it ranged from four months up to 25 years (median 9.3 years) [11] and the average age of patients at the time of diagnosis was about 50 years [12]. The risk of generalised dissemination probably does not depend on the time interval between the onset of symptoms and treatment introduction; in the collected cases this time ranged from a month to two years [11]. Over 80% of patients were diagnosed in stage I according to Ann Arbor classification [1, 13]. The main reason for patients reporting to a physician was breast swelling, with moderate discomfort, without obvious pain. The cause of the symptoms is the formation of a seroma — accumulation of serous exudate under the fibrous capsule of the implant [9]. The volume of seroma varied between 200 and 1000 mL [1, 8, 14]. Occasionally (nine cases) the originally detected lesion was a nodule within the implant's fibrous capsule, which was always accompanied by exudate. In a few cases (six patients), the primary lymphoma tumour was accidentally detected during revision of an implant pouch [1]. The diameter of the nodules ranged from 4 mm to 10 cm (mean 4.4 cm) [1]. In individual cases, BIA ALCL manifested as breast ulceration (three cases) or local lymphadenopathy (three cases), which further led to the detection

of a primary lesion in the implant's fibrous capsule [11]. During further diagnostics, the tumour cells were found simultaneously in the serous exudate and the implant's fibrous capsule, resulting in the cultures being negative in all cases.

The clinical stage of the disease in the documented cases varies greatly — from only single lymphoma cells in the aspirate of serous exudate without any tissue involvement in five patients to the rapid progression of disseminated, refractory disease, being fatal in 9 out of 10 described patients [15]. In most cases the lesions did not exceed the implant's fibrous capsule, and in eight patients local metastases to axillary and mediastinal lymph nodes occurred [11]. One patient had central facial palsy in the course of lymphoma infiltration of the central nervous system [1]. General symptoms specific to lymphomas such as night sweats, fatigue, and weight loss occurred only in five patients [11]. Some speculations were raised about the relationship between aggressive disease course and manifestation of a primary lesion in the form of a nodule [1]. They were not unequivocally confirmed; in Brody's study only in four out of nine patients who died was the primary lesion a palpable breast mass [11], while in Laurent's publication, the presence of a palpable nodule was associated with a two-year survival rate of 52.5% vs. 100% in the group of patients with seroma as the only clinical manifestation [1].

The clinical picture is characteristic. With this in mind, BIA ALCL should be excluded mainly in patients with silicone breast implants, who report to the physician for breast swelling/late seroma (more than one year after implant placement) with no signs of infection or inflammatory exudate despite resolution of inflammation symptoms. Patients with capsular contracture or palpable masses within the implant's fibrous capsule also require increased vigilance [1]. There are no clearly established diagnostics. The material, without fixation, should be sent to a histopathological laboratory, where the diagnosis can be made mainly on the basis of immunohistochemical tests — the presence of CD30 marker and lack of ALK kinase expression are decisive [1]. To exclude lymphoma dissemination, computed tomography of the chest, abdomen, and pelvis is recommended. In high-risk cases, PET-CT with glucose should be performed [1].

Consensus on treatment has also not been reached yet. The disease is most often confined to the implant's fibrous capsule, and in such cases it seems sufficient to remove the implants along with the fibrous capsules and close follow-up [13]. Monitoring should be carried out every six months for five years by performing a breast ultrasound at least every two years [1]. Sentinel node biopsy is not recommended because the implant capsule is drained through several groups of regional lymph

nodes without a constant lymph flow pattern; however, axillary lymph nodes are most often involved in cases of dissemination to regional lymph nodes [16]. In the more advanced stages, complementary chemo- and radiotherapy, and even bone marrow transplantation, could be considered. The most commonly used chemotherapy protocol includes cyclophosphamide, doxorubicin, vincristine, and prednisone (CHOP), but radical surgical resection remains crucial [16].

Case report

A 60-year-old female patient had undergone bilateral mastectomy at the age of 45 years due to fibrocystic mastopathy and frequent breast cancers in her family history. Implants were changed twice due to rupture. In 2004, textured implants were inserted in these places. Due to rupture of the left prosthesis in 2007, both were replaced with new ones. In 2018 the patient reported to the operating surgeon due to growing swelling of the right breast and fluid accumulation in the implant pouch. In September 2018 both implants were removed, together with the pouch, and other PolyTech implants were inserted, in which the micro-polyurethane surface minimises the risk of capsular contracture.

Histological examination: breast implant associated anaplastic large cell lymphoma, immunophenotype: CD30+, ALK-, CD68, PGM-, CKAE1/AE3-, Ki 67 in 90% of cell nuclei.

The patient, in very good general condition, has undergone haematological examination, including bone marrow trepanobiopsy and no abnormalities were found. In PET-CT with 18F-FDG (13/12/2018), areas of slightly increased 18F-FDG activity were found in the vicinity of the implants on the right side (SUV max = 1.9) and on the left side (SUV max = 2.3), in addition left axillary lymph node 12 × 7 × 8 mm (SUV max = 2.0).

In this case, implant removal is recommended as a treatment method.

However, the patient did not agree to such a solution, so only the lymph nodes suspected in PET-CT were taken for histological examination; five reactive lymph nodes were prepared with features of fat loss, sinus histiocytosis, and single polynuclear cells of “around the foreign body” type. There are no explicit features of atypical hyperplasia. Immunohistochemical reactions: CD20 (+ + +) in lymphatic follicle, bcl2 (+) in mantle cells, and Ki 67 (+) 70% in secondary lymphatic follicle. The microscopic image and immunohistochemical profile do not allow the diagnosis of lymphoma.

A control PET-CT test was performed after four months, the result of which was comparable to the previous one. The patient is under observation.

Discussion

Considering the increasing use of breast implants in women treated for breast cancer, and for other reasons, the risk of anaplastic large cell lymphoma associated with such implants should be highlighted. This should not limit the use of this type of surgery, but it certainly requires that the patient be informed about the possibility of such a complication, and informed consent should be obtained for this type of surgery.

BIA ALCL is rare, and accurate assessment of the scale of the problem and epidemiological surveillance is difficult due to low awareness of this issue among physicians.

Because the current incidence is probably underestimated, a uniform international reporting system should be developed.

Physicians monitoring patients after breast implants should be reminded to maintain high oncological alertness in case of late seroma or productive lesions around the breast implant. Treatment should be carried out by multispecialist teams, including haematologists.

References

- Miszczyk JM, Charytonowicz M, Charytonowicz D. Guzek, obrzęk, deformacja piersi — problem dla hematologa? *Onkologia po Dyplomie*. 2016; 05.
- Keech JA, Creech BJ. Anaplastic T-cell lymphoma in proximity to a saline-filled breast implant. *Plast Reconstr Surg*. 1997; 100(2): 554–555, doi: [10.1097/00006534-199708000-00065](https://doi.org/10.1097/00006534-199708000-00065), indexed in Pubmed: [9252643](https://pubmed.ncbi.nlm.nih.gov/9252643/).
- Center for Devices and Radiological Health, U.S. Food and Drug Administration. Anaplastic large cell lymphoma (ALCL) in women with breast implants: preliminary FDA findings and analysis. FDA (online) 2011; <http://www.fda.gov/downloads/MedicalDevices/ProductsandMedicalProcedures/Implant-andProsthetics/BreastImplants/UCM240003.pdf>.
- Talwalkar SS, Miranda RN, Valbuena JR, et al. Lymphomas involving the breast: a study of 106 cases comparing localized and disseminated neoplasms. *Am J Surg Pathol*. 2008; 32(9): 1299–1309, doi: [10.1097/PAS.0b013e318165eb50](https://doi.org/10.1097/PAS.0b013e318165eb50), indexed in Pubmed: [18636016](https://pubmed.ncbi.nlm.nih.gov/18636016/).
- Validire P, Capovilla M, Asselain B, et al. Primary breast non-Hodgkin's lymphoma: a large single center study of initial characteristics, natural history, and prognostic factors. *Am J Hematol*. 2009; 84(3): 133–139, doi: [10.1002/ajh.21353](https://doi.org/10.1002/ajh.21353), indexed in Pubmed: [19199367](https://pubmed.ncbi.nlm.nih.gov/19199367/).
- Gualco G, Chioato L, Harrington WJ, et al. Primary and secondary T-cell lymphomas of the breast: clinico-pathologic features of 11 cases. *Appl Immunohistochem Mol Morphol*. 2009; 17(4): 301–306, doi: [10.1097/PAI.0b013e318195286d](https://doi.org/10.1097/PAI.0b013e318195286d), indexed in Pubmed: [19318917](https://pubmed.ncbi.nlm.nih.gov/19318917/).
- Bizjak M, Selmi C, Praprotnik S, et al. Silicone implants and lymphoma: The role of inflammation. *J Autoimmun*. 2015; 65: 64–73, doi: [10.1016/j.jaut.2015.08.009](https://doi.org/10.1016/j.jaut.2015.08.009), indexed in Pubmed: [26330346](https://pubmed.ncbi.nlm.nih.gov/26330346/).
- Miszczyk J, Charytonowicz M. Anaplastyczny chłoniak wielkokomórkowy związany z implantami piersi (BI A-ALCL) — podsumowanie aktualnego stanu wiedzy. *Chirurgia Plastyczna i Oparzenia*. 2015; 3(4): 169–172, doi: [10.15374/chpio2015008](https://doi.org/10.15374/chpio2015008).
- Eaves F, Nahai F. Anaplastic large cell lymphoma and breast implants: FDA report. *Aesthet Surg J*. 2011; 31(4): 467–468, doi: [10.1177/1090820X11407872](https://doi.org/10.1177/1090820X11407872), indexed in Pubmed: [21551441](https://pubmed.ncbi.nlm.nih.gov/21551441/).
- Jacobs A, Tahir S, Hu H, et al. In vitro and in vivo investigation of the influence of implant surface on the formation of bacterial biofilm in mammary implants. *Plast Reconstr Surg*. 2014; 133(4): 471e–80e, doi: [10.1097/PRS.000000000000020](https://doi.org/10.1097/PRS.000000000000020), indexed in Pubmed: [24675200](https://pubmed.ncbi.nlm.nih.gov/24675200/).
- Brody GS, Deapen D, Taylor CR, et al. Anaplastic large cell lymphoma occurring in women with breast implants: analysis

- of 173 cases. *Plast Reconstr Surg.* 2015; 135(3): 695–705, doi: [10.1097/PRS.0000000000001033](https://doi.org/10.1097/PRS.0000000000001033), indexed in Pubmed: [25490535](https://pubmed.ncbi.nlm.nih.gov/25490535/).
12. Jewell M, Spear SL, Largent J, et al. Anaplastic large T-cell lymphoma and breast implants: a review of the literature. *Plast Reconstr Surg.* 2011; 128(3): 651–661, doi: [10.1097/PRS.0b013e318221db81](https://doi.org/10.1097/PRS.0b013e318221db81), indexed in Pubmed: [21865998](https://pubmed.ncbi.nlm.nih.gov/21865998/).
 13. Miranda RN, Aladily TN, Prince HM, et al. Breast implant-associated anaplastic large-cell lymphoma: long-term follow-up of 60 patients. *J Clin Oncol.* 2014; 32(2): 114–120, doi: [10.1200/JCO.2013.52.7911](https://doi.org/10.1200/JCO.2013.52.7911), indexed in Pubmed: [24323027](https://pubmed.ncbi.nlm.nih.gov/24323027/).
 14. Xu J, Wei S. Breast implant-associated anaplastic large cell lymphoma: review of a distinct clinicopathologic entity. *Arch Pathol Lab Med.* 2014; 138(6): 842–846, doi: [10.5858/arpa.2013-0068-RS](https://doi.org/10.5858/arpa.2013-0068-RS), indexed in Pubmed: [24878027](https://pubmed.ncbi.nlm.nih.gov/24878027/).
 15. Carty MJ, Pribaz JJ, Antin JH, et al. A patient death attributable to implant-related primary anaplastic large cell lymphoma of the breast. *Plast Reconstr Surg.* 2011; 128(3): 112e–118e, doi: [10.1097/PRS.0b013e318221db96](https://doi.org/10.1097/PRS.0b013e318221db96), indexed in Pubmed: [21775924](https://pubmed.ncbi.nlm.nih.gov/21775924/).
 16. Clemens MW, Medeiros LJ, Butler CE, et al. Complete surgical excision is essential for the management of patients with breast implant-associated anaplastic large-cell lymphoma. *J Clin Oncol.* 2016; 34(2): 160–168, doi: [10.1200/JCO.2015.63.3412](https://doi.org/10.1200/JCO.2015.63.3412), indexed in Pubmed: [26628470](https://pubmed.ncbi.nlm.nih.gov/26628470/).