ISSN 2450–1654 | e-ISSN 2450–6478

2024, Vol. 20, Number 1

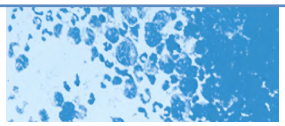

OFFICIAL JOURNAL OF THE POLISH SOCIETY OF CLINICAL ONCOLOGY

Oncology IN CLINICAL PRACTICE

Heba Mohamed El-Zawahry, Ayman Abd Al-Samie Gaber et al.
Vinorelbine plus platinum compared to vinorelbine plus capecitabine in treatment of patients with metastatic triple negative breast cancer previously treated with anthracycline and taxane: a prospective randomized study

Teodoro J. Oscanoa, Edwin Cieza-Macedo, Xavier Vidal, Roman Romero-Ortuno
Evaluation of the Timed Up and Go test for screening vulnerability and frailty in older cancer patients

Monika Durzyńska, Irmina M. Michałek
Pan-TRK immunohistochemistry as a tool in the screening for *NTRK* gene fusions in cancer patients

Datis Kalali
Potassium imbalances induced by systemic cancer therapy: pathophysiology and potential therapeutic strategies

Maryam Zamanian, Iraj Abedi
Convolutional neural networks in auto-segmentation of nasopharyngeal carcinoma tumor — a systematic review and meta-analysis

Emilia Babula, Aleksandra Sikora, Paweł Sobczuk, Piotr Rutkowski
Ripretinib in the treatment of patients with advanced gastrointestinal stromal tumors (GIST)

Aleksandra Piórek, Adam Płużański, Kinga Winiarczyk et al.
Tracheal cancers

Kenneth Grenis Vargas Ponce, Claudia Meléndez Dávila, Juan Antonio Salas Lopez et al.
Pulmonary tuberculosis as a differential diagnosis of a pulmonary nodule: the great masquerader

Chi Truong Nguyen, Ngoc Hieu Nguyen, Van Nguyen Huong et al.
A rare case report on bilateral scrotal lipoma — the largest tumor in Vietnam

Jolanta Dobrzańska, Paweł Potocki, Piotr J. Wysocki
Do solitary pancreatic metastases of renal-cell carcinoma indicate an indolent disease with a strong indication for aggressive local treatment? A case report with literature review

Maria Rozpłoch-Sapa, Patrycja Mrowczyk, Łukasz Kwinta et al.
Low-grade serous ovarian cancer with *BRAF*^{V600E} mutation treated with metronomic chemotherapy — a case report and literature review

Under the patronage of

Polska Grupa Raka Płuca

Polskie Towarzystwo Radioterapii Onkologicznej

VIA MEDICA

ONCOLOGY
IN CLINICAL PRACTICE

Official Journal of the Polish Society of Clinical Oncology, under the patronage of the Polish Lung Cancer Group (PLCG) and Polish Society of Radiation Oncology (PSRO)

https://journals.viamedica.pl/oncology_in_clinical_practice

Editor-in-Chief
prof. dr hab. n. med. Maciej Krzakowski

Deputy Editors
prof. dr hab. n. med. Anna M. Czarnecka
prof. dr hab. n. med. Andrzej Kawecki
prof. dr hab. n. med. Dariusz M. Kowalski
dr hab. n. med. Tomasz Kubiatowski, prof. UWM
prof. dr hab. n. med. Piotr Potemski
dr hab. n. med. Barbara Radecka
prof. dr hab. n. med. Piotr Rutkowski
prof. dr hab. n. med. Piotr Wysocki

Scientific Board
dr Edita Baltruskeviciene (Vilnius, Lithuania)
prof. Tomasz M. Beer (Portland, USA)
prof. Bartosz Chmielowski (Los Angeles, USA)
dr n. med. Rafał Czyżykowski
dr hab. n. med. Joanna Didkowska
prof. dr hab. n. med. Renata Duchnowska
dr Rick Haas (Leiden, The Netherlands)
dr hab. n. med. Beata Jagielska
dr n. med. Jerzy Jarosz
prof. dr hab. n. med. Jacek Jassem
prof. dr hab. n. med. Arkadiusz Jeziorski
dr hab. n. med. Ewa Kalinka, prof. ICZMP
prof. dr hab. n. med. Radzisław Kordek
lek. Łukasz Kwinta
dr hab. n. med. Maria Litwiniuk, prof. UMP
dr n. med. Aleksandra Łacko
dr hab. n. med. Iwona Ługowska, prof. NIO-PIB
prof. Ruggero De Maria (Rome, Italy)
prof. Mario Mandala (Perugia, Italy)
dr hab. n. med. Radosław Mądry
dr n. med. Janusz Meder
prof. dr hab. n. med. Sergiusz Nawrocki
dr hab. n. med. Anna Niwińska, prof. NIO-PIB
prof. dr hab. n. med. Włodzimierz Olszewski
dr hab. n. med. Adam Płużański
prof. dr hab. n. med. Maria Podolak-Dawidziak
prof. dr hab. n. med. Jarosław Reguła
prof. dr hab. n. med. Tadeusz Robak
prof. dr hab. n. med. Kazimierz Roszkowski
prof. dr hab. n. med. Janusz Siedlecki
prof. dr hab. n. med. Ewa Sierko
dr Silvia Stacchiotti (Milan, Italy)
dr Ryszard Szydło (London, UK)
prof. dr hab. n. med. Jerzy Walecki
prof. dr hab. n. med. Jan Walewski
prof. dr hab. n. med. Krzysztof Warzocha
prof. dr hab. n. med. Marek Wojtukiewicz
prof. Agnieszka Wozniak (Leuven, Belgium)
prof. Christoph Zielinski (Vienna, Austria)

Managing Editor
Aleksandra Cielecka

Opinions presented in the articles do not necessarily represent the opinions of the Editors

Oncology in Clinical Practice (ISSN 2450–1654, e-ISSN 2450–6478) is published six times a year by

VM Media Group sp. z o.o.
ul. Świętokrzyska 73, 80–180 Gdańsk, Poland
Phone: (+48 58) 320 94 94, fax: (+48 58) 320 94 60
e-mail: viamedica@viamedica.pl,
http://www.viamedica.pl

23-0661.001.001

Editorial Address

Klinika Nowotworów Płuca i Klatki Piersiowej
Narodowy Instytut Onkologii im. Marii Skłodowskiej-Curie — Państwowy Instytut Badawczy
ul. Roentgena 5, 02–781 Warszawa, Poland
Phone: (+48 22) 546 21 69
e-mail: sekretariat4@pib-nio.pl

Advertising

For details on media opportunities within this journal please contact the advertising sales department, ul. Świętokrzyska 73, 80–180 Gdańsk, Poland, phone: (+48 58) 320 94 94; e-mail: dsk@viamedica.pl

The Editors accept no responsibility for the advertisement contents.

All rights reserved, including translation into foreign languages. No part of this periodical, either text or illustration, may be used in any form whatsoever. It is particularly forbidden for any part of this material to be copied or translated into a mechanical or electronic language and also to be recorded in whatever form, stored in any kind of retrieval system or transmitted, whether in an electronic or mechanical form or with the aid of photocopying, microfilm, recording, scanning or in any other form, without the prior written permission of the publisher. The rights of the publisher are protected by national copyright laws and by international conventions, and their violation will be punishable by penal sanctions.

Legal note: http://czasopisma.viamedica.pl/owpk/about/legalNote

Indexed in Index Copernicus, Ulrich's Periodicals Directory and CAS. Current Impact Factor of "Oncology in Clinical Practice" (2022) is 0.5.

According to the statement of the Polish Ministry of Education and Science publication in the journal has been awarded with 100 points.

Editorial policies and author guidelines are published on journal website: http://journals.viamedica.pl/oncology_in_clinical_practice

VM Copyright © 2024 Via Medica

ONCOLOGY
IN CLINICAL PRACTICE

Official Journal of the Polish Society of Clinical Oncology, under the patronage of the Polish Lung Cancer Group (PLCG) and Polish Society of Radiation Oncology (PSRO)

https://journals.viamedica.pl/oncology_in_clinical_practice

2024, Vol. 20, Number 1

ORIGINAL ARTICLES

Vinorelbine plus platinum compared to vinorelbine plus capecitabine in treatment of patients with metastatic triple negative breast cancer previously treated with anthracycline and taxane: a prospective randomized study

Heba Mohamed El-Zawahry, Ayman Abd Al-Samie Gaber, Amany Abd-Elhameed Abou-Bakr, Marwa Nabil Abd-Elhafez, Ahmed Mohamed El-Debawy 1

Evaluation of the Timed Up and Go test for screening vulnerability and frailty in older cancer patients

Teodoro J. Oscanoa, Edwin Cieza-Macedo, Xavier Vidal, Roman Romero-Ortuno 9

REVIEW ARTICLES

Pan-TRK immunohistochemistry as a tool in the screening for *NTRK* gene fusions in cancer patients

Monika Durzyńska, Irmina M. Michałek 15

Potassium imbalances induced by systemic cancer therapy: pathophysiology and potential therapeutic strategies

Datis Kalali 22

Convolutional neural networks in auto-segmentation of nasopharyngeal carcinoma tumor — a systematic review and meta-analysis

Maryam Zamanian, Iraj Abedi 27

Ripretinib in the treatment of patients with advanced gastrointestinal stromal tumors (GIST)

Emilia Babula, Aleksandra Sikora, Paweł Sobczuk, Piotr Rutkowski 40

Tracheal cancers

Aleksandra Piórek, Adam Płużański, Kinga Winiarczyk, Sylwia Tabor, Magdalena Knetki-Wróblewska, Dariusz Mirosław Kowalski, Maciej Krzakowski 52

CASE REPORTS

Pulmonary tuberculosis as a differential diagnosis of a pulmonary nodule: the great masquerader

Kenneth Grenis Vargas Ponce, Claudia Meléndez Dávila, Juan Antonio Salas Lopez, Félix Llanos Tejada 60

A rare case report on bilateral scrotal lipoma — the largest tumor in Vietnam

Chi Truong Nguyen, Ngoc Hieu Nguyen, Van Nguyen Huong, Ngoc Tran Pham, Thai Chan Nguyen 64

Do solitary pancreatic metastases of renal-cell carcinoma indicate an indolent disease with a strong indication for aggressive local treatment? A case report with literature review

Jolanta Dobrzańska, Paweł Potocki, Piotr J. Wysocki 68

Low-grade serous ovarian cancer with *BRAF*^{V600E} mutation treated with metronomic chemotherapy — a case report and literature review

Maria Rozpłoch-Sapa, Patrycja Mrowczyk, Łukasz Kwinta, Mateusz Łobacz, Paweł M. Potocki 71

ERRATUM 77

Professor Krzysztof Krzemieniecki Award for the best case report accepted for publication

Case Report Contest Policies

This policy defines the scope, requirements and regulations regarding **The Krzysztof Krzemieniecki Award** for the best case report published in "Oncology in Clinical Practice" (OCP) 8th Edition.

1. The aim of the contest is to encourage submission of quality case reports and clinical vignettes related to oncological practice and to promote them in the scientific deliberations.
2. All respective manuscripts submitted to OCP between June 1, 2023 and May 31, 2024 and accepted for publication will qualify.
3. Manuscripts should be prepared in line with Authors' guidelines and should be submitted only through the manuscript system available at Journal's website: https://journals.viamedica.pl/oncology_in_clinical_practice
4. All submitted manuscripts will be evaluated during the peer review process and authors will be informed about their qualification for publication in OCP. Accepted papers will be evaluated by the Contest Committee based upon fulfillment of the Contest criteria as well as practical significance, originality, applicability and addressing of current/critical concerns.
5. The first author of the winning paper will be eligible for a prize of gross 1000,00 Euro gross (one thousand euro).
6. Results will be announced during the XXVIII National Congress of The Polish Society of Clinical Oncology and subsequently at the Journal website.
7. Winner will be notified via email.
8. Contest Committee may exclude a paper from participation in case of potential conflict of interest or ask submitting author for adequate clarifications.
9. The Sponsor at any stage and in any respect, will not participate in the evaluation of entries and selection of a winning paper.
10. The award amount shall be paid based on the copyright transfer agreement to the paper.
11. These Regulations are the sole and exclusive document defining the principles and conditions for the Contest. In all matters not regulated, decisions are made by The Organizer.

Contest Organizer:
VM Media Group sp. z o.o., seated at 73 Swietokrzyska Street, 80–180 Gdansk, Poland (Register of Entrepreneurs kept by the District Court for Gdansk, Commercial Division VII of the National Court Register under KRS No. 0000266430, VAT Reg. No. PL 583-28-39-187).

Patronage NOVARTIS

VIA MEDICA

ORIGINAL ARTICLE

Heba Mohamed El-Zawahry, Ayman Abd Al-Samie Gaber, Amany Abd-Elhameed Abou-Bakr, Marwa Nabil Abd-Elhafez, Ahmed Mohamed El-Debawy

National Cancer Institute, Cairo University, Cairo, Egypt

Vinorelbine plus platinum compared to vinorelbine plus capecitabine in treatment of patients with metastatic triple negative breast cancer previously treated with anthracycline and taxane: a prospective randomized study

Address for correspondence:
Ahmed Mohamed El-Debawy, MD
Department of Medical Oncology,
National Cancer Institute, Cairo University,
Fom-El-Khaleg, Kornish El-Nile,
11796 Cairo, Egypt
e-mail: eldebawyahmed@gmail.com

Oncology in Clinical Practice
DOI: 10.5603/ocp.96278
Copyright © 2024 Via Medica
ISSN 2450–1654
e-ISSN 2450–6478

ABSTRACT

Introduction. This study aims to investigate the efficacy and tolerability of the vinorelbine-based combination chemotherapy with either cisplatin or capecitabine in metastatic triple-negative breast cancer (mTNBC) pretreated with anthracycline and taxane.

Material and methods. This is an open-labeled randomized prospective single-institute study, that included all patients who received chemotherapy for mTNBC in the period between 1st of July 2016 and 30th of June 2017 and were pretreated with anthracycline and taxane. Patients were randomized to either vinorelbine 25 mg/m^2 i.v. on days 1 and 8 plus oral capecitabine 1000 mg/m^2 twice daily, on days 1–14 (NX); or vinorelbine 25 mg/m^2 i.v. on days 1 and 8 plus cisplatin 75 mg/m^2 (NP), every 21 days. The primary endpoint was time to progression (TTP), whereas the secondary endpoints were objective response rate (ORR), safety, and overall survival (OS).

Results. Median TTP was 9.9 months with NP *vs.* 8 months with NX, ($p = 0.22$). ORR was 40% with NP *vs.* 36% with NX, ($p = 0.77$). Median OS was 13 months with NP *vs.* 13.2 months with NX ($p = 0.599$). Both regimens demonstrated similar rates of grade ≥ 3 vomiting and neutropenia. A higher incidence of thrombocytopenia, tinnitus, and kidney function alteration were reported with NP. A higher incidence of anorexia, diarrhea, mucositis, and hand-foot syndrome were reported with NX.

Conclusions. Vinorelbine-based combination chemotherapy regimens with either cisplatin or capecitabine are active in the treatment of mTNBC pretreated with anthracycline and taxane with manageable toxicity profiles. Both regimens have comparable TTP, ORR, OS, and safety profiles.

Keywords: triple-negative breast cancer, chemotherapy, vinorelbine, cisplatin, capecitabine, platinol, Egypt
Oncol Clin Pract 2024; 20, 1: 1–8

Introduction

According to the clinical classification, triple-negative breast cancer (TNBC) is defined by negative estrogen receptor (ER), progesterone receptor (PR), and human epidermal growth factor receptor-2 (HER-2) [1]. Metastatic triple-negative breast cancer (mTNBC) exhibits more heterogeneity and genetic complexity as compared to early disease [2]. Patients with mTNBC have poor clinical outcomes and a high incidence of visceral and brain metastases [3–5].

Received: 04.07.2023 Accepted: 18.08.2023 Early publication date: 18.09.2023

This article is available in open access under Creative Common Attribution-Non-Commercial-No Derivatives 4.0 International (CC BY-NC-ND 4.0) license, allowing to download articles and share them with others as long as they credit the authors and the publisher, but without permission to change them in any way or use them commercially.

Despite efforts to classify TNBC and dynamic biomarker development, only PD-L1 is applied in clinical practice as a validated biomarker for response to immune checkpoint inhibitor anti-PDL-1 atezolizumab plus nab-paclitaxel in tumors expressing PD- L1 ≥ 1 [6, 7] and anti-PD-1 pembrolizumab plus chemotherapy (nab-paclitaxel, paclitaxel, or gemcitabine-carboplatin) in tumors with combined positive score ≥ 10 [8, 9]. Also, germline breast cancer susceptibility gene (gBRCA) mutations in HER-2 negative metastatic breast cancer are targets for Poly [adenosine diphosphate (ADP)-Ribose] Polymerase 1 inhibitor (PARPis) olaparib [10], and talazoparib [11], and most patients are treated with chemotherapy [12]. Combination chemotherapy could be preferred in cases of imminent organ failure mTNBC [13].

Antibody-drug conjugate (ADC) sacituzumab govitecan that directs the active metabolite of irinotecan to cells expressing trophoblast cell surface antigen 2 (Trop-2), which is highly expressed in TNBC, has led to an improvement in outcomes in mTNBC patients who have received two or more prior systemic therapies and at least one of them for metastatic disease with manageable safety profile [14, 15]. The classification of HER-2 negativity expression including IHC 0 and HER2-low IHC 1+ or IHC2+ with ISH negative, make tumors with HER2-low attractive targets for the newer generation of HER-2 directed ADC trastuzumab deruxtecan with improved outcomes [16]. Also, the clinical benefit of sacituzumab govitecan in mTNBC patients was consistent, regardless of their HER2 status [17].

The effect of re-challenge with anthracyclines and taxane in mTNBC might be limited due to drug resistance, as most patients have been treated with them before as part of neoadjuvant/adjuvant chemotherapy [18]. Vinorelbine is a mitotic spindle poison with no cross-resistance to anthracyclines and taxanes [19, 20] and is recommended as a sequential single agent in metastatic breast cancer (mBC) [13]. It has single-agent activity with an objective response rate (ORR) ranging from 25% to 45% in heavily pretreated mBC patients [21].

The rationale for including platinum agents is supported by the fact that: 1) most breast cancers, in the setting of germline BRCA1 mutation, are triple negative; 2) some TNBC have some BRCA characteristics resulting in faulty DNA repair pathways; 3) platinum-based chemotherapy is associated with progression-free survival (PFS) benefit in patients with MBC and gBRCA mutation [22, 23].

The rationale for including the anti-metabolite capecitabine is supported by its tolerability, clinical benefit, and superiority when tested, as first-line chemotherapy of mBC, in patients pretreated with anthracycline and taxane [24].

Our study aimed to investigate the efficacy and tolerability of the vinorelbine-based combination chemotherapy with either cisplatin or capecitabine in mTNBC patients previously treated with anthracycline and taxane.

Material and methods

Female patients aged > 18 years with histologically confirmed mTNBC (defined by lack of ER, PR, HER2-neu on biopsies of the primary and confirmed by a biopsy of the metastatic site), previously treated with anthracyclines and taxane in a neo/adjuvant setting were eligible for inclusion in this open-labeled prospective randomized single-institute study. Prior chemotherapy or taxane re-challenge in the metastatic setting was permitted. The present study has included all eligible patients who received chemotherapy for mTNBC in the period from 1st of July 2016 to 30th of June 2017. Other inclusion criteria included adequate organ function, measurable disease by Response Evaluation Criteria in Solid Tumors version 1.1 (RECIST v1.1) [25], and performance status of 2 or better on the Eastern Cooperative Oncology Group (ECOG) scale. Patients with brain metastasis, or with non-measurable disease were excluded. Patients aged 65 years or over were excluded because it is the chronological age that needs geriatric assessment [26].

Patients were randomized using permuted blocks to receive a combination of vinorelbine 25 mg/m^2 on days 1 and 8 and oral capecitabine 1000 mg/m^2 twice daily on days 1–14 every 21 days (NX regimen) or vinorelbine 25 mg/m^2 on day 1 and 8 and cisplatin 75 mg/m^2 on day 1 every 21 days (NP regimen) for up to 6 cycles, until progression or unacceptable toxicity.

Tumor response was assessed clinically every cycle, and computed tomography (CT) scans were required every two months. X-ray, bone scan, magnetic resonance imagining (MRI), and biopsy were required when indicated.

The primary endpoint was time to progression (TTP), whereas the secondary endpoints were objective response rate, safety, and overall survival (OS). Time to progression is the period from the first day of treatment to progression. The objective response rate was calculated as the number of patients with the best overall response of confirmed complete response (CR) or partial response (PR) according to RECIST v1.1. divided by the total number of patients in the group. Patients were evaluated for adverse events throughout the treatment period and were graded using NCI Common Terminology Criteria for Adverse Events v.4.03 [27].

Results

Patient characteristics

By June 30, 2017, fifty female patients with mTNBC had been enrolled, randomized, and treated. Thirty-seven patients received vinorelbine combination first-line chemotherapy of mTNBC, while 13 patients received vinorelbine combination second-line chemotherapy of mTNBC after progression on paclitaxel-carboplatin

Table 1. Patients baseline characteristics in both arms — vinorelbine plus capecitabine (NX) regimen and vinorelbine plus cisplatin (NP) regimen

Patients characteristics	NX (n = 25)	NP (n = 25)	p
Age			
Mean ± SD	47.8 ± 8.7	50 ± 9.4	0.41
Median (range)	50 (30–62)	49 (30–64)	
Age Groups			
≤ 45	10 (40%)	8 (32%)	0.76
>45	15 (60%)	17 (68%)	
Menopausal status			
Pre	14 (56%)	12 (48%)	0.77
Post	11 (44%)	13 (52%)	
Type of initial surgery			
MRM	18 (72%)	20 (80%)	0.50
BCS	7 (28%)	5 (20%)	
Histological subtype			
IDC	24 (96%)	22 (88%)	0.28
Others*	1 (4%)	3 (12%)	
T-stage at primary diagnosis			
T0	1 (4%)	0	0.62
T1	3 (12%)	3 (12%)	
T2	18 (72)	19 (76%)	
T3	2 (8%)	3 (12%)	
T4	1 (4%)	0	
N-stage at primary diagnosis			
N0	7 (28%)	7 (28%)	0.11
N1	2 (8%)	8 (32%)	
N2	11 (44%)	5 (20%)	
N3	5 (20%)	5 (20%)	
AJCC TNM at primary diagnosis			
IA	0	1 (4%)	0.22
IIA	6 (24%)	8 (32%)	
IIB	2 (8%)	6 (24%)	
IIIA	10 (40%)	5 (20%)	
IIIB	1 (4%)	0	
IIIC	5 (20%)	5 (20%)	
Prior local recurrence	7 (32%)	7 (32%)	1
Prior regimen for MBC			
0	18 (72%)	19 (76%)	0.75
1	7 (28%)	6 (24%)	
Number of metastatic sites			
1	5 (20%)	8 (32%)	0.542
2	15 (60%)	14 (56%)	
≥ 3	5 (20%)	3 (12%)	
Type of metastasis			
Visceral	10 (40%)	12 (48%)	0.83
Non-visceral	4 (16%)	4 (16%)	
Both	11 (44%)	9 (36%)	
Site of disease (multiple sites are possible)			
Lung	14 (56%)	17 (68%)	0.382
Liver	13 (52%)	11 (44%)	0.571
Lymph nodes	10 (40%)	6 (24%)	0.225
Chest wall	7 (28%)	5 (20%)	0.758
Pleural	4 (16%)	3 (12%)	0.666
Bone	7 (24%)	6 (24%)	0.747

*Others included metaplastic, medullary, and adenoid cystic carcinoma; AJCC TNM — American Joint Committee On Cancer; BCS — breast conserving surgery; IDC — invasive ductal carcinoma; M — metastasis; MRM — modified radical surgery; MBC — metastatic breast cancer; N — node; SD — standard deviation

(6 patients), paclitaxel weekly (5 patients), and gemcitabine-carboplatin (2 patients). The median age of the total population was 49.5 years (range 30–64 years). HER-2 negative expressions including IHC 0 and HER2-low (IHC 1+ or IHC2+ with ISH negative), were equal in both treatment arms, and accounted for 72%, and 28% in each group, respectively. Table 1 illustrates patient characteristics in both groups.

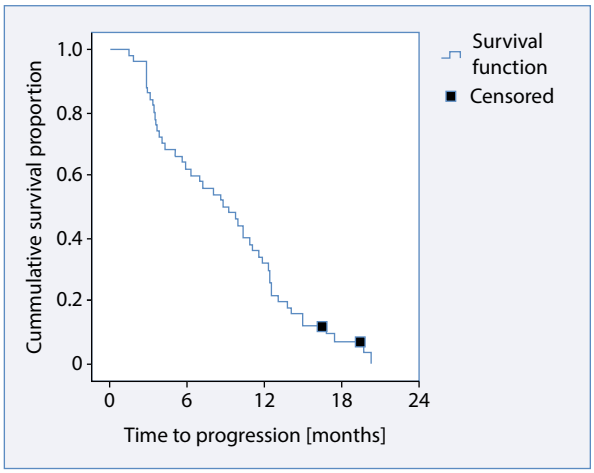

Figure 1. Time to progression of the total population

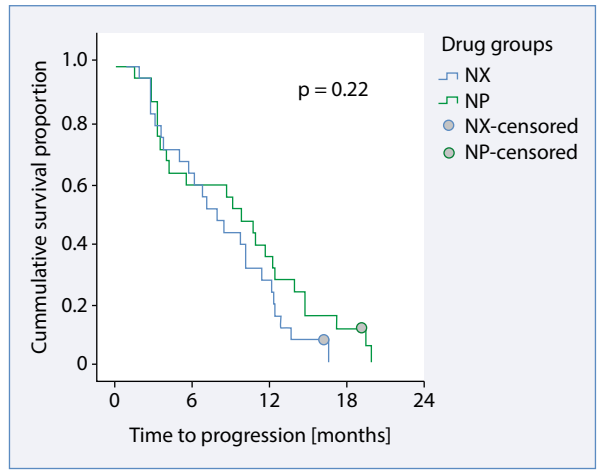

Figure 2. Time to progression of vinorelbine plus capecitabine (NX) regimen compared with vinorelbine plus cisplatin (NP) regimen

Safety

Twenty-five patients received a total of 131 NX cycles (range 2–6 cycles). Vinorelbine doses were delayed in 19 patients during their course of treatment due to neutropenia. Amongst them, 11 patients (44%) received granulocyte colony-stimulating factor (G-CSF) secondary prophylaxis due to grade 3 (< 1000–500/mm^3) or 4 (< 500/mm^3) neutropenia. Vinorelbine doses were reduced by 25% in 5 patients (20%) due to persistent grade 3 neutropenia after G-CSF secondary prophylaxis.

Capecitabine doses were interrupted in 10 patients (40%) during their course of treatment and continued at 75 % of the initial starting dose due to either grade 2 or 3 non-hematological toxicity (vomiting, hyperbilirubinemia, increased creatinine, hand food syndrome, neutropenia, oral mucositis, and diarrhea) using NCI Common Terminology Criteria for Adverse Events v.4.03 [27].

Twenty-five patients received a total of 133 NP cycles (range 2–6 cycles). Vinorelbine doses were delayed in 22 patients during their course of treatment due to neutropenia. Amongst them, 13 patients (52%) received G-CSF secondary prophylaxis due to grade 3 or 4 neutropenia. Vinorelbine doses were reduced by 25% in 3 patients (12%) due to persistent grade 3 neutropenia after G-CSF secondary prophylaxis. The dose of cisplatin was reduced by 25% in 12 patients (48%) if serum creatinine was between 1.5 to 2 mg/dL but creatinine clearance was ≥ 50 mL/min. Cisplatin was stopped in one patient because creatinine clearance was < 50 mL/min.

Time to progression

The median TTP of 50 patients who received vinorelbine-based therapy was 8.7 months (95% CI 5.5–11.8), and TPP at 1 year was 41% (Fig. 1).

The median TTP of the NP group was numerically higher than in the NX group; however, it was not statistically significant [9.9 months (95% CI 6.4–13.3) *vs.* 8 months (95% CI 5–10.7)], respectively. TTP at 1 year was 56% and 52% for the NP and NX regimens, respectively (p = 0.22) (Fig. 2).

Objective response rate

For the total population, the ORR was 38%, including 1 CR and 18 PR. The ORR was 40 % with the NP regimen included (1 CR and 9 PR,) and 36% with the NX regimen included (9 PR) (p = 0.77).

Overall survival

Median OS of 50 patients who received vinorelbine-based therapy was 13 months (95% CI 12–14), and OS at 1 year was 57%. (Fig. 3).

Median OS was similar in both groups, 13 months (95% CI, 11.6–14.4) *vs.* 13.2 months (95% CI 9.5–16.8). OS at 1 year was 62% and 56% for the NP and NX regimens, respectively (p = 0.599) (Fig. 4).

Toxicity

The most predominant grade 1 or 2 adverse events (AEs) reported were hematological (anemia 62% *vs.* 76%, neutropenia 48% *vs.* 48%, and thrombocytopenia 40% *vs.* 68% in the NX and NP regimens, respectively), gastrointestinal (anorexia 72% *vs.* 76%, nausea/vomiting 62% *vs.* 60%, diarrhea 48% *vs.* 32%, oral mucositis 48% *vs.* 24%, elevated bilirubin 20% *vs.* 16%, elevated transaminases 24% *vs.* 8%, in the NX and NP regimens, respectively). Other grades 1 or 2 AEs were peripheral neuropathy 80% *vs.* 68%, creatinine

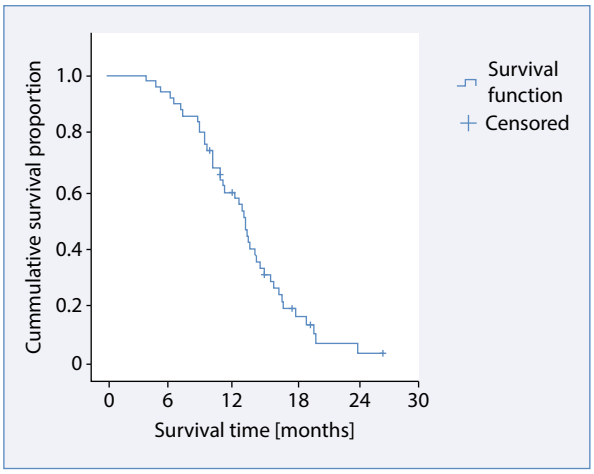

Figure 3. Overall survival of the total population

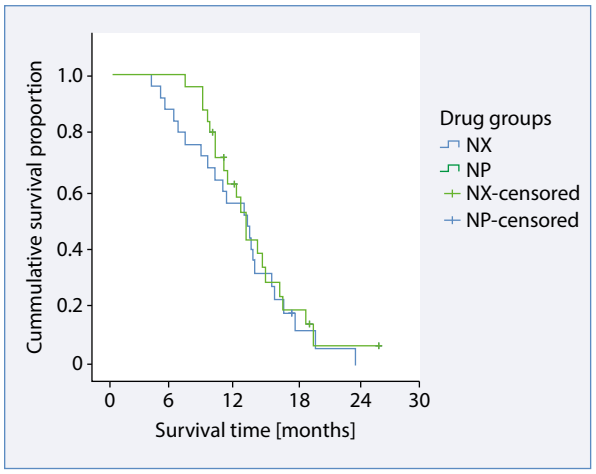

Figure. 4. Overall survival of vinorelbine plus capecitabine (NX) regimen compared with vinorelbine plus cisplatin (NP) regimen

Table 2. The highest grade (G) the of most common adverse event reported at any time

Adverse event*	NX (n = 25)				NP (n = 25)			
	G1 [%]	G2 [%]	G3 [%]	G4 [%]	G1 [%]	G2 [%]	G3 [%]	G4 [%]
N/V	8	54	28	4	24	36	32	4
Diarrhea	24	24	–	–	28	4	4	–
Oral mucositis	28	20	–	–	8	16	–	–
Neutropenia	16	32	40	4	12	36	40	12
Anemia	20	42	16	–	28	48	12	–
Thrombocytopenia	28	12	12	–	48	20	4	–
Neuropathy	48	32	4	–	40	28	12	–
Anorexia	28	44	4	–	40	36	–	–
Creatinine increased	48	8	–	–	48	–	4	–
Hypocalcemia	28	4	–	–	24	16	4	–
Hypercalcemia	12	4	–	–	4	4	–	–
Elevated transaminases	24	–	–	–	8	–	–	–
Elevated bilirubin	16	4			16	–		
Hand foot syndrome	24	8	–	–	–	–		
Extravasation	–	12	–	–	–	16	–	–
Tinnitus	8					32		
A. Fibrillation	–	4	–	–	–	–	–	–
Decreased EF	–	4	–	–	–	–	–	–

*NCI Common Terminology Criteria for Adverse Event version 4.03 was utilized; A. fibrillation — atrial fibrillation; EF — ejection fraction; NP — vinorelbine plus cisplatin; NX — vinorelbine plus capecitabine; N/V — nausea/vomiting;

increase from baseline 56% *vs.* 48%, hypocalcemia 32% *vs.* 40%, tinnitus 8% *vs.* 32%, and hand-foot syndrome 32% *vs.* 0%, in the NX and NP regimens, respectively (Tab. 2).

Higher incidences of thrombocytopenia, anemia, hypocalcemia, and tinnitus were reported in the NP compared to the NX arm.

A higher incidence of any grade of diarrhea, oral mucositis, hand-foot syndrome, and elevation of transaminases was reported in the NX regimen in comparison to the NP regimen.

Grade 3/4 AE reported in > 20% of patients were nausea/vomiting and neutropenia, which were not statistically significantly different between the two regimens (Tab. 3).

Table 3. Grade (G) 3/4 adverse events reported in > 20% of patients

Adverse event*	NX (n = 25)	NP (n = 25)	p
Nausea/vomiting	8 (32%)	9 (36%)	0.76
Neutropenia G3	11 (44%)	13 (52%)	0.57
Neutropenia G4	1 (4%)	3 (12%)	0.28

*NCI Common Terminology Criteria for Adverse Event version 4.03 was utilized; NP — vinorelbine plus cisplatin; NX — vinorelbine plus capecitabine

Other grades 3 AE reported in < 20% of patients were anemia (16% *vs.* 12%), thrombocytopenia (12% *vs.* 4%), neuropathy (4% *vs.* 12%), anorexia (4% *vs.* 0%), diarrhea (0% *vs.* 4%), hypocalcemia (0% *vs.* 4%) and creatinine increase (0% *vs.* 4%), in the NX and NP regimens, respectively.

Discussion

In the current study, the median TTP was 1.9 months longer in the vinorelbine-cisplatin (NP) group (9.9 months) compared to 8 months in the vinorelbine-capecitabine (NX) group; but the difference was not statistically significant (p = 0.22). ORR was numerically higher with NP 40% *vs.* 36% with NX (p = 0.77) but not statistically significant. Median OS was similar in both groups, 13 *vs.* 13.2 months, and OS at 1 year was 62% and 56% for the NP regimen and NX regimen, respectively (p = 0.599), compared to OS reported by Du et al. [28] in a retrospective analysis of 48 mTNBC patients who received NP *vs.* NX and were pretreated with anthracyclines and taxanes (PFS = 5.3 *vs.* 3.0 months; p = 0.023), (ORR = 33.8% *vs.* 7.7%; p = 0.029), and (OS = 27.7 *vs.* 14.8 months; p = 0.077). Our observed TTP rate was higher than that reported by Hu et al. [29] for gemcitabine — cisplatin *vs.* gemcitabine-paclitaxel (PFS = 7.73 *vs.* 6.47 months).

Key grade > 3 AEs were mainly vomiting and neutropenia, other grade 3 AEs reported were neuropathy, anemia, thrombocytopenia, and diarrhea. All these grade 3 AEs were manageable, no treatment-related death and no neutropenic fever were reported. Only 2 patients required unplanned hospitalization. One because of grade 4 vomiting and grade 3 diarrhea in the NX arm, and the other one because of grade 3 hypocalcemia in the NP arm. However, some patients required a 25% reduction in vinorelbine dose because of persistent grade 3 or 4 neutropenia after G-CSF prophylaxis which were numerically higher in NX than NP arm. Moreover, about one-fourth of patients required a 25% dose reduction in cisplatin dose due to an increase in creatinine 1.5–2 mg/dL. Only one patient stopped cisplatin because of creatinine clearance < 50 mg. Capecitabine was interrupted in 40% of patients due to grade 2 or 3 non-hematological AEs, mostly vomiting, diarrhea, and oral mucositis.

Nevertheless, dose reduction limited toxicity, and patients on both regimes in our study benefited from the alleviation of symptoms associated with mTNBC, such as dyspnea, pain, chest wall masses, and compression symptoms. This highlights the advantage of both treatment regimens and their potential, especially when they are used to achieve a rapid response, for example, in the setting of a visceral crisis and imminent organ failure. In our study, vomiting and neutropenia in both arms, diarrhea, loss of appetite and hand-foot syndrome in the NX arm, and drowsiness, thrombocytopenia and kidney function alteration in the NP arm were all manageable.

A limitation of our study is the small study group and its single-center character. Also, at the time when the study began in 2016, performing germinal BRCA mutation testing and PD-L1 assay was not often required to make treatment decisions. Another limitation of our study is the absence of analysis of patient-reported quality of life using a highly validated cancer-specific instrument.

Conclusions

Vinorelbine-based combination chemotherapy regimens with either cisplatin or capecitabine are active in the treatment of mTNBC pretreated with anthracycline and taxane with manageable toxicity profiles. Both regimens have comparable TTP, ORR, OS, and safety profiles.

Article Information and Declarations

Data availability statement

The dataset used and analyzed during the current study is available from the corresponding author on reasonable request

Ethics statement

The study was approved by the institutional review board of the Egyptian National Cancer Institute, Cairo University, organization No. IORG0003381, IRB

No. IRB00004025, FWA No. 00007284, approval No. 201516044.3, the study was constituted and operated according to ICH-GCP guidelines and complied with the declaration of Helsinki. Written informed consent to participate in the study was obtained from all patients. Results and other study material was not included items that reveal the identities of the patients.

Author contributions

AMD, HMZ, and AAG have substantial contributions to the conception and design of the work. AAA performed and revised the histopathological and immunohistochemical examination of tumor tissues. AMD, HMZ, AAG, and MNA have a substantial contribution to collecting and analyzing data. AMD drafting the article. HMZ and AAG revised it. All Authors have approved the submitted manuscript.

Funding

None.

Acknowledgments

None.

Conflict of interest

The authors have no conflicts of interest to disclose.

Supplementary material

None.

References

1. Li X, Oprea-Ilies GM, Krishnamurti U. New Developments in Breast Cancer and Their Impact on Daily Practice in Pathology. Arch Pathol Lab Med. 2017; 141(4): 490–498, doi: 10.5858/arpa.2016-0288-SA, indexed in Pubmed: 28353377.
2. Bertucci F, Ng CKY, Patsouris A, et al. Genomic characterization of metastatic breast cancers. Nature. 2019; 569(7757): 560–564, doi: 10.1038/s41586-019-1056-z, indexed in Pubmed: 31118521.
3. den Brok WD, Speers CH, Gondara L, et al. Survival with metastatic breast cancer based on initial presentation, de novo versus relapsed. Breast Cancer Res Treat. 2017; 161(3): 549–556, doi: 10.1007/s10549-016-4080-9, indexed in Pubmed: 28000014.
4. Bonotto M, Gerratana L, Poletto E, et al. Measures of outcome in metastatic breast cancer: insights from a real-world scenario. Oncologist. 2014; 19(6): 608–615, doi: 10.1634/theoncologist.2014-0002, indexed in Pubmed: 24794159.
5. Lin NU, Claus E, Sohl J, et al. Sites of distant recurrence and clinical outcomes in patients with metastatic triple-negative breast cancer: high incidence of central nervous system metastases. Cancer. 2008; 113(10): 2638–2645, doi: 10.1002/cncr.23930, indexed in Pubmed: 18833576.
6. Schmid P, Rugo HS, Adams S, et al. IMpassion130 Investigators. Atezolizumab plus nab-paclitaxel as first-line treatment for unresectable, locally advanced or metastatic triple-negative breast cancer (IMpassion130): updated efficacy results from a randomised, double-blind, placebo-controlled, phase 3 trial. Lancet Oncol. 2020; 21(1): 44–59, doi: 10.1016/S1470-2045(19)30689-8, indexed in Pubmed: 31786121.
7. Miles D, Gligorov J, André F, et al. IMpassion131 investigators. Primary results from IMpassion131, a double-blind, placebo-controlled, randomised phase III trial of first-line paclitaxel with or without atezolizumab for unresectable locally advanced/metastatic triple-negative breast cancer. Ann Oncol. 2021; 32(8): 994–1004, doi: 10.1016/j.annonc.2021.05.801, indexed in Pubmed: 34219000.
8. Cortes J, Cescon DW, Rugo HS, et al. KEYNOTE-355 Investigators. Pembrolizumab plus chemotherapy versus placebo plus chemotherapy for previously untreated locally recurrent inoperable or metastatic triple-negative breast cancer (KEYNOTE-355): a randomised, placebo-controlled, double-blind, phase 3 clinical trial. Lancet. 2020; 396(10265): 1817–1828, doi: 10.1016/S0140-6736(20)32531-9, indexed in Pubmed: 33278935.
9. Cortés J, Cescon DW, Rugo HS, et al. LBA16 KEYNOTE-355: Final results from a randomized, double-blind phase III study of first-line pembrolizumab + chemotherapy vs placebo + chemotherapy for metastatic TNBC. Ann Oncol. 2021; 32: S1289–S1290, doi: 10.1016/j.annonc.2021.08.2089.
10. Robson M, Im SA, Senkus E, et al. Olaparib for Metastatic Breast Cancer in Patients with a Germline BRCA Mutation. N Engl J Med. 2017; 377(6): 523–533, doi: 10.1056/NEJMoa1706450, indexed in Pubmed: 28578601.
11. Litton JK, Hurvitz SA, Mina LA, et al. Talazoparib versus chemotherapy in patients with germline BRCA1/2-mutated HER2-negative advanced breast cancer: final overall survival results from the EMBRACA trial. Ann Oncol. 2020; 31(11): 1526–1535, doi: 10.1016/j.annonc.2020.08.2098, indexed in Pubmed: 32828825.
12. Marra A, Trapani D, Viale G, et al. Practical classification of triple--negative breast cancer: intratumoral heterogeneity, mechanisms of drug resistance, and novel therapies. NPJ Breast Cancer. 2020; 6: 54, doi: 10.1038/s41523-020-00197-2, indexed in Pubmed: 33088912.
13. Gennari A, André F, Barrios CH, et al. ESMO Guidelines Committee. Electronic address: clinicalguidelines@esmo.org. ESMO Clinical Practice Guideline for the diagnosis, staging and treatment of patients with metastatic breast cancer. Ann Oncol. 2021; 32(12): 1475–1495, doi: 10.1016/j.annonc.2021.09.019, indexed in Pubmed: 34678411.
14. Bardia A, Hurvitz SA, Tolaney SM, et al. ASCENT Clinical Trial Investigators. Sacituzumab Govitecan in Metastatic Triple-Negative Breast Cancer. N Engl J Med. 2021; 384(16): 1529–1541, doi: 10.1056/NEJMoa2028485, indexed in Pubmed: 33882206.
15. Bardia A, Tolaney S, Loirat D, et al. Sacituzumab govitecan (SG) versus treatment of physician's choice (TPC) in patients (pts) with previously treated, metastatic triple-negative breast cancer (mTNBC): Final results from the phase 3 ASCENT study. J Clin Oncol. 2022; 40(16_suppl): 1071–1071, doi: 10.1200/jco.2022.40.16_suppl.1071.
16. Modi S, Jacot W, Yamashita T, et al. DESTINY-Breast04 Trial Investigators. Trastuzumab Deruxtecan in Previously Treated HER2-Low Advanced Breast Cancer. N Engl J Med. 2022; 387(1): 9–20, doi: 10.1056/NEJMoa2203690, indexed in Pubmed: 35665782.
17. Hurvitz SA, Bardia A, Punie K, et al. 168P Sacituzumab govitecan (SG) efficacy in patients with metastatic triple-negative breast cancer (mTNBC) by HER2 immunohistochemistry (IHC) status: Findings from the phase III ASCENT study. Ann Oncol. 2022; 33: S200–S201, doi: 10.1016/j.annonc.2022.03.187.
18. Li M, Fan Y, Li Q, et al. Vinorelbine Plus Platinum in Patients with Metastatic Triple Negative Breast Cancer and Prior Anthracycline and Taxane Treatment. Medicine (Baltimore). 2015; 94(43): e1928, doi: 10.1097/MD.0000000000001928, indexed in Pubmed: 26512619.
19. Gregory RK, Smith IE. Vinorelbine--a clinical review. Br J Cancer. 2000; 82(12): 1907–1913, doi: 10.1054/bjoc.2000.1203, indexed in Pubmed: 10864196.
20. Wang J, Zheng R, Wang Z, et al. Efficacy and Safety of Vinorelbine Plus Cisplatin vs. Gemcitabine Plus Cisplatin for Treatment of Metastatic Triple-Negative Breast Cancer After Failure with Anthracyclines and Taxanes. Med Sci Monit. 2017; 23: 4657–4664, doi: 10.12659/msm.905300, indexed in Pubmed: 28957036.
21. Zeichner SB, Terawaki H, Gogineni K. A Review of Systemic Treatment in Metastatic Triple-Negative Breast Cancer. Breast Cancer (Auckl). 2016; 10: 25–36, doi: 10.4137/BCBCR.S32783, indexed in Pubmed: 27042088.
22. Tutt A, Tovey H, Cheang MC, et al. Carboplatin in BRCA1/2-mutated and triple-negative breast cancer BRCAness subgroups: the TNT Trial. Nat Med. 2018; 24(5): 628–637, doi: 10.1038/s41591-018-0009-7, indexed in Pubmed: 29713086.
23. Diéras V, Han HS, Kaufman B, et al. Veliparib with carboplatin and paclitaxel in BRCA-mutated advanced breast cancer (BROCADE3): a randomised, double-blind, placebo-controlled, phase 3 trial. Lancet Oncol. 2020; 21(10): 1269–1282, doi: 10.1016/S1470-2045(20)30447-2, indexed in Pubmed: 32861273.
24. Ambros T, Zeichner SB, Zaravinos J, et al. A retrospective study evaluating a fixed low dose capecitabine monotherapy in women with HER-2 negative metastatic breast cancer. Breast Cancer Res Treat. 2014; 146(1): 7–14, doi: 10.1007/s10549-014-3003-x, indexed in Pubmed: 24899084.

25. Eisenhauer EA, Therasse P, Bogaerts J, et al. New response evaluation criteria in solid tumours: revised RECIST guideline (version 1.1). Eur J Cancer. 2009; 45(2): 228–247, doi: 10.1016/j.ejca.2008.10.026, indexed in Pubmed: 19097774.
26. Mohile SG, Dale W, Somerfield MR, et al. Practical Assessment and Management of Vulnerabilities in Older Patients Receiving Chemotherapy: ASCO Guideline for Geriatric Oncology. J Clin Oncol. 2018; 36(22): 2326–2347, doi: 10.1200/JCO.2018.78.8687, indexed in Pubmed: 29782209.
27. National Cancer Institute. (2010). The NCI Common Terminology Criteria for Adverse Events (CTCAE) version 4.03 (NIH Publication No. 09-5410 U.S. Revised and Reprinted June 2010) Department of Health and Human Services. National Institutes of Health.
28. Du F, Yuan P, Luo Y, et al. [Efficacy and toxicity of vinorelbine (NVB)-based regimens in patients with metastatic triple negative breast cancer (mTNBC) pretreated with anthracyclines and taxanes]. Zhonghua Zhong Liu Za Zhi. 2015; 37(10): 788–792, indexed in Pubmed: 26813602.
29. Hu XC, Zhang J, Xu BH, et al. Cisplatin plus gemcitabine versus paclitaxel plus gemcitabine as first-line therapy for metastatic triple-negative breast cancer (CBCSG006): a randomised, open-label, multicentre, phase 3 trial. Lancet Oncol. 2015; 16(4): 436–446, doi: 10.1016/S1470-2045(15)70064-1, indexed in Pubmed: 25795409.

VIA MEDICA

ORIGINAL ARTICLE

Teodoro J. Oscanoa[1–3], Edwin Cieza-Macedo[1–3], Xavier Vidal[4], Roman Romero-Ortuno[5]

[1]Facultad de Medicina Humana, Universidad de San Martín de Porres, Lima, Perú
[2]Geriatric Department, Almenara Hospital, ESSALUD, Lima, Perú
[3]Facultad de Medicina, Universidad Nacional Mayor de San Marcos, Lima, Perú
[4]Department de Farmacologia Clínica, Hospital Universitari Vall d'Hebron, Universitat Autònoma de Barcelona, Barcelona, Spain
[5]Discipline of Medical Gerontology, Mercer's Institute for Successful Ageing, St James's Hospital, Dublin, Ireland

Evaluation of the Timed Up and Go test for screening vulnerability and frailty in older cancer patients

Address for correspondence:
Teodoro J. Oscanoa, PhD
Facultad de Medicina Humana,
Universidad de San Martín de Porres,
Drug Safety Research Center,
Av. Alameda del Corregidor 1502,
La Molina 15024. Lima, Perú
e-mail:
tjoscanoae@gmail.com; toscanoae@usmp.pe

Oncology in Clinical Practice
DOI: 10.5603/ocp.96855
Copyright © 2024 Via Medica
ISSN 2450–1654
e-ISSN 2450–6478

ABSTRACT

Introduction. The need for comprehensive geriatric assessment (CGA) in older adults with cancer is increasing, which makes it necessary to have a screening instrument to identify those who would benefit from this evaluation. This study aimed to investigate diagnostic performance of the Timed Up and Go test (TUG) for identifying vulnerable or frail older adults with cancer who might benefit from CGA.

Material and methods. This observational and retrospective study took place at the geriatric center of Almenara Hospital in Lima, Peru We extracted CGA reports from electronic medical records of outpatients and inpatients aged 60 years and older with cancer, who were evaluated between November 2022 and July 2023. Patients were classified based on SIOG-2 (International Society of Geriatric Oncology) criteria as fit, vulnerable, or frail, based on scales including Activities of Daily Living (ADL), Instrumental ADL, Mini-Nutritional Assessment (MNA), Mini-Mental State Exam (MMSE), Geriatric Depression Scale, and Cumulative Illness Rating Scale-Geriatrics (CIRS-G). For the study, two groups were formed: fit patients and non-fit patients (vulnerable plus frail). We estimated sensitivity, specificity, and positive predictive values of the TUG test. The accuracy of the TUG test was analyzed using the area under the receiver operating characteristic curve (AUC).

Results. Among the 283 included patients, 154 were men (54.4%) and 129 women (45.6%), and the mean age was 76.8 ± 15.8 years. The most common neoplasms were colorectal (19.4%), stomach (15.2%), prostate (9.9%), and bile duct cancers (8.1%). The percentage of fit and non-fit patients was 21.9% and 78.1%, respectively. When the TUG test was equal to or greater than 15.5 seconds, sensitivity, specificity, positive predictive value, and AUC were 68.5% (95% CI 61.9–74.5), 88.5% (77.8–95.3), 95.6% (91.1–98.2), and 84.8% (0.80–0.90), respectively.

Conclusions. A TUG test result equal to or greater than 15.5 seconds demonstrated good screening properties for identifying older cancer patients who were vulnerable or frail and could benefit from CGA.

Keywords: timed up and go test, frailty, cancer, geriatric oncology, comprehensive geriatric assessment

Oncol Clin Pract 2024; 20, 1: 9–14

Introduction

Comprehensive geriatric assessment (CGA) is a multi-dimensional, multi-disciplinary diagnostic and therapeutic process that aims to identify medical, mental, and functional problems in frail older people. The goal is to develop a coordinated and integrated treatment plan and follow-up [1]. In older cancer patients, CGA is crucial for guiding therapeutic interventions and avoiding over- or under-treatment, especially in patients identified as vulnerable or frail [2–4].

Received: 07.08.2023 Accepted: 04.09.2023 Early publication date: 29.09.2023

This article is available in open access under Creative Common Attribution-Non-Commercial-No Derivatives 4.0 International (CC BY-NC-ND 4.0) license, allowing to download articles and share them with others as long as they credit the authors and the publisher, but without permission to change them in any way or use them commercially.

One of the challenges of conducting a CGA is the time it takes. In older cancer patients, this procedure can range from 30 to 80 minutes, depending on the components and tools used [5–7]. Although simplified 10-minute versions of the CGA have been developed [8], the greatest benefits are observed in cancer patients classified as vulnerable or frail. For fit patients, especially in areas with a shortage of geriatric specialists or high workloads, this procedure may not be necessary [9].

A two-step frailty assessment strategy in older cancer patients involves using a screening instrument to prevent unnecessary CGA in fit patients. The second step is to perform a CGA in the selected vulnerable or frail patients [10]. This strategy can also facilitate referrals to centers with greater expertise in CGA, particularly in low-income countries. A recent systematic study investigated validated instruments to identify older cancer patients who may benefit from CGA [11]. The study found that two instruments, the Vulnerable Elders Survey (VES-13) [12] and the G8 geriatric screening tool [13], had the most evidence for usefulness. However, most of these studies did not report on the time required to administer each tool [11]. Additionally, a modified G8 has recently been released [14]. Another study using the net benefit approach found that both G8 and the modified G8 failed to demonstrate clinical value in prescreening for frailty across various tumor types, disease stages, and age groups [10].

The Timed Up and Go (TUG) test is used to measure functional mobility of older adults and assess their risk of falls [15]. It has also been studied in a group of older cancer patients, showing a predictive capacity for the risk of early death in onco-geriatric patients receiving chemotherapy [16]. The TUG test can predict the risk of postoperative complications [17] and increased 5-year mortality in older adults undergoing surgery for solid tumors [18]. However, the TUG has not been studied in relation to its ability to identify older adults with cancer who are vulnerable or frail. Therefore, this study aimed to investigate the diagnostic performance of the TUG in identifying vulnerable or frail older adults with cancer who might benefit from CGA.

Material and methods

Setting

An observational and retrospective study was conducted study was conducted at the Geriatric Department of the ESSALUD Almenara Hospital, a tertiary care hospital in Lima, Peru. We reviewed CGA reports stored in the electronic medical records of hospitalized or outpatient adult patients aged ≥ 60 years with a previous cancer diagnosis, who had been evaluated between November 2022 and July 2023. The study followed the Standards for Reporting Diagnostic Accuracy Studies (STARD) recommendations [19].

Comprehensive geriatric assessment

Comprehensive geriatric assessment was performed by two trained geriatricians, who assessed the following domains: function and mobility, nutritional status, cognition, mood, social environment, and comorbidities. Six CGA indicators were selected: functional impairment (Activities of Daily Living score, ADL ≤ 5/6) [20]; cognitive impairment: Mini-Mental State Examination (MMSE, Spanish version) score < 24/30 [21]; malnutrition defined as one or more of the following French National Authority for Health criteria: at least 10% weight loss in 6 months or 5% in 1 month, and/or body mass index less than 21 kg/m^2, and/or Mini-Nutritional Assessment (MNA-SF) score less than 12/14, and/or serum albumin level less than 35 g/L [22]; inadequate social environment defined as a score ≥ 10 on the Gijon social family assessment scale (Spanish version) [23]; verification of the diagnosis of depression in the medical history and use of antidepressants or depression diagnosed by a semi-structured interview to identify criteria for a major depressive episode from the Diagnostic and Statistical Manual of Mental Disorders (DSM-IV) [24]; and the number of severe (grade 3–4) comorbidities as assessed by the Cumulative Illness Rating Scale for Geriatrics (CIRS-G 0, 1, ≥ 2) [25]. Data was also collected on tumor site, metastatic status, age, sex, and in/outpatient status at the time of the CGA.

Timed Up and Go

The TUG test assesses the time a patient needs to get up from a chair, walk 3 meters, turn around, walk back, and sit down again [15]. This is measured in seconds with a handheld stopwatch. Two measurements were taken, and the average of these measurements was used in the study. The cut-off points for impaired TUG scores in older patients varied between 10 to 20 seconds [26]. The TUG test is an integral component of the CGA procedure in our center. Consequently, the results are routinely documented. However, it is important to note that the TUG test was not performed in patients who were unable to walk due to various reasons, such as being bedridden, dizziness, or knee pain, among others.

Vulnerability and frailty criteria

We used the frailty criteria of the International Society of Geriatric Oncology (SIOG-2) [27]. A patient is considered frail when they meet one of the following criteria: the presence of CIRS-G ≥ 1 grade 4 comorbidity, or ≥ 2 grade 3 comorbidities, or IADL score ≥ 7 of 8, or MMSE score < 24 of 30, or malnutrition (MNA-SF ≤ 7),

or ADL score ≤ 3 of 6. A patient is called vulnerable when they meet the following criteria: number of severe (grade 4) comorbidities = 0 (assessed by the CIRS-G), and IADL score > 7 of 8, and MMSE ≥ 24 of 30, and 1 grade 3 comorbidity, or ≥ 1 grade 2 comorbidity, or at risk for malnutrition (MNA-SF < 12), or ADL score 4 or 5 of 6, or depression. Finally, a patient is considered fit when they score > 14 of 17 on the G8 scale. For this study, patients were assigned into two groups: fit *vs.* non-fit (vulnerable plus frail).

Statistical analysis

In the descriptive analysis, measures of central tendency, dispersion, and absolute and relative frequencies were used. Categorical variables were described as counts and percentages, and quantitative variables as means [standard deviation (SD)] or medians (range) depending on distribution. The performance of the TUG test was evaluated using sensitivity, specificity, receiver operating curve (ROC), and area under the ROC curve (AUC). Confidence intervals (95% CI) were reported. For sensitivity and specificity analysis, patients who did not undergo the test due to being bedridden or wheelchair-bound were timed with the maximum TUG time detected in the study.

Ethical approval

This study was approved by the Research Ethics Committee of Almenara Hospital in Lima, Peru (approval number 80-CIEI-OIyD-GRPA-ESSALUD-2023, March 27, 2023). Necessary strategies were implemented to maintain confidentiality of patient information.

Results

A total of 283 patients were included in the study, with 54.4% of them being hospitalized at the time of the CGA. The mean age was 76.8 ± 15.8 years, and the sample comprised 154 men (54.4%) and 129 women (45.6%). The prevalence of malnutrition, depression, and cognitive disorders was 71.7%, 27.2%, and 39.8%, respectively. Furthermore, 51.6% of the patients had severe comorbidities (grade 3–4 CIRS-G), and 46.0% had functional impairment (Katz < 5/6). The ten most frequent types of tumors were colorectal (19.4%), stomach (15.2%), prostate (9.9%), bile ducts (8.1%), hematologic malignancy (lymphoma, leukemia) (8.1%), breast (4.6%), lung (4.6%), liver (4.2%), skin (4.2%), and pancreas (3.9%). The frequency of patients with metastases and those with two tumors of different origin were 26.9% and 6.4%, respectively (Tab. 1). According to the SIOG-2 classification, the prevalence of fit, vulnerable, and frail patients was 21.9%, 50.9%, and 21.2%, respectively.

Regarding the performance of the screening tool, the prevalence of fit and non-fit patients was 21.9% and 78.1%, respectively. When the TUG test results were equal to or greater than 15.5 seconds, sensitivity, specificity, positive predictive value, and AUC were 68.5% (95% CI 61.9–74.5), 88.5% (77.8–95.3), 95.6% (91.1–98.2), and 84.8% (0.80–0.90), respectively (Fig. 1). When the TUG analysis was conducted with 217 patients (excluding 66 of 283 who were unable to walk during the examination), the optimal cut-off point remained at 15.5 seconds. Sensitivity, specificity, positive predictive value, and area under the curve (AUC) were as follows: 55.1% (47.0–63.1), 88.5% (77.8–95.3), 92.5% (84.8–94.5), and 0.72 (0.66–0.77), respectively.

Discussion

Our study demonstrated that the TUG test, with an optimum cut-off value of 15.5 seconds, could serve as a valuable screening tool to identify vulnerable or frail older adults with cancer who could benefit from a CGA.

To our knowledge, this study is the first to use the TUG test as a screening tool before CGA in cancer patients, but it can be compared with other studies that used similar strategies. For example, gait speed (GS) measures the time needed for older patients to walk a certain distance at their usual speed [28]. Pamoukdjian et al. [29] assessed the diagnostic performance of GS for assessing vulnerability in older cancer patients and found that a GS < 1 m/s had sensitivity of 79.4%, specificity of 64.7%, and AUC of 82.0% (74.0–90.0%) [29]. However, GS faces challenges in clinical practice due to the lack of a standardized protocol and variations in measurement methods (e.g. distance walked, starting and deceleration procedures, timing, and type of testing surface) [30]. In contrast, the TUG test is a more internationally standardized option.

The G8 index and its modified version have also been used as screening instruments in older cancer patients. The G8 index showed sensitivity ranging from 76.5% to 87.2% and specificity from 17% to 65% in different studies [13, 14, 31], while the modified version had sensitivity from 89.2% to 89.3% and specificity from 64.7% to 79.0% [14, 29]. Additionally, the VES-13, used for the same purpose, showed sensitivity ranging from 39.0% to 67.8% and specificity from 64.4% to 84.4% [31, 32]. The mean time to complete the G8 or VES-13 is approximately five minutes [31].

Previous evidence supports the usefulness of the TUG test in older cancer patients, as it has been correlated with survival, treatment-related complications, cognitive function, global health decline, disability in activities of daily living, and sarcopenia in various studies [26, 33–35].

Table 1. Patient characteristics

Variable	Total patients (n = 283)		Fit (n = 61) (21.6%)		Non-fit (vulnerable+ frail*) n = 222 (78.5%)	
	n	%	n	%	n	%
Sex						
Male	154	54.4%	40	65.6%	114	51.4%
Female	129	45.6%	21	34.4%	108	48.7%
Indicators						
Inadequate social environment	13	4.6%	2	3.3%	11	5.0%
Malnutrition	203	71.7%	6	9.8%	197	88.7%
Depression (DSM IV criteria)	77	27.2%	1	1.6%	76	34.2%
Cognitive impairment (MMSE < 24/30)	112	39.6%	0		112	50.5%
No. of severe comorbidities (grade 3–4 CIRS-G)						
0	137	48.4%	61	100.0%	76	34.2%
1	120	42.4%	0		120	54.1%
≥ 2	26	9.2%	0		26	11.7%
Functional impairment (Katz; ADL score < 5 of 6)	130	45.9%	0		130	58.6%
Outpatient at time of CGA	129	45.6%	28	45.9%	101	45.5%
Tumor site						
Colorectal	55	19.4%	8	13.1%	47	21.2%
Stomach	43	15.2%	5	8.2%	38	17.1%
Prostate	28	9.9%	8	13.1%	20	9.0%
Bile ducts	23	8.1%	7	11.5%	16	7.2%
Hematologic malignancy (lymphoma, leukemia)	23	8.1%	5	8.2%	18	8.1%
Breast	13	4.6%	5	8.2%	8	3.6%
Lung	13	4.6%	3	4.9%	10	4.5%
Liver	12	4.2%	5	8.2%	7	3.2%
Skin	12	4.2%	4	6.6%	8	3.6%
Pancreas	11	3.9%	3	4.9%	8	3.6%
Kidney	10	3.5%	2	3.3%	8	3.6%
Head and neck	7	2.5%	2	3.3%	5	2.3%
Brain	6	2.1%	0		6	2.7%
Endometrium	3	1.1%	0		3	1.4%
Bladder	3	1.1%	0		3	1.4%
Ovary	2	0.7%	1	1.6%	1	0.5%
Other/unknown primary sites	19	6.70%	3	4.9%	16	7.2%
Two tumor sites	18	6.36%	3	4.9%	15	6.8%
Metastatic status	76	26.86%	10	16.4%	66	29.7%

*Classification of the International Society of Geriatric Oncology (SIOG-2); CGA — comprehensive geriatric assessment; CIRS-G — Cumulative Illness Rating Scale-Geriatrics; DSM-IV — Diagnostic and Statistical Manual of Mental Disorders; MMSE — Mini-Mental State Exam

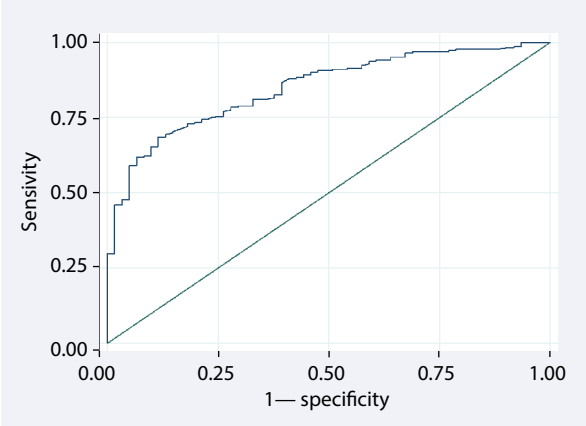

Figure 1. Evaluation of the Timed Up and Go test to screen for vulnerability and frailty in older cancer patients: Receiver operating characteristic (ROC) curve; receiver operating characteristic curve (AUC) = 84.8% (0.800–0.897)

However, our study has some limitations. The criteria used to select fit and non-fit patients (vulnerable plus frail) and evaluate TUG's performance were based on SIOG-2 criteria [27, 36], whereas studies evaluating G8 and VES-13 used different cut-off points for each CGA scale [13]. Additionally, our study was conducted in a group of patients with a high prevalence of frailty, and further research is needed in patients with a lower prevalence of frailty. This is because diagnostic test studies in high-prevalence disease groups may lead to variations in predictive values, increasing the positive predictive value. In addition, the cut-off of > 15.5 is internally valid to our sample and not necessarily externally generalizable, further research is needed in different settings before an international TUG cut-off value can be recommended.

Conclusions

In conclusion, the TUG test with a cut-off of > 15.5 seconds showed promising sensitivity, specificity, positive predictive value, and AUC in identifying older adult cancer patients who may require CGA. This test could be beneficial, especially in hospitals with high demand for geriatric evaluation or a limited number of specialists.

Article Information and Declarations

Data availability statement

The data that support the findings of this study are available on request from the corresponding author. The data are not publicly available due to privacy or ethical restriction.

Ethics statement

This study was approved by the Research Ethics Committee of Almenara Hospital in Lima, Peru (letter 80-CIEI-OIyD-GRPA-ESSALUD-2023, March 27, 2023). The necessary strategies were implemented to maintain the privacy of patient information.

Author contributions

T.J.O.: concept and design, drafting of the manuscript, critical revision of the manuscript for important intellectual content; E.C-M.: acquisition, analysis, interpretation of the data, critical revision of the manuscript for important intellectual content; X.V.: acquisition, analysis, interpretation of the data, critical revision of the manuscript for important intellectual content; R.R.-O.: drafting of the manuscript, critical revision of the manuscript for important intellectual content, supervision.

Funding

None.

Acknowledgments

None.

Conflict of interest

The authors have no conflicts of interest to disclose.

References

1. Ellis G, Gardner M, Tsiachristas A, et al. Comprehensive geriatric assessment for older adults admitted to hospital. Cochrane Database Syst Rev. 2017; 9(9): CD006211, doi: 10.1002/14651858.CD006211.pub3, indexed in Pubmed: 28898390.
2. Mohile SG, Dale W, Somerfield MR, et al. Practical Assessment and Management of Vulnerabilities in Older Patients Receiving Chemotherapy: ASCO Guideline for Geriatric Oncology Summary. J Oncol Pract. 2018; 14(7): 442–446, doi: 10.1200/JOP.18.00180, indexed in Pubmed: 29932846.
3. Rostoft S, O'Donovan A, Soubeyran P, et al. Geriatric Assessment and Management in Cancer. J Clin Oncol. 2021; 39(19): 2058–2067, doi: 10.1200/JCO.21.00089, indexed in Pubmed: 34043439.
4. Dale W, Klepin HD, Williams GR, et al. Practical Assessment and Management of Vulnerabilities in Older Patients Receiving Systemic Cancer Therapy: ASCO Guideline Update. J Clin Oncol. 2023 [Epub ahead of print]: JCO2300933, doi: 10.1200/JCO.23.00933, indexed in Pubmed: 37459573.
5. Horgan AM, Leighl NB, Coate L, et al. Impact and feasibility of a comprehensive geriatric assessment in the oncology setting: a pilot study. Am J Clin Oncol. 2012; 35(4): 322–328, doi: 10.1097/COC.0b013e318210f9ce, indexed in Pubmed: 21422992.
6. Horgan AM, Knox JJ, Alibhai SMH. The comprehensive geriatric assessment in oncology: promises, pitfalls, and practicalities. Hosp Pract (1995). 2010; 38(3): 128–136, doi: 10.3810/hp.2010.06.306, indexed in Pubmed: 20890062.
7. Corre R, Greillier L, Le Caër H, et al. Use of a Comprehensive Geriatric Assessment for the Management of Elderly Patients With Advanced Non-Small-Cell Lung Cancer: The Phase III Randomized ESOGIA-GFPC-GECP 08-02 Study. J Clin Oncol. 2016; 34(13): 1476–1483, doi: 10.1200/JCO.2015.63.5839, indexed in Pubmed: 26884557.
8. Akhtar OS, Huang LW, Tsang M, et al. Geriatric assessment in older adults with non-Hodgkin lymphoma: A Young International Society

of Geriatric Oncology (YSIOG) review paper. J Geriatr Oncol. 2022; 13(5): 572–581, doi: 10.1016/j.jgo.2022.02.005, indexed in Pubmed: 35216939.
9. Stuck AE, Siu AL, Wieland GD, et al. Comprehensive geriatric assessment: a meta-analysis of controlled trials. Lancet. 1993; 342(8878): 1032–1036, doi: 10.1016/0140-6736(93)92884-v, indexed in Pubmed: 8105269.
10. González Serrano A, Laurent M, Barnay T, et al. A Two-Step Frailty Assessment Strategy in Older Patients With Solid Tumors: A Decision Curve Analysis. J Clin Oncol. 2023; 41(4): 826–834, doi: 10.1200/JCO.22.01118, indexed in Pubmed: 36306481.
11. Garcia MV, Agar MR, Soo WK, et al. Screening Tools for Identifying Older Adults With Cancer Who May Benefit From a Geriatric Assessment: A Systematic Review. JAMA Oncol. 2021; 7(4): 616–627, doi: 10.1001/jamaoncol.2020.6736, indexed in Pubmed: 33443547.
12. Saliba D, Elliott M, Rubenstein LZ, et al. The Vulnerable Elders Survey: a tool for identifying vulnerable older people in the community. J Am Geriatr Soc. 2001; 49(12): 1691–1699, doi: 10.1046/j.1532-5415.2001.49281.x, indexed in Pubmed: 11844005.
13. Bellera CA, Rainfray M, Mathoulin-Pélissier S, et al. Screening older cancer patients: first evaluation of the G-8 geriatric screening tool. Ann Oncol. 2012; 23(8): 2166–2172, doi: 10.1093/annonc/mdr587, indexed in Pubmed: 22250183.
14. Martinez-Tapia C, Canoui-Poitrine F, Bastuji-Garin S, et al. ELCAPA Study Group. Optimizing the G8 Screening Tool for Older Patients With Cancer: Diagnostic Performance and Validation of a Six-Item Version. Oncologist. 2016; 21(2): 188–195, doi: 10.1634/theoncologist.2015-0326, indexed in Pubmed: 26764250.
15. Podsiadlo D, Richardson S. The timed "Up & Go": a test of basic functional mobility for frail elderly persons. J Am Geriatr Soc. 1991; 39(2): 142–148, doi: 10.1111/j.1532-5415.1991.tb01616.x, indexed in Pubmed: 1991946.
16. Soubeyran P, Fonck M, Blanc-Bisson C, et al. Predictors of early death risk in older patients treated with first-line chemotherapy for cancer. J Clin Oncol. 2012; 30(15): 1829–1834, doi: 10.1200/JCO.2011.35.7442, indexed in Pubmed: 22508806.
17. Huisman MG, van Leeuwen BL, Ugolini G, et al. "Timed Up & Go": a screening tool for predicting 30-day morbidity in onco-geriatric surgical patients? A multicenter cohort study. PLoS One. 2014; 9(1): e86863, doi: 10.1371/journal.pone.0086863, indexed in Pubmed: 24475186.
18. Hendriks S, Huisman MG, Ghignone F, et al. Timed up and go test and long-term survival in older adults after oncologic surgery. BMC Geriatr. 2022; 22(1): 934, doi: 10.1186/s12877-022-03585-4, indexed in Pubmed: 36464696.
19. Bossuyt PM, Reitsma JB, Bruns DE, et al. STARD Group. STARD 2015: an updated list of essential items for reporting diagnostic accuracy studies. BMJ. 2015; 351: h5527, doi: 10.1136/bmj.h5527, indexed in Pubmed: 26511519.
20. Katz S. Studies of Illness in the Aged. JAMA. 1963; 185(12): 914, doi: 10.1001/jama.1963.03060120024016.
21. Lobo A, Saz P, Marcos G, et al. [Revalidation and standardization of the cognition mini-exam (first Spanish version of the Mini-Mental Status Examination) in the general geriatric population]. Med Clin (Barc). 1999; 112(20): 767–774, indexed in Pubmed: 10422057.
22. Raynaud-Simon A, Revel-Delhom C, Hébuterne X, et al. French Nutrition and Health Program, French Health High Authority. Clinical practice guidelines from the French Health High Authority: nutritional support strategy in protein-energy malnutrition in the elderly. Clin Nutr. 2011; 30(3): 312–319, doi: 10.1016/j.clnu.2010.12.003, indexed in Pubmed: 21251732.
23. García González JV, Díaz Palacios E, Salamea García A, et al. [An evaluation of the feasibility and validity of a scale of social assessment of the elderly]. Aten Primaria. 1999; 23(7): 434–440, indexed in Pubmed: 10363397.
24. Bell C. DSM-IV: Diagnostic and Statistical Manual of Mental Disorders. JAMA J Am Med Assoc. 1994; 272(10): 828, doi: 10.1001/jama.1994.03520100096046.
25. Miller MD, Paradis CF, Houck PR, et al. Rating chronic medical illness burden in geropsychiatric practice and research: application of the Cumulative Illness Rating Scale. Psychiatry Res. 1992; 41(3): 237–248, doi: 10.1016/0165-1781(92)90005-n, indexed in Pubmed: 1594710.
26. Verweij NM, Schiphorst AHW, Pronk A, et al. Physical performance measures for predicting outcome in cancer patients: a systematic review. Acta Oncol. 2016; 55(12): 1386–1391, doi: 10.1080/0284186X.2016.1219047, indexed in Pubmed: 27718777.
27. Droz JP, Aapro M, Balducci L, et al. Management of prostate cancer in older patients: updated recommendations of a working group of the International Society of Geriatric Oncology. Lancet Oncol. 2014; 15(9): e404–e414, doi: 10.1016/S1470-2045(14)70018-X, indexed in Pubmed: 25079103.
28. Binotto M, Lenardt M, Rodríguez-Martínez M. Fragilidade física e velocidade da marcha em idosos da comunidade: uma revisão sistemática. Revista da Escola de Enfermagem da USP. 2018; 52(0), doi: 10.1590/s1980-220x2017028703392.
29. Pamoukdjian F, Canoui-Poitrine F, Longelin-Lombard C, et al. Diagnostic performance of gait speed, G8 and G8 modified indices to screen for vulnerability in older cancer patients: the prospective PF-EC cohort study. Oncotarget. 2017; 8(31): 50393–50402, doi: 10.18632/oncotarget.17361, indexed in Pubmed: 28881570.
30. Stuck AK, Bachmann M, Füllemann P, et al. Effect of testing procedures on gait speed measurement: A systematic review. PLoS One. 2020; 15(6): e0234200, doi: 10.1371/journal.pone.0234200, indexed in Pubmed: 32479543.
31. Soubeyran P, Bellera C, Goyard J, et al. Screening for vulnerability in older cancer patients: the ONCODAGE Prospective Multicenter Cohort Study. PLoS One. 2014; 9(12): e115060, doi: 10.1371/journal.pone.0115060, indexed in Pubmed: 25503576.
32. Shah M, Noronha V, Ramaswamy A, et al. G8 and VES-13 as screening tools for geriatric assessment and predictors of survival in older Indian patients with cancer. J Geriatr Oncol. 2022; 13(5): 720–730, doi: 10.1016/j.jgo.2022.02.013, indexed in Pubmed: 35283049.
33. Donoghue OA, Horgan NF, Savva GM, et al. Association between timed up-and-go and memory, executive function, and processing speed. J Am Geriatr Soc. 2012; 60(9): 1681–1686, doi: 10.1111/j.1532-5415.2012.04120.x, indexed in Pubmed: 22985141.
34. Viccaro LJ, Perera S, Studenski SA. Is timed up and go better than gait speed in predicting health, function, and falls in older adults? J Am Geriatr Soc. 2011; 59(5): 887–892, doi: 10.1111/j.1532-5415.2011.03336.x, indexed in Pubmed: 21410448.
35. Martinez BP, Gomes IB, Oliveira CS, et al. Accuracy of the Timed Up and Go test for predicting sarcopenia in elderly hospitalized patients. Clinics (Sao Paulo). 2015; 70(5): 369–372, doi: 10.6061/clinics/2015(05)11, indexed in Pubmed: 26039955.
36. Ferrat E, Paillaud E, Caillet P, et al. Performance of Four Frailty Classifications in Older Patients With Cancer: Prospective Elderly Cancer Patients Cohort Study. J Clin Oncol. 2017; 35(7): 766–777, doi: 10.1200/JCO.2016.69.3143, indexed in Pubmed: 28095145.

Monika Durzyńska, Irmina M. Michałek

Department of Pathology, Maria Sklodowska-Curie National Research Institute of Oncology, Warsaw, Poland

Pan-TRK immunohistochemistry as a tool in the screening for *NTRK* gene fusions in cancer patients

Address for correspondence:
Monika Durzyńska MD PhD
Department of Pathology,
Maria Sklodowska-Curie National Research Institute of Oncology
ul. Roentgena 5, 02–781 Warsaw, Poland
e-mail: monika.durzynska@nio-pib.pl

Oncology in Clinical Practice
DOI: 10.5603/OCP.2023.0024
Copyright © 2024 Via Medica
ISSN 2450–1654
e-ISSN 2450–6478

ABSTRACT

Therapy with TRK inhibitors is a tumor-agnostic treatment directed against specific molecular changes rather than cancer type. *NTRK* fusions are rare in most prevalent cancers, accounting for less than 0.5% of cases. However, there is a group of rare cancers in which *NTRK* fusion is more prevalent. These include secretory carcinoma of the breast and salivary gland, childhood sarcomas, such as infantile fibrosarcoma, and cellular and mixed congenital mesoblastic nephroblastoma. The most common rearrangement pertains to *NTRK3* and the most common fusion gene is *ETV6*. Identifying patients with *NTRK* gene fusions who would likely benefit from targeted therapy with TRK inhibitors requires practical diagnostic tools and an appropriate management strategy of diagnostic trajectory. The fusions can be detected by molecular biology techniques or pan-TRK immunohistochemistry. The latter detects *NTRK1/2/3* gene fusions independently of the resulting fusion gene but does not determine which of them has been rearranged or what the fusion partner is. The sensitivity and specificity of the method reach 97% and 100%, respectively. Other advantages include the relatively low cost, short duration of examination, and broad accessibility of immunohistochemistry laboratories. These characteristics make this method a useful screening tool for detecting patients with *NTRK* gene fusions.

Keywords: *NTRK* genes, TRK inhibitors, diagnostic methods; immunohistochemistry

Oncol Clin Pract 2024; 20, 1: 15–21

Cancers with *NTRK* gene fusions as a therapeutic target for TRK inhibitors

In recent years, apart from the methods used so far in the treatment of oncological patients, such as surgical treatment or radio- and chemotherapy, an increasing role is played by targeted therapy, including "tumor-agnostic" therapy, directed at specific molecular changes and not cancer type [1, 2]. Tropomyosin receptor kinase (TRK) inhibitors are examples of such therapies [3, 4].

Neurotrophic TRKs are transmembrane tyrosine kinases that are essential for regulating nerve cell growth, proliferation, and differentiation. These include three groups of proteins: TRKA, TRKB, and TRKC, encoded by *NTRK1*, *NTRK2*, and *NTRK3*, respectively [5]. The *NTRK* genes can be rearranged during carcinogenesis. The *NTRK* fusion combines sequences coding for TRK proteins with sequences of other genes, leading to new active protein production [6]. In tumors with *NTRK* gene fusion, constitutive (ligand-independent) activation of intracellular biological pathways leads to a signaling cascade that controls cell cycle progression, proliferation, apoptosis, and/or survival of cancer cells [7, 8].

Tropomyosin receptor kinase inhibitors can be used in patients with confirmed *NTRK* gene rearrangement, regardless of cancer type [3, 5]. Clinical trials with a TRK inhibitor, entrectinib, have shown effectiveness

Received: 19.04.2023 Accepted: 24.04.2023 Early publication date: 29.05.2023

This article is available in open access under Creative Common Attribution-Non-Commercial-No Derivatives 4.0 International (CC BY-NC-ND 4.0) license, allowing to download articles and share them with others as long as they credit the authors and the publisher, but without permission to change them in any way or use them commercially.

Table 1. Methods for detecting *NTRK* gene fusions in tumors

	Sensitivity	Specificity	Detection of all fusions	Detection of fusion partners	Detection of protein expression
IHC	Relatively high*	Relatively high*	Yes	No	Yes
FISH	High	High	One per probe	One per probe	No
RNA NGS	High	High	Yes	Yes	Yes
DNA NGS	Moderate	High	Yes	Yes	No

*Depending on tumor morphology; FISH — fluorescence *in situ* hybridization; IHC — immunohistochemistry; NGS — next-generation sequencing

in treating diverse types of cancer, both locally advanced and generalized [9].

Cancers with *NTRK* gene fusions are rare, regardless of age group, and account for up to 0.3% of all malignancies [10]. *NTRK* gene fusions have been described in over 40 types of solid tumors [11], including pulmonary, colorectal, breast, and thyroid cancers; melanoma; glioblastoma; and several sarcomas [7, 12]. In addition, some rare tumors have a remarkably high incidence of *NTRK* fusions (> 90%). In adults, these tumors include secretory breast and salivary gland cancer, whereas, in children, they include infantile fibrosarcoma, secretory cancer of the salivary gland, and cellular and mixed congenital mesoblastic nephroblastoma [13, 14].

NTRK fusion detection methods

The infrequent occurrence of tumors with *NTRK* gene fusion requires practical diagnostic tools and appropriate diagnostic strategies [6, 7]. These fusions can be detected by immunohistochemistry (IHC), fluorescence *in situ* hybridization (FISH), reverse transcriptase polymerase chain reaction (RT-PCR), and next-generation sequencing (NGS) [7, 14]. These methods have different sensitivities, specificities, strengths, and limitations (Tab. 1).

Using pan-TRK IHC, *NTRK1/2/3* gene fusions are detected independently of the resulting fusion genes. However, it is not possible to determine the fusion partner or the rearranged *NTRK* gene. The sensitivity of the method varies between 75% and 97%, and specificity ranges from 92% to 100%. The advantages of the pan-TRK IHC technique include the relatively low cost of the test, short execution time, and availability of IHC laboratories. Due to the above qualities, this technique can be used to screen patients for *NTRK* fusion [6, 15].

Fluorescence *in situ* hybridization is a widely used diagnostic method that allows for the detection of chromosomal rearrangements. Fusion probes detect a specific type of fusion gene, such as *ETV6-NTRK3*, or break-apart probes that detect breaks such as those in *NTRK3*. However, FISH cannot determine whether the resulting fusion gene encodes a productive in-frame chimeric transcript or not. The recommendations for detecting the *ETV6-NTRK3* fusion gene are the same as the general principles of the FISH method for detecting fusion genes. They include counting the fluorescent signals in at least 50 randomly selected, non-overlapping tumor cell nuclei by at least two experienced specialists. The usefulness of FISH in cancer screening for *NTRK* fusions is limited because of the variety of fusion partners and the ability to evaluate only one gene rearrangement at a time. This method may help detect the *ETV6-NTRK3* fusion gene in tumors where this gene is present in most cases, such as secretory breast and salivary gland cancers [6, 7].

RNA NGS allows the detection of fusion genes that are transcribed. The main limitation of this method is the instability of the RNA material, especially in archival paraffin blocks. Evaluating the quality of RNA is critical for distinguishing possible false-negative results. According to the literature, only approximately 55% of archival samples meet the quality control requirements before sequencing, and the probability of quality control failure increases with the age of the analyzed material [7, 16].

Targeted DNA NGS tests consisting of panels of selected genes are increasingly being used, including those detecting *NTRK1*, *NTRK2*, and *NTRK3* fusions. Although the DNA NGS method successfully detects gene rearrangements, not all *NTRK* fusions can be detected using targeted assays. *NTRK2* and *NTRK3* are particularly problematic, as they have large intronic regions [6]. Moreover, many *NTRK* fusions detected by DNA-based sequencing are of unknown functional significance and require confirmation by other assays such as RNA sequencing or IHC [6, 7].

Performance and interpretation of the pan-TRK IHC test

The IHC test aims to detect tumors with *NTRK* fusions, which will be subjected to further molecular analysis, usually using the DNA NGS technique. Therefore, special attention should be paid to pre-analytical factors

and the assay process to minimize false-negative rates [17]. Proper conduct of the respective phases of the study affects the credibility of the results.

The first step is to select the optimal material for testing. IHC should be performed using histopathological samples that were fixed in 10% buffered formalin. The fixation time depends on the size of the tested sample and is 6–48 hours for small materials and 24–72 hours for larger materials.

Among the available antibodies, the most frequently used and best-characterized clone is EPR17341 [7, 15]. This antibody detects the C-terminal region of TRK proteins A, B, and C, which are conserved in both the wild-type and fusion proteins. Although the expression of the wild-type TRK protein in most solid tumors is minimal and rare, the pan-TRK IHC assay does not distinguish between wild-type and fusion proteins. IHC determination should be performed following the staining protocol provided by the manufacturer [18]. In addition, negative and positive control stains should be performed each time to minimize the incidence of false positive and false negative results. A negative control is performed using rabbit monoclonal antibodies. A positive control is performed using a normal human appendix. The nerves and ganglion cells in the wall show a positive reaction in the pan-TRK IHC test, whereas other structures are not stained. Performing an external positive control allows for verification of the correctness of the IHC staining process, but it does not constitute control of the pre-analytical stage. Therefore, during the assessment of pan-TRK IHC preparations, attention should be paid to whether any neural structures would constitute an internal positive control [6, 14].

The pan-TRK IHC color reaction is highly variable and can be nuclear, perinuclear/nuclear membrane, cytoplasmic, cellular membrane, or a combination of these. In addition, the staining intensity varies from weak to strong. Any of the above types of staining, stronger than that in the background and present in at least 1% of tumor cells, is interpreted as a positive reaction [14, 15, 19]. The percentage of stained cells and the intensity of staining is higher at the periphery of the specimen and lower in the central part. This type of staining is related to pre-analytical factors such as material fixation. Therefore, pan-TRK IHC tests are best performed with a small amount of material, such as a core needle biopsy, rather than with postoperative material [14]. The most common type of staining observed is the cytoplasmic reaction, which is the most common source of false-positive results compared to other types of expression. Moreover, false-positive pan-TRK IHC results are more common in tumors with muscular and nervous differentiation (leiomyosarcoma, glioma, and neuroblastoma) [7, 14]. In addition, there is a link between the type of color reaction and the occurrence of a specific fusion gene. Positive nuclear staining is often associated with *ETV6-NTRK3* and *EML4-NTRK3* fusions, nuclear membrane staining with *LMNA-NTRK1* fusions, and cell membrane staining with *TPM3-NTRK1* and *TRAF--NTRK2* fusions [15].

As mentioned above, the sensitivity of the pan-TRK IHC test has been reported to be between 75% and 97%. Discrepancies in the obtained results may result from different study populations (cancer types and fusion genes present in them) and pre-analytical procedures. The false-negative rate was higher for *NTRK3* gene fusions (21–27%) than for *NTRK1* and *NTRK2* fusions (< 10%) [13].

NTRK gene fusion tumors in the context of pan-TRK IHC results

Common neoplasms with the rare occurrence of *NTRK* gene fusions

This group of cancers includes colorectal, pulmonary, and breast cancers, where *NTRK* gene fusions occur in fewer than 1% of cases [14]. Within the gastrointestinal tract, *NTRK* fusions have also been detected in cancers of the pancreas, biliary tract, liver, appendix, and gallbladder (20). The most commonly described fusion genes include *TPM3-NTRK1*, *LMNA-NTRK1*, *TPR-NTRK1*, and *ETV6-NTRK3* [15, 20]. In wild-type *BRAF*/*RAS* and high-grade microsatellite instability (MSI), an increase in *NTRK* fusions to approximately 5% has been observed [14]. In pan-TRK IHC, these tumors are usually characterized by strong cytoplasmic staining, which may be accompanied by perinuclear staining (*LMNA* fusion partner) or membrane staining (*TPM3* fusion partner) [15].

In non-small cell lung cancer (NSCLC), mainly glandular NSCLC, *NTRK* gene rearrangements have been detected (most commonly *NTRK1*). The prevalence of such detected fusions is less than 1% [8]. In pan-TRK IHC, strong nuclear and cytoplasmic staining is usually observed [14].

In adult thyroid cancers, *NTRK* gene fusions occur in 2–4% of cases, both in well-differentiated, poorly differentiated, and undifferentiated cancers. In the pediatric group, *NTRK* fusions are more common in papillary thyroid carcinoma (8–15%) [21, 22]. The most common fusion gene is *ETV6-NTRK3*. A positive granular cytoplasmic reaction is observed in pan-TRK IHC (Fig. 1A, B). The sensitivity of this method in thyroid cancers is low, and the rate of false-negative results varies between 25% and 50% and is more common in the case of *NTRK3* fusions [13].

Rare tumors with a low prevalence of *NTRK* gene rearrangements include glioblastoma multiforme [15, 23],

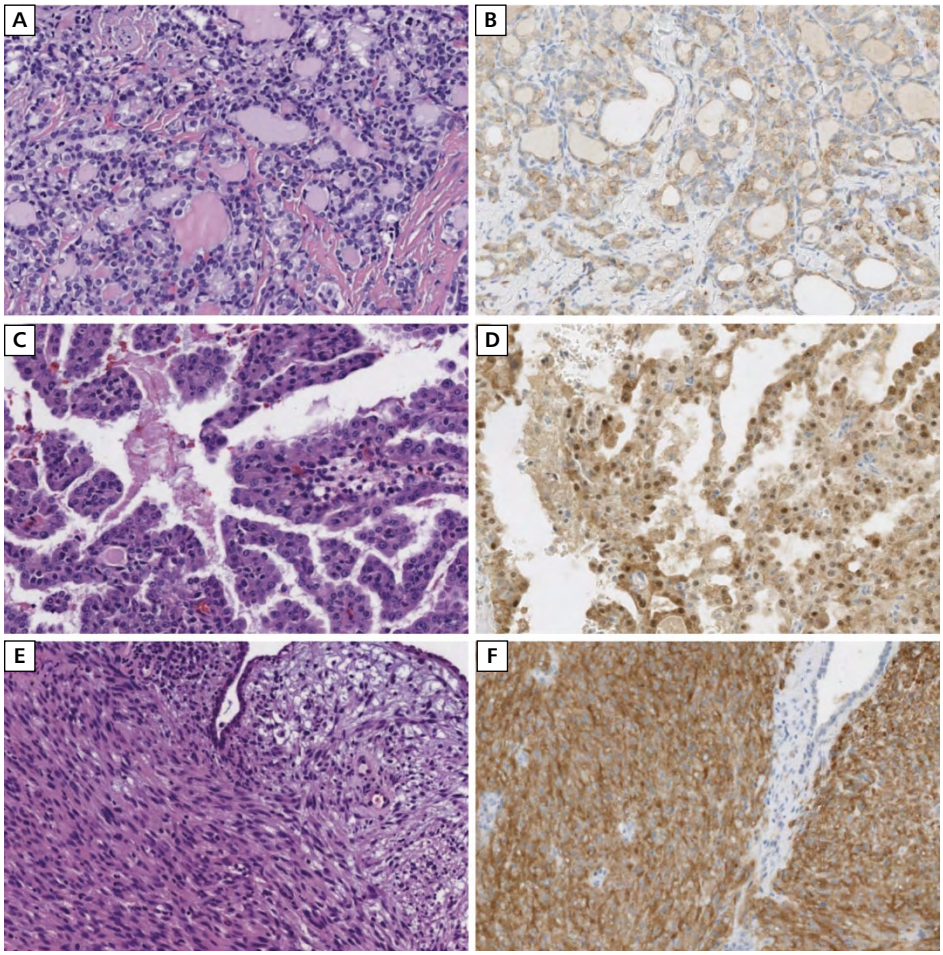

Figure 1. A. Papillary thyroid carcinoma, follicular variant with a confirmed *VIM-NTRK3* fusion gene, HE 200×; **B.** Papillary thyroid carcinoma, follicular variant with a confirmed *VIM-NTRK3* fusion gene; Pan-TRK IHC 200×, with perinuclear and cytoplasmic staining of weak and medium intensity; **C.** Secretory carcinoma of the salivary gland with the detected *ETV6-NTRK3* fusion gene, HE 200×; **D.** Secretory carcinoma of the salivary gland with the detected *ETV6-NTRK3* fusion gene; Pan-TRK IHC 200×, with a strong nuclear and cytoplasmic staining with a weak staining intensity; **E.** Spindle cell sarcoma of the cervix with a confirmed *EML4-NTRK3* fusion gene, HE 200×; **F.** Spindle cell sarcoma of the cervix with a confirmed *EML4-NTRK3* fusion gene; Pan-TRK IHC 200×, a strong cytoplasmic reaction is visible in the tumor cells, no color reaction in the overlying epithelium and the subepithelial layer

a malignant brain tumor with poor prognosis. In the case of this cancer, an effective anti-TRK-targeted therapy would be beneficial. The identification of rare glioblastomas with *NTRK* rearrangements requires reliable diagnostic tests. However, the pan-TRK IHC test is of limited use as a screening method in this group of cancers because of the high rate of false-positive results [23].

Rare tumors with a very high prevalence of *NTRK* gene fusions

This group of tumors includes cancers such as breast secretory carcinoma and salivary gland secretory carcinoma, as well as sarcomas, including infantile fibrosarcoma, cellular and mixed congenital mesoblastic nephroblastoma [14], and the recently described group of low-grade spindle cell sarcomas with *NTRK* gene rearrangements [24, 25].

Secretory carcinoma accounts for fewer than 0.05% of all infiltrating breast cancers and occurs mainly in adult women. In most cases, it is a triple-negative tumor or a tumor with low estrogen and progesterone receptor expression [26]. *ETV6-NTRK3* fusion occurs in over 90% of cases [27, 28]. Pan-TRK IHC is positive in 96% of cases. It is usually characterized by a strong nuclear reaction, and rarely by a nuclear-cytoplasmic reaction of varying intensity. *NTRK* gene rearrangements may also occur in approximately 10% of non-secretory breast cancers, most often *NTRK1* with various fusion

partners [29]. The occurrence of *NTRK* fusions in both secretory and non-secretory breast cancers supports the rationale for performing the pan-TRK IHC test as a screening method to detect patients for treatment with TRK inhibitors [30].

Secretory carcinoma with a morphology similar to that of the breast may develop in the salivary glands, most often in the parotid gland, usually in adults [31, 32]. In nearly 100% of cases, it is characterized by *ETV6* gene rearrangements, with *NTRK3* being the fusion partner in 90% of the cases [31]. On pan-TRK IHC, strong nuclear expression is seen, usually accompanied by low-intensity positive cytoplasmic staining (Fig. 1C, D). The pan-TRK IHC method is characterized by high sensitivity (91%) and specificity (nearly 100%) for the detection of secretory carcinoma of the salivary gland with *ETV6--NTRK3* fusion [33, 34]. In some cases, the nuclear reaction may be weakly intense or occur only focally, making the IHC test challenging. In addition, only cytoplasmic or membrane expression may be present in non-secretory salivary carcinomas [35]. A particular group is adenoid cystic carcinoma, in which a positive pan-TRK IHC test result is found in nearly 40% of cases (strong cytoplasmic staining), which does not correlate with the presence of NTRK gene fusions [36].

Sarcomas with widespread occurrence of *NTRK* gene fusions primarily include childhood cancer. Infantile fibrosarcoma is a fibroblastic tumor that typically affects superficial and deep soft tissues of the limbs, trunk, head, and neck. Analogous tumors in the kidney are termed cellular and mixed congenital mesoblastic nephromas. These cancers usually develop during the first year of life [37]. Approximately 90% of cases are characterized by the *ETV6-NTRK3* gene fusion [38]. Other less common molecular changes include *EML4-NTRK3* fusions or *NTRK1* and *NTRK2* gene rearrangements [16, 38]. Another group of spindle cell sarcomas with *NTRK* gene rearrangement is a newly described group of rare sarcomas with immunohistochemical co-expression of S100 and CD34 in the absence of SOX10 expression. This new category includes tumors previously described as lipofibromatosis-like neural and peripheral nerve sheath tumors. Most of these tumors develop superficially or deep within the extremities or trunk during the first two decades of life [38, 39]. In this group of sarcomas, *NTRK1* fusions with various partners such as *TPR* and *TPM3* are the most common [25]. In the described sarcomas, pan-TRK IHC reaction is positive in most cases (> 90%). In infantile fibrosarcomas, it is a strong nuclear reaction, whereas in neural tumors, similar to lipofibromatosis, it is usually a perinuclear and/or cytoplasmic reaction. In spindle cell sarcomas without *NTRK* fusion, pan-TRK IHC may only be positive in approximately 8% of the cases. The pan-TRK IHC test is characterized by high sensitivity in detecting childhood sarcomas with *NTRK* gene fusions and can be used as a screening method to qualify patients for therapy with TRK inhibitors [24].

A newly described adult sarcoma with an *NTRK* rearrangement is a cervical spindle cell sarcoma. It usually occurs in pre-menopausal women. The co-expression of S100 and CD34 characterizes the tumor cells. Desmin, estrogen receptor (ER), and progesterone receptor (PGR) are not expressed [40]. *NTRK1* and *NTRK3* rearrangements with different fusion partners occur in this group of sarcomas. Fusion genes described so far include but are not limited to *TPM3-NTRK1*, *LMNA-NTRK1*, *TPR-NTRK1*, *SPECC1L-NTRK3*, and *RBPMS-NTRK3* [40–42]. In pan-TRK IHC, TRK expression was observed in tumor cells in all cases (100%). The type of staining (cytoplasmic, perinuclear, or nuclear) may be associated with the formation of the fusion gene (Fig. 1E, F). It should be emphasized that in a low percentage of leiomyosarcomas (approximately 5%), in which there is no *NTRK* gene fusion, a positive pan-TRK IHC test is observed [40].

Tumors expressing pan-TRK IHC without *NTRK* gene fusions

A group of cancers is pan-TRK-positive IHC without *NTRK* gene fusion. Other specific molecular changes may characterize these tumors. Within the head and neck, this group of tumors includes bi-phenotypic sarcomas of the nose and paranasal sinuses (BSNS). The tumor comprises spindle-shaped cells that co-express S100 and SMA but do not express SOX10 [43]. Biphenotypic sarcomas of the nose and paranasal sinuses with non-specific pan-TRK IHC expression have been reported [44]. A characteristic feature of BSNS is rearrangement of the *PAX3* gene with the *MAML3* fusion gene [45]. Because of the microscopic image, S100 expression, and the possibility of a positive pan-TRK IHC result, it is necessary to differentiate this tumor from spindle-cell sarcomas with *NTRK* fusion. Other tumors in this area with frequent positive pan-TRK IHC without *NTRK* rearrangements are olfactory neuroblastoma, childhood small-round-cell tumors, such as Ewing's sarcoma [14, 46], adenoid cystic carcinoma of the salivary gland, and leiomyosarcoma.

Conclusions

Identifying cancer patients with *NTRK* gene fusions who could benefit from targeted therapy using TRK inhibitors requires adequate diagnostic tools. These tumors are diverse and rare. On the one hand, there is a group of rare cancers with widespread occurrence

of *NTRK* gene fusions, and on the other hand, there is a group of common cancers in which such molecular changes occur very rarely.

The pan-TRK method is characterized by high sensitivity and specificity, which may vary depending on the type of cancer. The ability to correctly interpret the results of the pan-TRK IHC test in correlation with the type of cancer is crucial in detecting cancer patients with *NTRK* gene fusions.

The pan-TRK IHC test can be used as a screening method because of its low cost, short execution time, and widespread use of IHC techniques. Pan-TRK IHC-positive tumors should be further investigated by molecular biology techniques to confirm the existence of *NTRK* fusions definitively.

Article Information and Declaration

Author contributions

M.D.: concept and design, analysis and interpretation of data, drafting of the manuscript and critical revision of the manuscript for intellectual content.
I.M.M.: critical revision of the manuscript for intellectual content.

Funding

None to declared.

Acknowledgments

None to declared.

Conflict of interest

M.D.: fees for lectures from Roche and Via Medica. Did not affect the content of this article.
I.M.M.: declares no conflict of interests.

References

1. Tsimberidou AM, Fountzilas E, Nikanjam M, et al. Review of precision cancer medicine: Evolution of the treatment paradigm. Cancer Treat Rev. 2020; 86: 102019, doi: 10.1016/j.ctrv.2020.102019, indexed in Pubmed: 32251926.
2. Huang FW, Feng FY. A Tumor-Agnostic NTRK (TRK) Inhibitor. Cell. 2019; 177(1): 8, doi: 10.1016/j.cell.2019.02.049, indexed in Pubmed: 30901551.
3. Drilon AT. inhibitors in TRK fusion-positive cancers. Ann Oncol. 2019; 30(Suppl 8): viii23–viii30.
4. Cocco E, Scaltriti M, Drilon A. NTRK fusion-positive cancers and TRK inhibitor therapy. Nat Rev Clin Oncol. 2018; 15(12): 731–747, doi: 10.1038/s41571-018-0113-0, indexed in Pubmed: 30333516.
5. Jiang T, Wang G, Liu Y, et al. Development of small-molecule tropomyosin receptor kinase (TRK) inhibitors for fusion cancers. Acta Pharm Sin B. 2021; 11(2): 355–372, doi: 10.1016/j.apsb.2020.05.004, indexed in Pubmed: 33643817.
6. Marchiò C, Scaltriti M, Ladanyi M, et al. ESMO recommendations on the standard methods to detect NTRK fusions in daily practice and clinical research. Ann Oncol. 2019; 30(9): 1417–1427, doi: 10.1093/annonc/mdz204, indexed in Pubmed: 31268127.
7. Solomon JP, Benayed R, Hechtman JF, et al. Identifying patients with NTRK fusion cancer. Ann Oncol. 2019; 30(Suppl_8): viii16–viii22, doi: 10.1093/annonc/mdz384, indexed in Pubmed: 31738428.
8. Gatalica Z, Xiu J, Swensen J, et al. Molecular characterization of cancers with NTRK gene fusions. Mod Pathol. 2019; 32(1): 147–153, doi: 10.1038/s41379-018-0118-3, indexed in Pubmed: 30171197.
9. Drilon A, Chiu CH, Fan Y, et al. trial investigators, trial investigators. Entrectinib in patients with advanced or metastatic NTRK fusion-positive solid tumours: integrated analysis of three phase 1-2 trials. Lancet Oncol. 2020; 21(2): 271–282, doi: 10.1016/S1470-2045(19)30691-6, indexed in Pubmed: 31838007.
10. Okamura R, Boichard A, Kato S, et al. Analysis of Alterations in Pan-Cancer Adult and Pediatric Malignancies: Implications for NTRK-Targeted Therapeutics. JCO Precis Oncol. 2018; 2018, doi: 10.1200/PO.18.00183, indexed in Pubmed: 30637364.
11. Frampton JE, Frampton JE. Entrectinib: A Review in NTRK+ Solid Tumours and ROS1+ NSCLC. Drugs. 2021; 81(6): 697–708, doi: 10.1007/s40265-021-01503-3, indexed in Pubmed: 33871816.
12. Sbaraglia M, Bellan E, Dei Tos AP. The 2020 WHO Classification of Soft Tissue Tumours: news and perspectives. Pathologica. 2021; 113(2): 70–84, doi: 10.32074/1591-951X-213, indexed in Pubmed: 33179614.
13. Hondelink LM, Schrader AMR, Asri Aghmuni G, et al. The sensitivity of pan-TRK immunohistochemistry in solid tumours: A meta-analysis. Eur J Cancer. 2022; 173: 229–237, doi: 10.1016/j.ejca.2022.06.030, indexed in Pubmed: 35933886.
14. Conde E, Hernandez S, Sanchez E, et al. Pan-TRK Immunohistochemistry: An Example-Based Practical Approach to Efficiently Identify Patients With NTRK Fusion Cancer. Arch Pathol Lab Med. 2021; 145(8): 1031–1040, doi: 10.5858/arpa.2020-0400-RA, indexed in Pubmed: 33112951.
15. Chiang S, Cotzia P, Hyman DM, et al. Pan-Trk Immunohistochemistry Is an Efficient and Reliable Screen for the Detection of NTRK Fusions. Am J Surg Pathol. 2017; 41(11): 1547–1551, doi: 10.1097/PAS.0000000000000911, indexed in Pubmed: 28719467.
16. Church AJ, Calicchio ML, Nardi V, et al. Recurrent EML4-NTRK3 fusions in infantile fibrosarcoma and congenital mesoblastic nephroma suggest a revised testing strategy. Mod Pathol. 2018; 31(3): 463–473, doi: 10.1038/modpathol.2017.127, indexed in Pubmed: 29099503.
17. Marchiò C, Dowsett M, Reis-Filho JS. Revisiting the technical validation of tumour biomarker assays: how to open a Pandora's box. BMC Med. 2011; 9: 41, doi: 10.1186/1741-7015-9-41, indexed in Pubmed: 21504565.
18. Roche. VENTANA pan-TRK (EPR17341) Assay 2022. https://www.rochebiomarkers.be/content/media/Files/Bijsluiter_790--70261017533EN.pdf (05.04.2023).
19. Brčić I, Godschachner TM, Bergovec M, et al. Broadening the spectrum of NTRK rearranged mesenchymal tumors and usefulness of pan-TRK immunohistochemistry for identification of NTRK fusions. Mod Pathol. 2021; 34(2): 396–407, doi: 10.1038/s41379-020-00657-x, indexed in Pubmed: 32860002.
20. Lasota J, Chłopek M, Lamoureux J, et al. Colonic Adenocarcinomas Harboring NTRK Fusion Genes: A Clinicopathologic and Molecular Genetic Study of 16 Cases and Review of the Literature. Am J Surg Pathol. 2020; 44(2): 162–73.
21. Macerola E, Proietti A, Poma AM, et al. Limited Accuracy of Pan-Trk Immunohistochemistry Screening for Rearrangements in Follicular-Derived Thyroid Carcinoma. Int J Mol Sci. 2022; 23(13), doi: 10.3390/ijms23137470, indexed in Pubmed: 35806472.
22. Ricarte-Filho J, Halada S, O'Neill A, et al. The clinical aspect of NTRK--fusions in pediatric papillary thyroid cancer. Cancer Genetics. 2022; 262-263: 57–63, doi: 10.1016/j.cancergen.2022.01.002.
23. Bourhis A, Caumont C, Quintin-Roué I, et al. Detection of NTRK fusions in glioblastoma: fluorescent in situ hybridisation is more useful than pan-TRK immunohistochemistry as a screening tool prior to RNA sequencing. Pathology. 2022; 54(1): 55–62, doi: 10.1016/j.pathol.2021.05.100, indexed in Pubmed: 34518039.
24. Hung YP, Fletcher CDM, Hornick JL. Evaluation of pan-TRK immunohistochemistry in infantile fibrosarcoma, lipofibromatosis-like neural tumour and histological mimics. Histopathology. 2018; 73(4): 634–644, doi: 10.1111/his.13666, indexed in Pubmed: 29863809.
25. Agaram NP, Zhang L, Sung YS, et al. Recurrent NTRK1 Gene Fusions Define a Novel Subset of Locally Aggressive Lipofibromatosis-like Neural Tumors. Am J Surg Pathol. 2016; 40(10): 1407–1416, doi: 10.1097/PAS.0000000000000675, indexed in Pubmed: 27259011.
26. Horowitz DP, Sharma CS, Connolly E, et al. Secretory carcinoma of the breast: results from the survival, epidemiology and end results database. Breast. 2012; 21(3): 350–353, doi: 10.1016/j.breast.2012.02.013, indexed in Pubmed: 22494666.
27. Del Castillo M, Chibon F, Arnould L, et al. Secretory Breast Carcinoma: A Histopathologic and Genomic Spectrum Characterized by a Joint Specific ETV6-NTRK3 Gene Fusion. Am J Surg Pathol. 2015;

39(11): 1458–1467, doi: 10.1097/PAS.0000000000000487, indexed in Pubmed: 26291510.
28. Krings G, Joseph NM, Bean GR, et al. Genomic profiling of breast secretory carcinomas reveals distinct genetics from other breast cancers and similarity to mammary analog secretory carcinomas. Mod Pathol. 2017; 30(8): 1086–1099, doi: 10.1038/modpathol.2017.32, indexed in Pubmed: 28548128.
29. Maund SL, Sokol ES, Ang Houle A, et al. NTRK gene fusions are detected in both secretory and non-secretory breast cancers. Pathol Int. 2022; 72(3): 187–192, doi: 10.1111/pin.13204, indexed in Pubmed: 35102630.
30. Shukla N, Roberts SS, Baki MO, et al. Successful Targeted Therapy of Refractory Pediatric Fusion-Positive Secretory Breast Carcinoma. JCO Precis Oncol. 2017; 2017, doi: 10.1200/PO.17.00034, indexed in Pubmed: 29623306.
31. Skálová A, Vanecek T, Sima R, et al. Mammary analogue secretory carcinoma of salivary glands, containing the ETV6-NTRK3 fusion gene: a hitherto undescribed salivary gland tumor entity. Am J Surg Pathol. 2010; 34(5): 599–608, doi: 10.1097/PAS.0b013e3181d9efcc, indexed in Pubmed: 20410810.
32. Bishop JA, Yonescu R, Batista D, et al. Most nonparotid „acinic cell carcinomas" represent mammary analog secretory carcinomas. Am J Surg Pathol. 2013; 37(7): 1053–1057, doi: 10.1097/PAS.0b013e3182841554, indexed in Pubmed: 23681074.
33. Sharma P, Sivakumar N, Pandiar D. Diagnostic accuracy of pan-TRK immunohistochemistry in differentiating secretory carcinoma from acinic cell carcinoma of salivary gland-A systematic review. J Oral Pathol Med. 2023; 52(3): 255–262, doi: 10.1111/jop.13373, indexed in Pubmed: 36207812.
34. Su YJ, Lee YH, Jin YT, et al. Using pan-TRK and RET Immunohistochemistry for the Detection of Fusion Types of Salivary Gland Secretory Carcinoma. Appl Immunohistochem Mol Morphol. 2022; 30(4): 264–272, doi: 10.1097/PAI.0000000000001003, indexed in Pubmed: 35384876.
35. Hung YP, Jo VY, Hornick JL. Immunohistochemistry with a pan-TRK antibody distinguishes secretory carcinoma of the salivary gland from acinic cell carcinoma. Histopathology. 2019; 75(1): 54–62, doi: 10.1111/his.13845, indexed in Pubmed: 30801752.
36. Guibourg B, Cloarec E, Conan-Charlet V, et al. EPR17341 and A7H6R pan-TRK Immunohistochemistry Result in Highly Different Staining Patterns in a Series of Salivary Gland Tumors. Appl Immunohistochem Mol Morphol. 2020; 28(9): 719–724, doi: 10.1097/PAI.0000000000000825, indexed in Pubmed: 32187023.
37. Orbach D, Rey A, Cecchetto G, et al. Infantile fibrosarcoma: management based on the European experience. J Clin Oncol. 2010; 28(2): 318–323, doi: 10.1200/JCO.2009.21.9972, indexed in Pubmed: 19917847.
38. Davis JL, Lockwood CM, Stohr B, et al. Expanding the Spectrum of Pediatric NTRK-rearranged Mesenchymal Tumors. Am J Surg Pathol. 2019; 43(4): 435–445, doi: 10.1097/PAS.0000000000001203, indexed in Pubmed: 30585824.
39. Antonescu CR. Emerging soft tissue tumors with kinase fusions: An overview of the recent literature with an emphasis on diagnostic criteria. Genes Chromosomes Cancer. 2020; 59(8): 437–444, doi: 10.1002/gcc.22846, indexed in Pubmed: 32243019.
40. Chiang S, Cotzia P, Hyman DM, et al. NTRK Fusions Define a Novel Uterine Sarcoma Subtype With Features of Fibrosarcoma. Am J Surg Pathol. 2018; 42(6): 791–798, doi: 10.1097/PAS.0000000000001055, indexed in Pubmed: 29553955.
41. Nilforoushan N, Wethington SL, Nonogaki H, et al. NTRK-Fusion Sarcoma of the Uterine Cervix: Report of 2 Cases With Comparative Clinicopathologic Features. Int J Gynecol Pathol. 2022; 41(6): 642–648, doi: 10.1097/PGP.0000000000000834, indexed in Pubmed: 34723848.
42. Hodgson A, Pun C, Djordjevic B, et al. NTRK-rearranged Cervical Sarcoma: Expanding the Clinicopathologic Spectrum. Int J Gynecol Pathol. 2021; 40(1): 73–77, doi: 10.1097/PGP.0000000000000669, indexed in Pubmed: 32044823.
43. Kuczkiewicz-Siemion O, Prochorec-Sobieszek M, Rysz M, et al. Small Biopsy Samples: Are They Representative for Biphenotypic Sinonasal Sarcoma? Diagnostics (Basel). 2022; 12(10), doi: 10.3390/diagnostics12102528, indexed in Pubmed: 36292216.
44. Nichols MM, Alruwaii F, Chaaban M, et al. Biphenotypic Sinonasal Sarcoma with a Novel PAX3::FOXO6 Fusion: A Case Report and Review of the Literature. Head Neck Pathol. 2023; 17(1): 259–264, doi: 10.1007/s12105-022-01479-w, indexed in Pubmed: 36169791.
45. Fritchie KJ, Jin L, Wang X, et al. Fusion gene profile of biphenotypic sinonasal sarcoma: an analysis of 44 cases. Histopathology. 2016; 69(6): 930–936, doi: 10.1111/his.13045, indexed in Pubmed: 27454570.
46. Wong DD, Vargas AC, Bonar F, et al. NTRK-rearranged mesenchymal tumours: diagnostic challenges, morphological patterns and proposed testing algorithm. Pathology. 2020; 52(4): 401–409, doi: 10.1016/j.pathol.2020.02.004, indexed in Pubmed: 32278476.

Datis Kalali

Medical School, University of Cyprus, Nicosia, Cyprus

Potassium imbalances induced by systemic cancer therapy: pathophysiology and potential therapeutic strategies

Address for correspondence:
Mr. Datis Kalali
Medical School, University of Cyprus,
Palios Dromos Lefkosias-Lemesou 215,
Nicosia, Cyprus
e-mail: kalali.datis@ucy.ac.cy

Oncology in Clinical Practice
DOI: 10.5603/ocp.96314
Copyright © 2024 Via Medica
ISSN 2450–1654
e-ISSN 2450–6478

ABSTRACT

Imbalances of serum potassium levels are common complications in patients receiving systemic antineoplastic therapy. These conditions can provoke further complications such as cardiac arrhythmia and paralysis due to the significant role of potassium in muscle physiology. Many cytotoxic drugs and novel targeted therapy agents have been found to induce hypokalemia and occasionally hyperkalemia. Therefore, they should be administered carefully and a broad understanding of the topic is necessary for medical oncologists. To this end, the present narrative review explores the pathophysiology of potassium disorders induced by systemic therapy and points out some therapeutic strategies for reversing them.

Keywords: chemotherapy, hyperkalemia, hypokalemia, systemic therapy, targeted therapy

Oncol Clin Pract 2024; 20, 1: 22–26

Introduction

Electrolyte disorders are one of the most serious and, in some cases, life-threatening medical conditions worldwide [1]. Specifically, imbalances of serum potassium (K^+) levels, namely hyperkalemia and hypokalemia, are known to induce several serious conditions [2]. Normal serum potassium levels in adults range from 3.5 to 5.2 mmol/L, and any values out of this range are considered a pathological condition [1, 2]. Both hyperkalemia and hypokalemia, due to the significant role of potassium ions in muscular physiology, can lead to cardiac arrhythmia, muscle weakness, cramps, and even paralysis [3]. Their onset is usually sudden and can cause cardiac arrhythmia quickly, and thus they should be diagnosed and treated urgently.

Electrolyte imbalances are prevalent in patients receiving systemic cancer therapy, especially in those receiving cytotoxic drugs [4]. Although these imbalances may seldom be caused by paraneoplastic syndromes, in most cases, they are due to the effects of anticancer drugs on the cells, kidneys, and homeostasis mechanisms [5]. With potassium imbalances being one of the most serious categories of electrolyte disorders, the present narrative review aims to explore all the underlying mechanisms through which anticancer drugs induce these imbalances and present all current therapeutic strategies for reversing them.

Hypokalemia induced by systemic therapy

Hypokalemia is defined as a serum potassium level of less than 3.5 mmol/L, and in cases where the level is less than 2.5 mmol/L, the hypokalemia is categorized as severe [2, 6].

Received: 02.07.2023 Accepted: 18.08.2023 Early publication date: 18.09.2023

This article is available in open access under Creative Common Attribution-Non-Commercial-No Derivatives 4.0 International (CC BY-NC-ND 4.0) license, allowing to download articles and share them with others as long as they credit the authors and the publisher, but without permission to change them in any way or use them commercially.

Pathophysiology

There are several mechanisms through which anticancer drugs can induce low potassium levels. Firstly, chemotherapy and some targeted therapy drugs are known to bear a risk of inducing emesis and diarrhea as major side effects [7]. Consistent vomiting and diarrheal excretions can cause excessive potassium loss through the lost body fluids [8]. Moreover, many antineoplastic agents are known to induce magnesium deficiency by binding to proteins in the nephron and decreasing magnesium reabsorption [9]. Magnesium deficiency, in turn, can lead to hypokalemia since a decrease in intracellular magnesium concentration causes inactivation of the renal outer medullary potassium channel (ROMK) and thus decreases potassium reabsorption in the thick ascending loop of Henle [10].

At the same time, many chemotherapeutic agents are known to be nephrotoxic, and, therefore, they lead to acute or even chronic kidney failure and injury as well as tubular necrosis due to cytotoxicity [11, 12]. It is worth noting that approximately 80% of patients undergoing systemic cancer therapy receive nephrotoxic agents in their therapeutic regimens [12]. During the polyuric phase of acute tubular necrosis, there is a great loss of potassium through the kidneys, and hence hypokalemia is a common complication [13].

It is also worth mentioning that antineoplastic agents have the potential to cause inflammation and necrosis in the intestinal epithelium [14]. In this manner, they can lead to reduced potassium absorption in the small intestine and thus hypokalemia [15]. Figure 1 summarizes the mechanisms through which anticancer agents can trigger the development of hypokalemia.

Specific antineoplastic agents have been shown to be related to the development of hypokalemia. Platinum-based antineoplastic drugs, namely cisplatin, carboplatin, and oxaliplatin are known to induce several electrolyte disorders including hypokalemia [16]. Cisplatin can cause hypomagnesemia by interfering with magnesium reabsorption in the loop of Henle and the distal tube of the nephron [17, 18]. It has been indicated that carboplatin and oxaliplatin can also induce hypomagnesemia, but to a lesser extent [18]. In turn, magnesium deficiency can lead to significantly decreased renal potassium reabsorption and hypokalemia [10, 16]. Moreover, unlike carboplatin and oxaliplatin, which have a great affinity for plasma proteins, cisplatin circulates freely in the plasma and is filtered to a great extent in the kidneys, and its cytotoxic nature can induce nephrotoxicity and, in some cases, acute tubular necrosis, hence leading to hypokalemia [19–21]. It is also worth mentioning that all platinum-based agents can trigger intestinal inflammation, and subsequently induce hypokalemia [22].

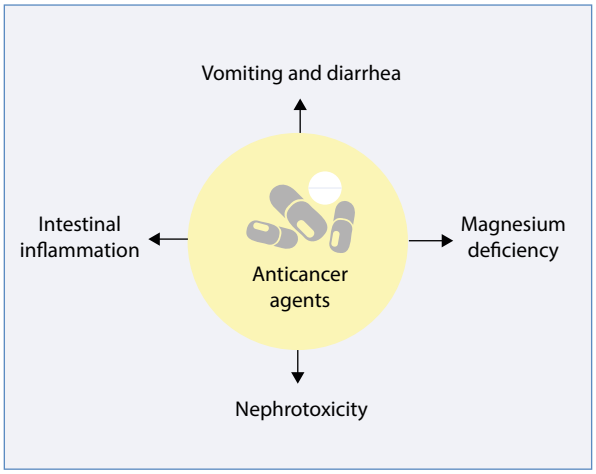

Figure 1. Mechanisms of hypokalemia induction by systemic therapy

Antimetabolites have also been found to be associated with plunges in serum potassium levels. Indeed, the dihydrofolate reductase inhibitor methotrexate, which is included in many chemotherapy regimens, is known to increase the risk of acute kidney injury and thus that of hypokalemia [23]. Furthermore, the antimetabolite azacytidine is known to induce renal tubular dysfunction in many patients and, therefore, reduce tubular potassium reabsorption [24]. It should also be noted that the drug ifosfamide, which can act both as an alkylating agent and as an antimetabolite is associated with the development of Fanconi syndrome, which can cause both tubular dysfunction and hypokalemia [25].

At the same time, novel targeted therapy agents, which act as monoclonal antibodies, can also induce hypokalemia through the previously mentioned mechanisms. Specifically, the anti-epidermal growth factor receptor (anti-EGFR) antibodies cetuximab and panitumumab have been shown to be related to the development of magnesium deficiency and thereby lower serum potassium [26]. In fact, a meta-analysis published in 2010 indicated that the incidence of severe hypokalemia in patients receiving cetuximab in their therapeutic regimen is approximately twofold compared to patients receiving regimens without cetuximab [27]. Moreover, the monoclonal antibodies trastuzumab and pertuzumab are known to be diarrheagenic and hence increase the risk of developing hypokalemia [28]. It is worth noting that other drugs, such as irinotecan and immune checkpoint inhibitors, are known to induce chronic and severe diarrhea, hence increasing the possibility of developing hypokalemia [29]. Table 1 [17–19, 22–26, 28] summarizes all antineoplastic drugs known to increase the risk of hypokalemia, alongside the mechanism through which they induce the condition.

Table 1. Anticancer agents inducing hypokalemia

Anticancer agent(s)	Mechanisms of hypokalemia induction	References
Cisplatin	Development of hypomagnesemia, nephrotoxicity, and decreased intestinal K^+ reabsorption	[17, 19, 22]
Carboplatin and oxaliplatin	Development of hypomagnesemia and decreased intestinal K^+ reabsorption	[18, 22]
Methotrexate	Nephrotoxicity (acute kidney injury)	[23]
Azacitidine	Nephrotoxicity (renal tubular dysfunction)	[24]
Ifosfamide	Fanconi syndrome (renal tubular dysfunction)	[25]
Cetuximab and panitumumab	Development of hypomagnesemia	[26]
Trastuzumab and pertuzumab	Induction of diarrhea	[28]

K+ — potassium

Management

After evaluation of biochemical blood test results, given that magnesium deficiency is identified simultaneously with hypokalemia, initially magnesium levels must be restored using oral or intravenous magnesium administration according to the standard operating procedures of the particular healthcare center [30]. Potassium replacement therapy should certainly be undertaken to restore serum potassium levels. Therapy may include oral or intravenous administration of potassium [31]. Hospitalization is not needed in cases of mild hypokalemia, where cardiac arrhythmias are not present [32]. In cases of severe hypokalemia or where the patient is unable to receive oral doses due to excessive vomiting, intravenous administration should be considered [33]. Also, it is worth mentioning that 0.9% normal saline is preferred over 5% dextrose as a solvent for intravenous therapy, as a 5% dextrose solution may induce absorption of potassium ions into the intracellular fluid [31, 34].

Hyperkalemia induced by systemic therapy

Hyperkalemia is defined as a serum potassium level of more than 5.2 mmol/L, and in cases where the level is more than 6.5 mmol/L, the hyperkalemia is categorized as severe [2, 35].

Pathophysiology

Hyperkalemia is an occasional complication in patients undergoing systemic therapy, mainly due to two reasons: tumor lysis syndrome and chronic kidney disease (CKD) [5]. The tumor lysis syndrome occurs mainly in patients with hematological malignancies or sometimes in patients with very large solid tumors, undergoing systemic therapy [36]. The latter syndrome occurs when destroyed cancerous cells release their contents into the bloodstream and since potassium concentrations are relatively high in the intracellular fluid, hyperkalemia is often induced [36, 37]. It is worth mentioning that the use of the targeted therapy drugs venetoclax, obinutuzumab, dinaciclib, and alvocidib and the use of chimeric antigen receptor T-cells (CAR-Ts) have been found to be associated with a high incidence rate of tumor lysis syndrome [38].

On the other hand, CKD can seldom occur as a long-term complication of anticancer systemic therapy [39]. In such cases, due to improper kidney function, plasma potassium excretion rates are decreased, leading to the occurrence of hyperkalemia [40]. CKD can occur in all patients receiving nephrotoxic chemotherapy, such as cisplatin and ifosfamide, over a long time [41].

Management

Generally, according to experts, initial management of hyperkalemia includes 10 mL intravenous administration of 10% calcium gluconate solution, followed by the simultaneous administration of 50 mL dextrose with 10 units of insulin and a final administration of nebulized salbutamol [42]. In the case of mild hyperkalemia where cardiac rhythm changes are not present, hospitalization is not usually required and a regimen of oral sodium polystyrene sulfonate alongside a salbutamol inhaler can be administered in an outpatient setting [42, 43]. For cases of severe hyperkalemia or when cardiac arrhythmias are present, hospitalization and the administration of calcium gluconate are deemed necessary [44]. In cases when kidney failure is not suspected, the administration of loop diuretics is not recommended [45, 46]. Otherwise, loop diuretics, such as furosemide, may be administered to reverse the hyperkalemia and hypervolemia induced by CKD, after consultation with a nephrologist [46]. Occasionally, hemodialysis may be required in patients presenting severe chronic hyperkalemia due to CKD [47].

Conclusions

As seen in this review, potassium imbalances are common complications in patients receiving systemic anticancer therapy, and due to the life-threatening

nature of these conditions, they should be diagnosed and treated immediately. Overall, it is of paramount significance for medical oncologists to have a broad understanding of these mechanisms and underlying causes of the disorders, to choose an appropriate therapeutic strategy and to take preventive measures for patients receiving certain antineoplastic drugs.

Article Information and Declarations

Author contributions

D.K.: study design, manuscript writing.

Funding

None.

Acknowledgments

None.

Conflict of interest

None.

Supplementary material

None.

References

1. Hoorn EJ, Tuut MK, Hoorntje SJ, et al. Dutch guideline for the management of electrolyte disorders--2012 revision. Neth J Med. 2013; 71(3): 153–165, indexed in Pubmed: 23712815.
2. Viera AJ, Wouk N. Potassium Disorders: Hypokalemia and Hyperkalemia. Am Fam Physician. 2015; 92(6): 487–495, indexed in Pubmed: 26371733.
3. Elliott TL, Braun M. Electrolytes: Potassium Disorders. FP Essent. 2017; 459: 21–28, indexed in Pubmed: 28806047.
4. Palumbo MO, Kavan P, Miller WH, et al. Systemic cancer therapy: achievements and challenges that lie ahead. Front Pharmacol. 2013; 4: 57, doi: 10.3389/fphar.2013.00057, indexed in Pubmed: 23675348.
5. Verzicco I, Regolisti G, Quaini F, et al. Electrolyte Disorders Induced by Antineoplastic Drugs. Front Oncol. 2020; 10: 779, doi: 10.3389/fonc.2020.00779, indexed in Pubmed: 32509580.
6. SEVERE HYPOKALÆMIA. The Lancet. 1980; 315(8167): 520–521, doi: 10.1016/s0140-6736(80)92772-5.
7. Sharma R, Tobin P, Clarke SJ. Management of chemotherapy-induced nausea, vomiting, oral mucositis, and diarrhoea. Lancet Oncol. 2005; 6(2): 93–102, doi: 10.1016/S1470-2045(05)01735-3, indexed in Pubmed: 15683818.
8. Unwin RJ, Luft FC, Shirley DG. Pathophysiology and management of hypokalemia: a clinical perspective. Nat Rev Nephrol. 2011; 7(2): 75–84, doi: 10.1038/nrneph.2010.175, indexed in Pubmed: 21278718.
9. Berenguer-Francés M. Magnesium Deficiency in a Patient on Chemotherapy-Radiotherapy Treatment for Cervical Cancer: Case Report and Review. Gaceta Mexicana de Oncolog a. 2022; 16(2), doi: 10.24875/j.gamo.17000021.
10. Huang CL, Kuo E. Mechanism of hypokalemia in magnesium deficiency. J Am Soc Nephrol. 2007; 18(10): 2649–2652, doi: 10.1681/ASN.2007070792, indexed in Pubmed: 17804670.
11. Nicolaysen A. Nephrotoxic Chemotherapy Agents: Old and New. Adv Chronic Kidney Dis. 2020; 27(1): 38–49, doi: 10.1053/j.ackd.2019.08.005, indexed in Pubmed: 32147000.
12. Chen C, Xie D, Gewirtz DA, et al. Nephrotoxicity in cancer treatment: An update. Adv Cancer Res. 2022; 155: 77–129, doi: 10.1016/bs.acr.2022.03.005, indexed in Pubmed: 35779877.
13. Pathophysiology review: acute tubular necrosis. Nursing. 2010; 40(4): 46–47, doi: 10.1097/01.NURSE.0000369866.13552.7e, indexed in Pubmed: 20234271.
14. Dahlgren D, Sjöblom M, Hellström PM, et al. Chemotherapeutics-Induced Intestinal Mucositis: Pathophysiology and Potential Treatment Strategies. Front Pharmacol. 2021; 12: 681417, doi: 10.3389/fphar.2021.681417, indexed in Pubmed: 34017262.
15. Heitzmann D, Warth R. Physiology and pathophysiology of potassium channels in gastrointestinal epithelia. Physiol Rev. 2008; 88(3): 1119–1182, doi: 10.1152/physrev.00020.2007, indexed in Pubmed: 18626068.
16. Oronsky B, Caroen S, Oronsky A, et al. Electrolyte disorders with platinum-based chemotherapy: mechanisms, manifestations and management. Cancer Chemother Pharmacol. 2017; 80(5): 895–907, doi: 10.1007/s00280-017-3392-8, indexed in Pubmed: 28730291.
17. Lajer H, Daugaard G. Cisplatin and hypomagnesemia. Cancer Treat Rev. 1999; 25(1): 47–58, doi: 10.1053/ctrv.1999.0097, indexed in Pubmed: 10212589.
18. Liamis G, Hoorn EJ, Florentin M, et al. An overview of diagnosis and management of drug-induced hypomagnesemia. Pharmacol Res Perspect. 2021; 9(4): e00829, doi: 10.1002/prp2.829, indexed in Pubmed: 34278747.
19. Holditch SJ, Brown CN, Lombardi AM, et al. Recent Advances in Models, Mechanisms, Biomarkers, and Interventions in Cisplatin-Induced Acute Kidney Injury. Int J Mol Sci. 2019; 20(12), doi: 10.3390/ijms20123011, indexed in Pubmed: 31226747.
20. Wadd NJ, Tiplady C, Roberts JT. Cisplatin and acute tubular necrosis. Clin Oncol (R Coll Radiol). 1997; 9(4): 267–268, doi: 10.1016/s0936-6555(97)80016-7, indexed in Pubmed: 9315405.
21. Kato R, Sato T, Iwamoto A, et al. Interaction of platinum agents, cisplatin, carboplatin and oxaliplatin against albumin in vivo rats and in vitro study using inductively coupled plasma-mass spectrometory. Biopharm Drug Dispos. 2019; 40(7): 242–249, doi: 10.1002/bdd.2197, indexed in Pubmed: 31219617.
22. Abu-Sbeih H, Mallepally N, Goldstein R, et al. Gastrointestinal toxic effects in patients with cancer receiving platinum-based therapy. J Cancer. 2020; 11(11): 3144–3150, doi: 10.7150/jca.37777, indexed in Pubmed: 32231718.
23. Steward JS, Bullard HM, O'Rourke TJ, et al. Effect of single agent high-dose methotrexate-related acute kidney injury on length of hospitalization and relative dose intensity in adult patients with central nervous system lymphoma. J Oncol Pharm Pract. 2017; 23(7): 496–501, doi: 10.1177/1078155216665244, indexed in Pubmed: 27543094.
24. Peterson BA, Collins AJ, Vogelzang NJ, et al. 5-Azacytidine and renal tubular dysfunction. Blood. 1981; 57(1): 182–185, indexed in Pubmed: 6160887.
25. Das S, Valencia DN, Fershko A. Partial Fanconi Syndrome Induced by Ifosfamide. Cureus. 2019; 11(1): e3947, doi: 10.7759/cureus.3947, indexed in Pubmed: 30937245.
26. Maliakal P, Ledford A. Electrolyte and protein imbalance following anti-EGFR therapy in cancer patients: A comparative study. Exp Ther Med. 2010; 1(2): 307–311, doi: 10.3892/etm_00000047, indexed in Pubmed: 22993543.
27. Cao Y, Liu L, Liao C, et al. Meta-analysis of incidence and risk of hypokalemia with cetuximab-based therapy for advanced cancer. Cancer Chemother Pharmacol. 2010; 66(1): 37–42, doi: 10.1007/s00280-009-1131-5, indexed in Pubmed: 19760217.
28. Sakaguchi H, Ishihara M, Sawaki A, et al. Safety of Trastuzumab and Pertuzumab for Patients with Previously Treated Her2 Positive Advanced Breast Cancer. Ann Oncol. 2014; 25: v92, doi: 10.1093/annonc/mdu436.78.
29. Nishida T, Iijima H, Adachi S. Immune checkpoint inhibitor-induced diarrhea/colitis: Endoscopic and pathologic findings. World J Gastrointest Pathophysiol. 2019; 10(2): 17–28, doi: 10.4291/wjgp.v10.i2.17, indexed in Pubmed: 31559106.
30. Ahmed F, Mohammed A. Magnesium: The Forgotten Electrolyte-A Review on Hypomagnesemia. Med Sci (Basel). 2019; 7(4), doi: 10.3390/medsci7040056, indexed in Pubmed: 30987399.
31. Kardalas E, Paschou SA, Anagnostis P, et al. Hypokalemia: a clinical update. Endocr Connect. 2018; 7(4): R135–R146, doi: 10.1530/EC-18-0109, indexed in Pubmed: 29540487.
32. Abensur Vuillaume L, Rossignol P, Lamiral Z, et al. Hyperkalaemia and hypokalaemia outpatient management: a survey of 500 French general practitioners. ESC Heart Fail. 2020; 7(5): 2042–2050, doi: 10.1002/ehf2.12834, indexed in Pubmed: 32602236.
33. Kraft MD, Btaiche IF, Sacks GS, et al. Treatment of electrolyte disorders in adult patients in the intensive care unit. Am J Health Syst Pharm. 2005; 62(16): 1663–1682, doi: 10.2146/ajhp040300, indexed in Pubmed: 16085929.

34. Ashurst J, Sergent SR, Wagner BJ, et al. Evidence-Based Management Of Potassium Disorders In The Emergency Department. Emerg Med Pract. 2016; 18(11): 1–24, indexed in Pubmed: 27775507.
35. An JN, Lee JP, Jeon HJ, et al. Severe hyperkalemia requiring hospitalization: predictors of mortality. Crit Care. 2012; 16(6): R225, doi: 10.1186/cc11872, indexed in Pubmed: 23171442.
36. Howard SC, Jones DP, Pui CH. The tumor lysis syndrome. N Engl J Med. 2011; 364(19): 1844–1854, doi: 10.1056/NEJMra0904569, indexed in Pubmed: 21561350.
37. Rahmani B, Patel S, Seyam O, et al. Current understanding of tumor lysis syndrome. Hematol Oncol. 2019; 37(5): 537–547, doi: 10.1002/hon.2668, indexed in Pubmed: 31461568.
38. Howard SC, Trifilio S, Gregory TK, et al. Tumor lysis syndrome in the era of novel and targeted agents in patients with hematologic malignancies: a systematic review. Ann Hematol. 2016; 95(4): 563–573, doi: 10.1007/s00277-015-2585-7, indexed in Pubmed: 26758269.
39. Francisco Ade, Macía M, Alonso F, et al. Onco-Nephrology: Cancer, chemotherapy and kidney. Nefrología (English Edition). 2019; 39(5): 473–481, doi: 10.1016/j.nefroe.2018.10.016.
40. Watanabe R. Hyperkalemia in chronic kidney disease. Rev Assoc Med Bras (1992). 2020; 66Suppl 1(Suppl 1): s31–s36, doi: 10.1590/1806-9282.66.S1.31, indexed in Pubmed: 31939533.
41. Chiruvella V, Annamaraju P, Guddati AK. Management of nephrotoxicity of chemotherapy and targeted agents: 2020. Am J Cancer Res. 2020; 10(12): 4151–4164, indexed in Pubmed: 33414992.
42. Palmer BF, Carrero JJ, Clegg DJ, et al. Clinical Management of Hyperkalemia. Mayo Clin Proc. 2021; 96(3): 744–762, doi: 10.1016/j.mayocp.2020.06.014, indexed in Pubmed: 33160639.
43. Charytan D, Goldfarb DS. Indications for hospitalization of patients with hyperkalemia. Arch Intern Med. 2000; 160(11): 1605–1611, doi: 10.1001/archinte.160.11.1605, indexed in Pubmed: 10847253.
44. Celebi Yamanoglu NG, Yamanoglu A. The effect of calcium gluconate in the treatment of hyperkalemia. Turk J Emerg Med. 2022; 22(2): 75–82, doi: 10.4103/2452-2473.342812, indexed in Pubmed: 35529029.
45. Elliott MJ, Ronksley PE, Clase CM, et al. Management of patients with acute hyperkalemia. CMAJ. 2010; 182(15): 1631–1635, doi: 10.1503/cmaj.100461, indexed in Pubmed: 20855477.
46. Mushiyakh Y, Dangaria H, Qavi S, et al. Treatment and pathogenesis of acute hyperkalemia. J Community Hosp Intern Med Perspect. 2011; 1(4), doi: 10.3402/jchimp.v1i4.7372, indexed in Pubmed: 23882341.
47. Pirklbauer M. Hemodialysis treatment in patients with severe electrolyte disorders: Management of hyperkalemia and hyponatremia. Hemodial Int. 2020; 24(3): 282–289, doi: 10.1111/hdi.12845, indexed in Pubmed: 32436307.

VIA MEDICA

REVIEW ARTICLE

Maryam Zamanian, Iraj Abedi

Department of Medical Physics, School of Medicine, Isfahan University of Medical Sciences, Isfahan, Iran

Convolutional neural networks in auto-segmentation of nasopharyngeal carcinoma tumor — a systematic review and meta-analysis

Address for correspondence:
Dr. Iraj Abedi
Department of Medical Physics,
School of Medicine, Isfahan University
of Medical Sciences
Hezar Jarib Street, Postal code:
8174673461, Isfahan, Iran
e-mail: I.abedi@med.mui.ac.ir

Oncology in Clinical Practice
DOI: 10.5603/OCP.2023.0040
Copyright © 2024 Via Medica
ISSN 2450–1654
e-ISSN 2450–6478

ABSTRACT

Introduction. Segmentation is one of the main stages of the treatment planning system (TPS), especially in nasopharyngeal carcinoma (NPC), because it is very heterogeneous and penetrates the skull bone tissue. An automated method to reduce the workload and human error caused by the lack of expertise and perspective would be very helpful. This meta-analysis evaluated the ability of convolutional neural networks (CNNs) to plan auto-segmentation computed tomography (CT) and magnetic resonance imaging (MRI) modalities.

Material and methods. Articles published in PubMed, Scholar, and Cochrane databases were examined. The risk of bias was evaluated by the QUADAS-2 tool. The dice similarity coefficient (DSC) as the effect size and standard error (SE) as the precision index were analyzed by random effects. To calculate the degree of heterogeneity and its agent, we used (I^2 and τ^2) and meta-regression analysis ($p < 0.05$). A funnel plot was used to check for publication bias.

Results. In general, eight studies on CT and 12 on MRI modalities were selected from 3601 studies. The heterogeneity based on (I^2 and τ^2) and DSC values (with a 95% confidence interval) for CT and MRI modalities were 88.7% ($\tau^2 = 0.011$), 0.67 (0.62–0.72), and 81.42% ($\tau^2 = 0.01$), 0.76 (0.72–0.80), respectively.

Conclusions. CNNs' ability to segment both CT and MRI modalities is at a medium level, and its improvement can make it more suitable for clinical use.

Keywords: convolutional neural network, computed tomography, magnetic resonance imaging, nasopharyngeal carcinoma, segmentation

Oncol Clin Pract 2024; 20, 1: 27–39

Introduction

Nasopharyngeal carcinoma (NPC) is the most common type of otolaryngological cancer that grows on the walls of the nasopharyngeal cavity. It has a heterogeneous distribution in different geographical regions, with the highest prevalence observed in Southeast Asia and moderate prevalence in South Asia and North Africa [1]. As the tumor grows and its grade increases to T4, it gradually spreads to the skeletal structure of the skull, even to the intracranial area [2].

The location of the tumor in the head and neck region, surrounding vital organs, and high sensitivity to radiation are reasons for choosing radiotherapy as

Received: 11.04.2023 Accepted: 06.09.2023 Early publication date: 17.10.2023

This article is available in open access under Creative Common Attribution-Non-Commercial-No Derivatives 4.0 International (CC BY-NC-ND 4.0) license, allowing to download articles and share them with others as long as they credit the authors and the publisher, but without permission to change them in any way or use them commercially.

the best treatment method [3]. The most important step in the treatment planning system (TPS), which is performed by an experienced radiation oncology specialist, is contouring of the tumor tissue (PTV) and the organs at risk (OARs) before starting the treatment, which can involve two imaging modalities: computed tomography (CT), magnetic resonance imaging (MRI), or both of them [4].

Magnetic resonance imaging can provide the best soft tissue contrast for NPC, and it is a painless and non-invasive method that does not require ionizing radiation, which makes it possible to repeat it to take different sequences (such as T1W, T2W, and T1C). It can also show the shape and location of the lesion well [5]. Because of NPC location, its spread to bone tissues, and the advantage of CT images, including the quality of imaging with better contrast in bony areas and high speed, CT is the best choice. In addition, CT scans take less time than MRI and are cost-effective and available. Centers may use either of these two modalities according to the patient's condition [6, 7].

Image segmentation is a time-consuming person-dependent task that requires the rendering skill of the oncologist; therefore, its correct execution creates a large workload, and the smallest error in segmentation affects the treatment plan [8]. In addition, segmentation of NPC tumors is more difficult due to their greater diversity and heterogeneous intensity compared to other tumors. One of the other challenges and problems of NPC segmentation is its metamorphic form, and each stage of treatment may require re-segmentation. For this reason, an automatic and accurate method to implement segmentation would be of great help [2, 9].

Among alternative methods that have been tested in recent years is the use of artificial intelligence for the automatic and accurate implementation of all TPS parts in various tumors [10]. In recent studies, Convolutional Neural Networks (CNNs) are evaluated rapidly in image auto-segmentation [11–13]. Therefore, in this study, we decided to comprehensively analyze the available literature on CNN ability to automatically perform NPC tumor segmentation in CT and MRI modalities.

Material and methods

We launched a comprehensive and systematic search of reliable sources to learn whether CNNs have sufficient ability to perform accurate segmentation. The study was registered at the beginning of its conceptualization in PROSPERO, the international open-access Prospective Register of Systematic Reviews (CRD42022379228).

Search strategy

We searched electronic databases, including MEDLINE (through PubMed) and Cochrane Library. In addition, a Google Scholar search of gray literature and publications in the arXiv database was conducted. There were no limitations regarding study language. Considering that the investigation of CNNs does not have a long history and has been evaluated only in recent years, no time limit was set for the search (in the year 2022). The terms used for the search strategy included ("Nasopharyngeal carcinoma") AND ("Segmentation" OR "U-Net" OR "U-Res-Net" OR "Res-UNet") AND ("Computed tomography" OR "CT" OR "Magnetic resonance imaging" OR "MRI"). PubMed was searched using the restriction of placing the [Title/Abstract] fields in all terms, and no field restriction was placed in Scholar.

After searching, Endnote software was used to collect articles. First, duplicate articles were excluded from the study. The screening of the studies was carried out in three steps: title, abstract, and full text. The search and screening of articles were performed by two researchers. Our assessment overlapped in 95% of cases, and in the remaining cases, we resolved differences of opinion based on the eligibility criteria.

Study exclusion criteria

All the selected studies investigated the power of all CNNs in relation to the NPC tumor segment, and the examination of OAR segments was excluded from the study. In terms of the investigated indicators, studies that reported the dice similarity coefficient (DSC) index were included. Studies in which the size of the network training samples was under 15 and studies that combined positron emission tomography (PET) images with CT and MRI were excluded from this analysis. All study reviews, case reports, editorials, and letters were excluded from the study.

Data extraction

The results were classified into two subgroups: CT and MRI modalities. The data extracted from the studies included the name of the first author, country and year of publication, network architecture, sample size and classification for training, external validation and testing, tumor staging, epochs number, learning rate, batch size, type of datasets, network dimension, CT contrast type, MRI sequence, feature extraction software, and processor characterization.

Furthermore, the indices of network performance included the DSC index and Hausdorff distance (HD) extracted from the studies. Meta-analysis results were

reported using the 2020-PRISMA criteria, and the study protocol was written accordingly (Supplementary Tab. S1).

Quality assessment (risk of bias)

The Quality Assessment of Diagnostic Accuracy Studies-2 (QUADAS-2) tool was used to evaluate the quality of m eta-analyses and the risk of bias. This tool evaluates the quality of diagnostic studies and includes four key domains: (1) patient selection random sampling, (2) index test (assessment blinded for and independent of reference test), (3) reference standard (valid reference test, assessment independent of index test), and (4) flow and timing (sufficient time between index and reference, all data points included in the analysis). The set of questions for each domain had answers on three scores including "yes-(1) score", "no-(0) score", and "unclear-(0) score". This step was implemented by two persons.

Statistical analysis

Stata software (version 17.0; College Station, TX 77845, US) was used to perform all statistical calculations. Excel software (Microsoft 2016) was used to extract primary information from the articles and perform some basic calculations. One of the most important indices for evaluating CNN segmentation results is the DSC index, which is used as effect size. The heterogeneity studies were calculated by a random effect model, I^2, τ^2, and a level higher than 0.7 ($I^2 > 0$) was considered an indicator of heterogeneity. To predict and investigate the effect of a variable on the obvious change in the results, the regression method was used, and the existence of possible publication bias was evaluated using a funnel plot.

Results

Study selection

Among the 3625 studies that were obtained by searching PubMed, Scholar, and Cochrane databases, 20 studies met eligibility criteria. A flow diagram of the study selection process is shown in Figure 1.

Study characteristics and quality assessment

The reviewed studies on both modalities were conducted in China in the years 2018–2022. Different CNNs included 2D–2.5D-3D UNet [14–26], modified UNet

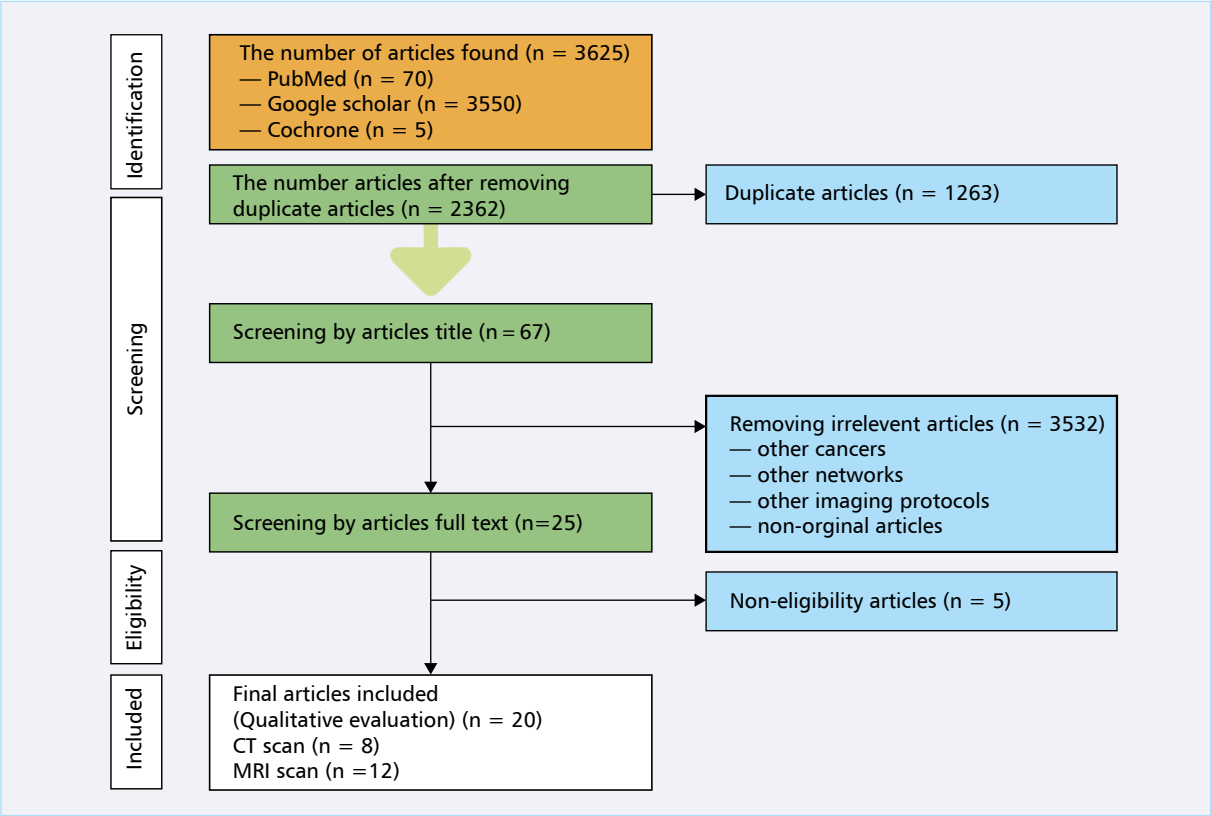

Figure 1. PRISMA flow diagram for study selection; CT — computed tomography; MRI — magnetic resonance imaging

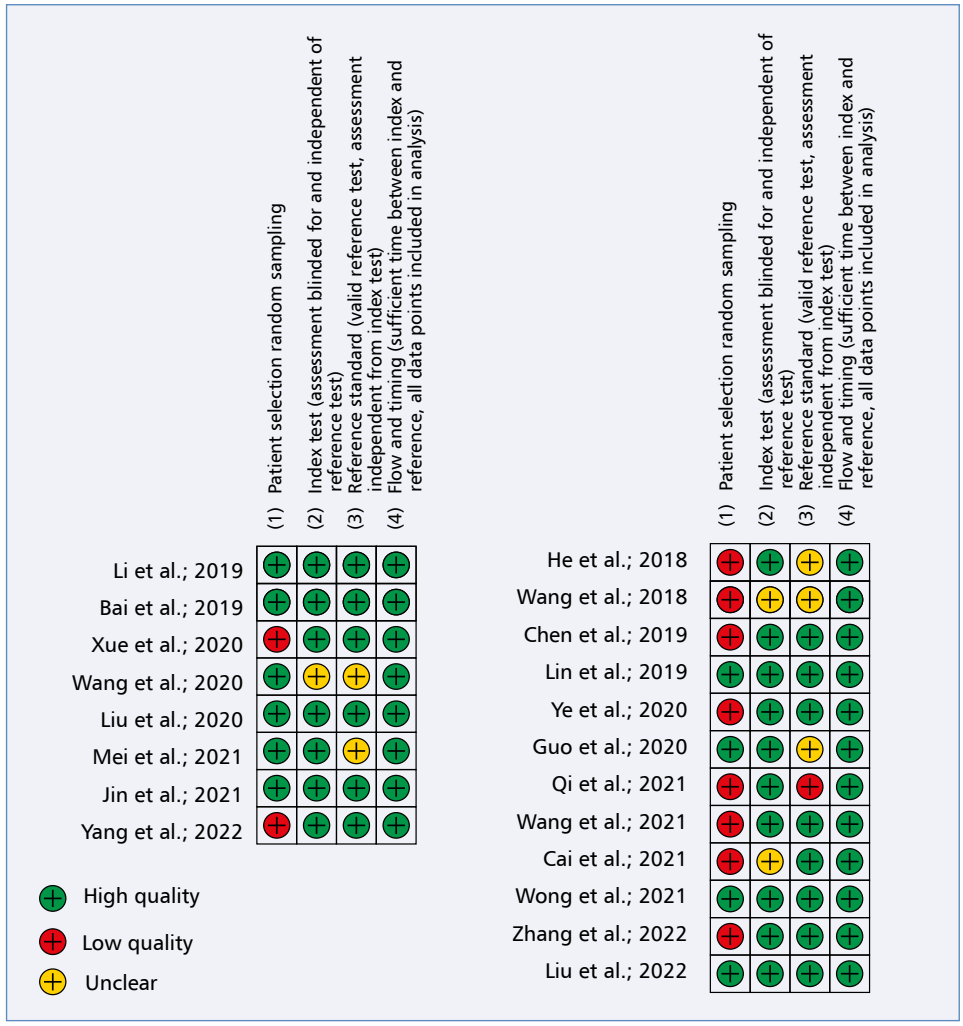

Figure 2. Quality assessment of the studies. Part (**A**) is related to the quality assessment of computed tomography (CT) studies and part (**B**) is related to magnetic resonance imaging (MRI) studies

[17], 3D Res-UNet [17, 27, 28], modified 3D Res-UNet [14, 17], a mix of 2D and 3D Res-UNet [29, 30], 3D VNet [15], 3D SI-UNet [18], 3D Nested UNet [14, 19, 31], 3D AttR2-UNet [14, 21, 31], 3D LW-UNet [32], and 3D DE-UNet [33].

Magnetic resonance imagining modality studies used hospital data [21–24, 26, 28, 29, 31–35], and CT studies often used the 2019 MICCAI StructSeg data [14, 15, 17, 19] and hospital data [16, 18, 27, 30]. Two articles were conference papers [22, 30], and one was from the arXiv database [26].

In studies where CT images were analyzed, types of considered images were included without contrast (CT), and with contrast (CE-CT). Also, MRI images were the collection of different sequences of T1-Weighted (T1W), T2-Weighted (T2W), T1-Contrast (T1C), and multi-sequence (MS). In most studies of both modalities, full details of the task were not given; however, the epoch size was between 40 and 600, batch size was 1–8, and the learning rate was 0.01–0.001.

Result of risk of bias evaluation

The quality of the articles in the CT and MRI modality groups was evaluated using the QUADAS-2 tool, as presented in Figure 2.

Result of meta-analysis

The descriptive characteristics and some performance results of NPC segmentation studies on CT scan MRI modalities are listed in Tables 1 [15–19, 27, 30, 36] and 2 [21–24, 26, 28, 29, 31–33, 35, 37], respectively.

NPC CT scan segmentation evaluation

Meta-analysis results of NPC segmentation studies of CT scan modality are presented as a forest plot in Figure 3. The pooled DSC was 0.67 (CI 95%, 0.62 to 0.72; $I^2 = 88.07\%$, $\tau^2 = 0.011$) (p = 0.00) for CT scan segmentation.

Table 1. Details of the studies on convolutional neural networks segmentation of computed tomography (CT) images

The first author (publication year and country)	Sample Size	Training [number]	External. validation	Testing N	Dataset	Tumor staging	Image type	Architecture	Epoch	Batch size	Learning Rate	DSC (mean)	HD (mean)	Processor specifications
Li et al. [16] (2019; China)	502	302	100	100	West China Hospital	T1–T4	CT	2D UNet	40	NM	0.01	74	32.10	Dual. Intel Xeon E5-2643 v4 (3.4 GHz) and dual. NVIDIA Tesla K40m graphics card
Xue et al. [18] (2020; China)	150	120	15	15	Hospital. of USTC	T1–T4	CT	3D UNet 3D SI-UNet	200	NM	0.0001	84 74	9.7 8.7	One Intel Xeon Processor E5-2695 CPU and an NVIDIA Tesla P100 GPU memory
Wang et al. [27] (2020; China)	205	NM	NM	NM	NM	T1–T4	CE-CT CT	3D Res –UNet	NM	1	0.03	73	4.96	One NVIDIA GeForce RTX 2080Ti with 11 GB GPU memory
Bai et al. [17] (2021; China)	60	50	No	10	StructSeg 2019 Challenge	T1–T4	CT	2D UNet 2D PUNet 3D UNet 3D PUNet 3D Res-UNet 3D PRes-UNet	NM	8	0.0005	57.01 60.59 59.71 59.8 58.97 62.88	8.12 6.75 14.52 11.94 7.41 6.07	One NVIDIA RTX 2080Ti GPU and 32 GB memory
Liu et al. [19] (2021; China)	140	60	No	40	2019 MICCAI StructSeg+ Sichuan Provincial. Cancer Hospital	T1–T4	CT	3D UNet 3D Nested-UNet	300	4	0.001	33.9 25.6	13.2 13.7	NM
Mei et al. [15] (2021; China)	50	40	No	10	2019 MICCAI StructSeg	T1–T4	CT	3D UNet 2.5 UNet 3D VNet	NM	16	0.0001	59.91 62.16 61.02	NM	Two NVIDIA GTX 1080 Ti GPU memory
Jin et al. [30] (2021; China)	90	63	18	9	Sichuan Cancer Hospital. & Institute	T1–T4	CT	3D PUNet 3D ResSE-UNet	200	8	0.0001	75 79	8.59 7.64	NM
Yang et al. [36] (2022; China)	257	205	No	52	2019 MICCAI StructSeg	T1–T4	CE-CT CT	3D UNet 3D PRes-UNet 3D AttR2-UNet 3D Nested-UNet	120	2	0.01	73.67 74.49 73.54 73.87	6.32 5.06 6.74 5.17	One NVIDIA GeForce RTX 2080Ti with 11 GB GPU memory

DSC — dice similarity coefficient; HD — Hausdorff distance; N — number; NM — not mentioned

Table 2. Details of the studies on convolutional neural networks segmentation of magnetic resonance imaging (MRI)

The first author (publication year and country)	Sample Size	Training [number]	External. validation	Testing N	Dataset	Tumor staging	MRI sequence	Archit-ecture	Epoch	Batch size	Learning Rate	DSC (mean)	HD (mean)	Processor specifications
He et al. [22] (2018; China)	19	18	No	1	NM	T1–T4	T1W	3D UNet	NM	NM	0.0001	74.8	NM	Ubuntu 14.04 with Tesla K80 at 3.6GHz and 11.18GB GPU memory
Wang et al. [23] (2018; China)	15	11	No	4	West China Hospital	T1–T4	T1W	3D UNet	NM	NM	NM	79	NM	NM
Chen et al. [26] (2019; China)	149	NM	NM	NM	Shandong Cancer Hospital	T1–T4	T1W T2W T1C MS	2D UNet 3D UNet	100	8	0.001	57.97 64.33	84.66 21.02	NVIDIA Titan Xp GPU with 12GB GPU memory
Lin et al. [28] (2019; China)	1021	715	103	203	Sun Yat-sen University Cancer Center	T1–T4	T1W T2W T1C	3D Res-UNet	NM	NM	NM	79	NM	NM
Ye et al. [33] (2020; China)	44	NM	NM	NM	Panyu Central. Hospital	T1–T4	T2W T1W	2D DE-UNet	200	1	0.0001	66.1	NM	NVIDIA Geforce GTX 1080 TI with 11 GB GPU memory
Guo et al. [24] (2020; China)	120	96	14	10	NM	T1–T4	MRI	3D UNet	500	1	0.0001	73.7	NM	NM
Wang et al. [29] (2021; China)	45	NM	NM	NM	West China Hospital	T1–T4	T1W T2W T1C MS	2D+3D Res-UNet	50	5	0.05	89.6	5.07	NM
Wong et al. [37] (2021; China)	201	136	No	65	NM	T1–T4	T2W T1W	2D UNet	75	4	0.005	71	NM	NM
Cai et al. [21] (2021; China)	251	241	No	10	Shanghai Cancer Center	T1–T4	T1W T2W T1C	3D UNet 3D AttR2-UNet	600	NM	0.0001	81.1 81.5	NM	Two NVIDIA Geforce GTX 1080 Ti GPU memory
Qi et al. [35] (2021; China)	130	NM	NM	NM	Shandong Cancer Hospital	T1–T4	T1W T2W T1C	3D UNet	NM	NM	NM	88.2	NM	NM
Zhang et al. [31] (2022; China)	93	73	10	10	NM	T1–T4	T1W T1C	2D AttR2-UNet 2D Nested-UNet 2D SE-UNet	100	3	0.001	73.8 79 78.7	NM	NM
Liu et al. [32] (2022; China)	92	72	10	10	NM	T1–T4	T1W T1C	2D LW-UNet	NM	1	NM	81.3	NM	NM

DSC — dice similarity coefficient; HD — Hausdorff distance; N — number; NM — not mentioned

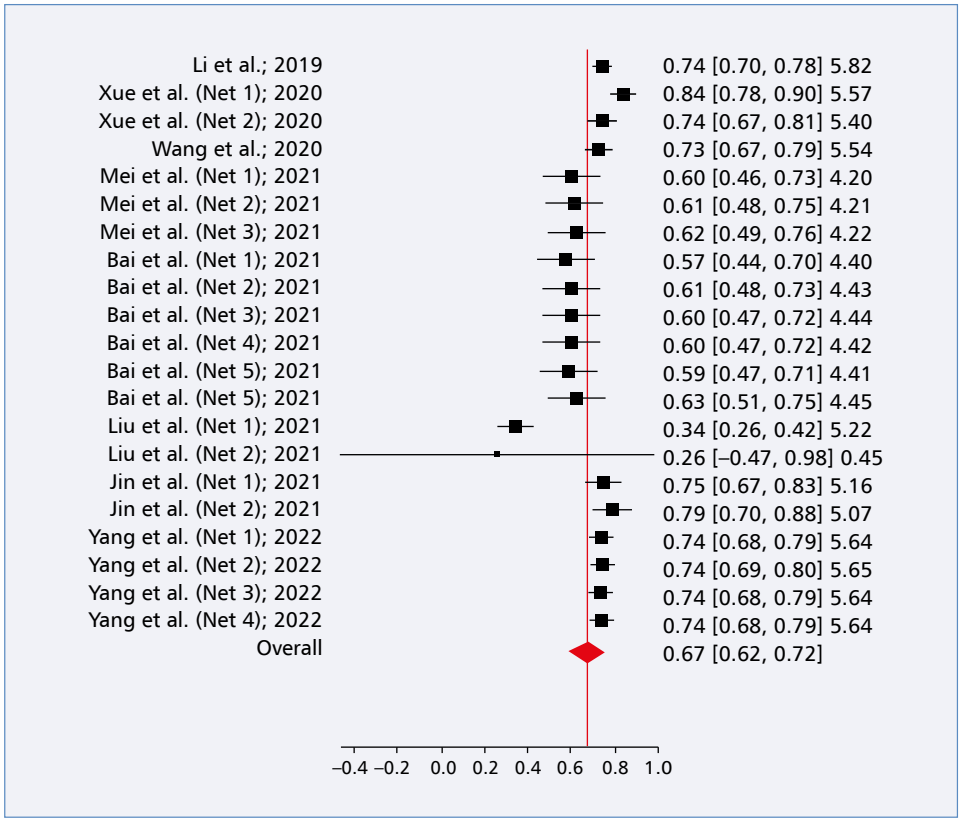

Figure 3. Forest plot of computed tomography (CT) modality segmentation studies. The pooled-dice similarity coefficient (DSC) value [calculated with the 95% confidence interval (CI) with range for each study is reported]. Studies are sorted by year, and all Network type values are indicated (Net: Network type).

NPC MRI scan segmentation

The meta-analyses result of NPC segmentation on the MRI modality showed that the pooled DSC was 0.76 (95% CI 0.72 to 0.80; I^2= 81.42%) (p = 0.01), and its forest plot is presented in Figure 4.

Subgroup analysis

The type of networks and their dimensions were evaluated in the following subgroups:

— CT scan: based on the number of network types, subgroups were divided into 12 categories. The number of six Network types was reported without a meta-analysis evaluation (including one study). The DSC index for 2.5D UNet, 2D UNet, 3D UNet, 2D P-UNet, 3D P-UNet, 3D AttR2-UNet, 3D Nested UNet, 3D Res-UNet, 3D P-Res-UNet, 3D ResSE-UNet, 3D SI-UNet, and 3D VNet was 0.62 (0.49 to 0.76), 0.67 (95% CI 0.50 to 0.83; I^2 = 84.52%), 0.62 (0.95% CI 0.46 to 0.79; I^2 = 95.64%), 0.61 (95% CI 0.48 to 0.73), 0.68 (0.95% CI 0.53 to 0.83; I^2 = 74.68%), 0.74 (0.68 to 0.79), 0.64 (0.95% CI 0.25 to 1.02; I^2 = 41.30%), 0.67 (95% CI 0.53 to 0.81; I^2 =74.63%), 0.70 (95% CI 0.59 to 0.81; I^2 = 74.68%), 0.79 (0.70 to 0.88), 0.74 (0.67 to 0.81), and 0.61(0.48 to 0.75), respectively.

Furthermore, the pooled DSC values for Network dimensions including 2D, 2.5D, and 3D were 0.65 (95% CI 0.54 to 0.76; I^2 = 75.96%), 0.62 (0.49 to 0.76), and 0.68 (95% CI 0.62 to 0.74; I^2 = 89.20%), respectively;

— MRI scan: in this modality, network types were divided into ten categories (10 network types) which nine categories were reported without a meta-analysis evaluation (including one study). The DSC index on 2D UNet, 3D UNet, 2D AttR2-UNet, 3D AttR2-UNet, 2D Nested-UNet, 2D SE-UNet, 2D+3D Res-UNet, 3D Res-UNet, 3D DE-UNet, and 3D LW-UNet was 0.64 (0.57 to 0.72), 0.76 (95% CI 0.68 to 0.84; I^2 = 87.20%), 0.78 (0.70 to0.87), 0.81 (0.77 to 0.86), 0.79 (0.71 to 0.87), 0.79 (0.70 to 0.87), 0.79 (0.67 to 0.91), 0.79 (0.77 to 0.81), 0.66 (0.52 to 0.80), and 0.81 (0.73 to 0.89), respectively.

The pooled DSC analysis for the subgroups of Network Dimensions including 2D, 2D + 3D, and

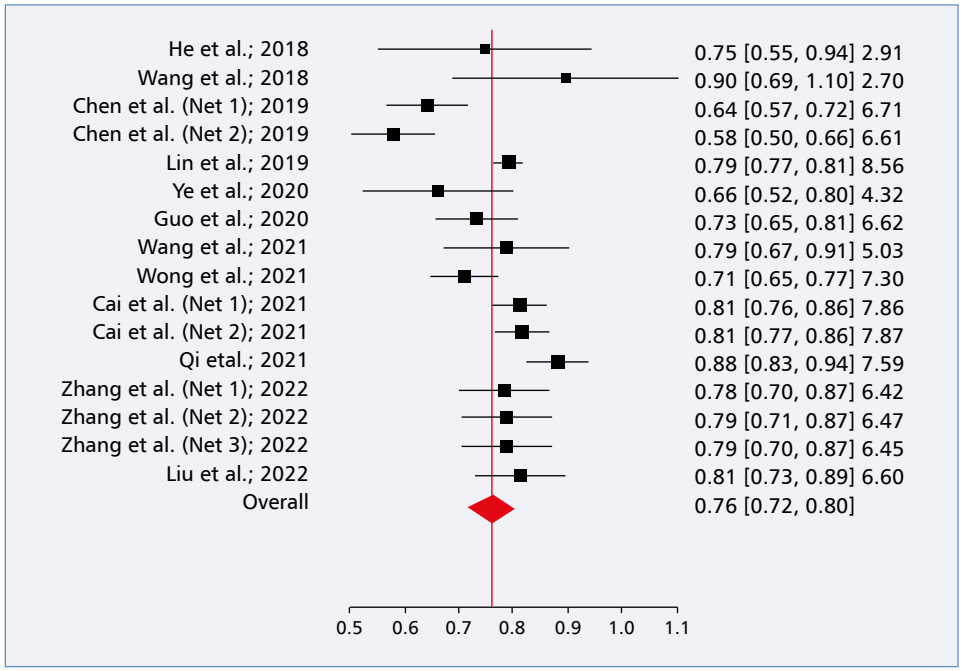

Figure 4. Forest plot of magnetic resonance imagining modality segmentation studies. The pooled dice similarity coefficient (DSC) value (calculated with a 95% confidence interval) with range for each study is reported. Studies are sorted by year, and all Network type values are indicated (Net: Network type)

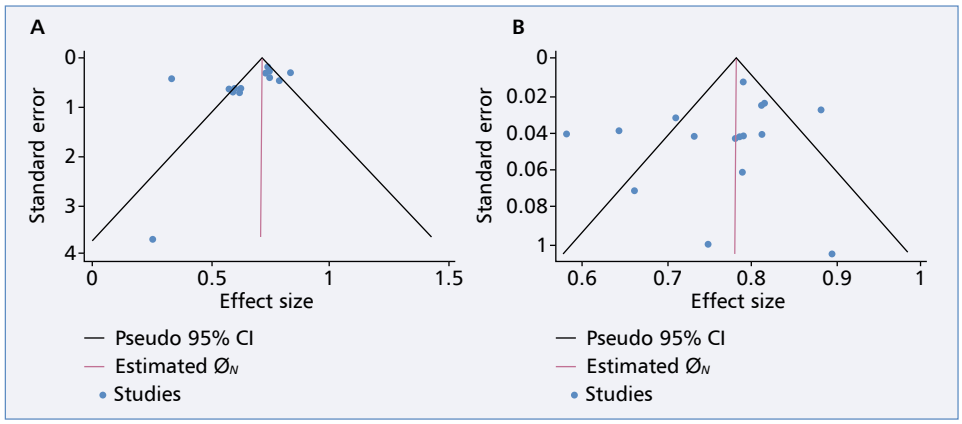

Figure 5. Funnel plot on computed tomography (**A**) and magnetic resonance imagining (**B**) modalities for evaluation of publication bias. The dice similarity coefficient (DSC) index was calculated as the effect size [95% confidence interval (CI)]

3D achieved 0.75 (95% CI 0.68 to 0.82; I^2 = 67.92%), 0.79 (0.67 to 0.91) and 0.77 (95% CI 0.71 to 0.82; I^2 = 86.87%), respectively.

Evaluation of possible causes of heterogeneity

In regression evaluation, coefficients of variables caused heterogeneity for CT studies based on the training number, external validation, and epoch number, which were (0.00073, p = 0.014), (–0.13648, p = 0.008), (–0.00109, p = 0.041), respectively, and for MRI studies based on batch size (–0.02199, p = 0.010).

Publication bias

We used a funnel plot to evaluate the publication bias in the studies that evaluated CNNs in image segmentation of both CT and MRI modalities (Fig. 5).

Discussion

The automatic system for the segmentation of heterogeneous NPC tumors is very valuable because it reduces the workload and speeds up diagnosis and treatment. It is necessary to know how successful deep learning networks have been so far, thus the results of this study will be very helpful in decision-making. The DSC index value was selected as the effect size parameter, and a meta-analysis was performed along with SE.

Convolutional neural networks as a subgroup of deep learning were initially tested as 2D in 2018 for CT scans and then in 2019 for MRI. After introducing innovative 3D networks, more studies have been devoted to these networks (Tab. 1, 2). However, 3D networks require a higher volume of calculations and more complex hardware for processing [39]. Recently, the expansion of network layers to improve network performance has been considered. AttR2-UNet and Nested-UNet are examples of such networks [40, 41].

Overall, considering the classification of the DSC index into three levels: good ($0.8 \leq DSC \leq 1$), medium ($0.6 \leq DSC < 0.8$), and poor ($0 \leq DSC < 0.6$)] [38], both MRI image (0.76) and CT image (0.67) segmentation networks achieved medium results, while MRI studies obtained better results than NPC CT image segmentation studies. However, due to the different characteristics of the networks and the heterogeneous distribution of the studies in the two categories, it is not possible to draw definitive conclusions in this regard. The included studies were performed in the past five years, which indicates that this field is very new and will gain more success with further investigations.

In addition, the pooled DSC of both CT and MRI modalities for different dimensions of networks (2D–2.5D–3D), reported almost similar values (~0.02 difference). In detail, the highest value of the DSC index for CT and MRI modalities was observed in 3D-ResSe-UNet (0.79), AttR2-UNet, and LW-UNet (0.81), respectively.

The limitation of analysis based on the results of the evaluated networks was the difference in details and performance of networks, such as the used loss function and epoch number even in similar networks. In addition, there was heterogeneity regarding the training of the networks using CT (with and without contrast) and MRI in different sequences. Due to the dependence of deep learning on the dataset, the heterogeneous distribution of patients, and the small number of patients in some geographical areas, may have affected the results of studies. Almost half of the CT scan segmentation studies used the same dataset presented in the 2019 MICCAI StructSeg, which reduces the impact of data type on the results and makes their comparison more valid. What is characteristic of these studies is that external validation was not performed in more than half of both modalities. Overall, we were able to reduce the heterogeneity analysis of the dimensions and type of the network subgroups.

Notably, all eligible studies were conducted in China, and on the other hand, the highest prevalence of NPC cancer was reported in China (~80%) [42]. Probably, the number of appropriate datasets, compared to other countries, and prioritizing this cancer in research facilitated the implementation of studies.

Since it is not easy to determine the margin of small tumors in magnetic resonance (MR) images, it may affect the ability of the network [43]. Therefore, more empowerment of networks to segmentation of MR images should be given more attention in future studies. Due to the impossibility of using contrast agents for patients with renal failure and the possibility of long-term complications [44], using images with contrast is likely to be used less in the future, thus it is better to enable networks to use non-contrast images.

Conclusions

The medium capability level of CNNs was observed in both CT and MRI modalities, while this capability was better in MRI segmentation. By improving CNNs, their clinical application can be made more practical.

Article Information and Declarations

Ethics statement

This article does not involve any studies with human participants or animals performed by any of the authors.

Author contributions

I.A. and M.Z. were equally involved in the design, literature review, and analysis of the study.

Funding

None.

Acknowledgments

None.

Conflict of interest

The authors declare that they have no conflict of interest.

Supplementary material

Supplementary Table S1.

References

1. Chang ET, Ye W, Zeng YX, et al. The Evolving Epidemiology of Nasopharyngeal Carcinoma. Cancer Epidemiol Biomarkers Prev. 2021; 30(6): 1035–1047, doi: 10.1158/1055-9965.EPI-20-1702, indexed in Pubmed: 33849968.
2. Guo R, Mao YP, Tang LL, et al. The evolution of nasopharyngeal carcinoma staging. Br J Radiol. 2019; 92(1102): 20190244, doi: 10.1259/bjr.20190244, indexed in Pubmed: 31298937.
3. Blanchard P, Biau J, Huguet F, et al. Radiotherapy for nasopharyngeal cancer. Cancer Radiother. 2022; 26(1-2): 168–173, doi: 10.1016/j.canrad.2021.08.009, indexed in Pubmed: 34953699.
4. Minniti G, Goldsmith C, Brada M. Radiotherapy. Handb Clin Neurol. 2012; 104: 215–228, doi: 10.1016/B978-0-444-52138-5.00016-5, indexed in Pubmed: 22230446.
5. King AD. MR Imaging of Nasopharyngeal Carcinoma. Magn Reson Imaging Clin N Am. 2022; 30(1): 19–33, doi: 10.1016/j.mric.2021.06.015, indexed in Pubmed: 34802578.
6. Choopani MR, Abedi I, Dalvand F. Quality Assessment of Computed Tomography Images using a Channelized Hoteling Observer: Optimization of Protocols in Clinical Practice. Adv Biomed Res. 2023; 12: 8, doi: 10.4103/abr.abr_353_21, indexed in Pubmed: 36926443.
7. Patel PR, De Jesus O. CT Scan. In: De Je. ed. StatPearls. StatPearls Publishing LLC, Treasure Island (FL) 2022.
8. Schaue D, McBride WH. Opportunities and challenges of radiotherapy for treating cancer. Nat Rev Clin Oncol. 2015; 12(9): 527–540, doi: 10.1038/nrclinonc.2015.120, indexed in Pubmed: 26122185.
9. Claude L, Jouglar E, Duverge L, et al. Update in pediatric nasopharyngeal undifferentiated carcinoma. Br J Radiol. 2019; 92(1102): 20190107, doi: 10.1259/bjr.20190107, indexed in Pubmed: 31322911.
10. Wang C, Zhu X, Hong JC, et al. Artificial Intelligence in Radiotherapy Treatment Planning: Present and Future. Technol Cancer Res Treat. 2019; 18: 1533033819873922, doi: 10.1177/1533033819873922, indexed in Pubmed: 31495281.
11. Shen G, Jin X, Sun C, et al. Artificial Intelligence Radiotherapy Planning: Automatic Segmentation of Human Organs in CT Images Based on a Modified Convolutional Neural Network. Front Public Health. 2022; 10: 813135, doi: 10.3389/fpubh.2022.813135, indexed in Pubmed: 35493368.
12. Liu Z, Liu F, Chen W, et al. Automatic Segmentation of Clinical Target Volume and Organs-at-Risk for Breast Conservative Radiotherapy Using a Convolutional Neural Network. Cancer Manag Res. 2021; 13: 8209–8217, doi: 10.2147/CMAR.S330249, indexed in Pubmed: 34754241.
13. Liang S, Tang F, Huang X, et al. Deep-learning-based detection and segmentation of organs at risk in nasopharyngeal carcinoma computed tomographic images for radiotherapy planning. Eur Radiol. 2019; 29(4): 1961–1967, doi: 10.1007/s00330-018-5748-9, indexed in Pubmed: 30302589.
14. Yang G, Dai Z, Zhang Y, et al. Multiscale Local Enhancement Deep Convolutional Networks for the Automated 3D Segmentation of Gross Tumor Volumes in Nasopharyngeal Carcinoma: A Multi-Institutional Dataset Study. Front Oncol. 2022; 12: 827991, doi: 10.3389/fonc.2022.827991, indexed in Pubmed: 35387126.
15. Mei H, Lei W, Gu R, et al. Automatic segmentation of gross target volume of nasopharynx cancer using ensemble of multiscale deep neural networks with spatial attention. Neurocomputing. 2021; 438: 211–222, doi: 10.1016/j.neucom.2020.06.146.
16. Li S, Xiao J, He L, et al. The Tumor Target Segmentation of Nasopharyngeal Cancer in CT Images Based on Deep Learning Methods. Technol Cancer Res Treat. 2019; 18: 1533033819884561, doi: 10.1177/1533033819884561, indexed in Pubmed: 31736433.
17. Bai X, Hu Y, Gong G, et al. A deep learning approach to segmentation of nasopharyngeal carcinoma using computed tomography. Biomedical Signal Processing and Control. 2021; 64: 102246, doi: 10.1016/j.bspc.2020.102246.
18. Xue X, Qin N, Hao X, et al. Sequential and Iterative Auto-Segmentation of High-Risk Clinical Target Volume for Radiotherapy of Nasopharyngeal Carcinoma in Planning CT Images. Front Oncol. 2020; 10: 1134, doi: 10.3389/fonc.2020.01134, indexed in Pubmed: 32793483.
19. Liu Y, Yuan X, Jiang X, et al. Dilated Adversarial U-Net Network for automatic gross tumor volume segmentation of nasopharyngeal carcinoma. Applied Soft Computing. 2021; 111: 107722, doi: 10.1016/j.asoc.2021.107722.
20. Wong L, Ai Qy, Mo F, et al. Non contrast-enhanced imaging as a replacement for contrast-enhanced imaging for MRI automatic delineation of nasopharyngeal carcinoma. medRxiv. 2020, doi: 10.1101/2020.07.09.20148817.
21. Cai M, Wang J, Yang Q, et al. Combining Images and T-Staging Information to Improve the Automatic Segmentation of Nasopharyngeal Carcinoma Tumors in MR Images. IEEE Access. 2021; 9: 21323–21331, doi: 10.1109/access.2021.3056130.
22. He Yu, Yu Xi, Liu C, et al. A 3D Dual Path U-Net of Cancer Segmentation Based on MRI. 2018 IEEE 3rd International Conference on Image, Vision and Computing (ICIVC). 2018, doi: 10.1109/icivc.2018.8492781.
23. Wang Y, Zu C, Hu G, et al. Automatic Tumor Segmentation with Deep Convolutional Neural Networks for Radiotherapy Applications. Neural Processing Letters. 2018; 48(3): 1323–1334, doi: 10.1007/s11063-017-9759-3.
24. Guo F, Shi C, Li X, et al. Image segmentation of nasopharyngeal carcinoma using 3D CNN with long-range skip connection and multi-scale feature pyramid. Soft Computing. 2020; 24(16): 12671–12680, doi: 10.1007/s00500-020-04708-y.
25. Qi Y, Yin Y, Li T, et al. A Computer Aided System for Nasopharyngeal Carcinoma Segmentation and Visualization Based on CT Images. 2018 2nd International Conference on Robotics and Automation Sciences (ICRAS). 2018, doi: 10.1109/icras.2018.8443238.
26. Chen H, Qi Y, Yin Y, et al. MMFNet: A multi-modality MRI fusion network for segmentation of nasopharyngeal carcinoma. Neurocomputing. 2020; 394: 27–40, doi: 10.1016/j.neucom.2020.02.002.
27. Wang X, Yang G, Zhang Y, et al. Automated delineation of nasopharynx gross tumor volume for nasopharyngeal carcinoma by plain CT combining contrast-enhanced CT using deep learning. Journal of Radiation Research and Applied Sciences. 2020; 13(1): 568–577, doi: 10.1080/16878507.2020.1795565.
28. Lin Li, Dou Qi, Jin YM, et al. Deep Learning for Automated Contouring of Primary Tumor Volumes by MRI for Nasopharyngeal Carcinoma. Radiology. 2019; 291(3): 677–686, doi: 10.1148/radiol.2019182012, indexed in Pubmed: 30912722.
29. Wang D, Gong Z, Zhang Y, et al. Convolutional Neural Network Intelligent Segmentation Algorithm-Based Magnetic Resonance Imaging in Diagnosis of Nasopharyngeal Carcinoma Foci. Contrast Media Mol Imaging. 2021; 2021: 2033806, doi: 10.1155/2021/2033806, indexed in Pubmed: 34456649.
30. Jin Z, Li X, Shen L, et al. Automatic Primary Gross Tumor Volume Segmentation for Nasopharyngeal Carcinoma using ResSE-UNet. 2020 IEEE 33rd International Symposium on Computer-Based Medical Systems (CBMS). 2020, doi: 10.1109/cbms49503.2020.00116.
31. Zhang J, Gu L, Han G, et al. AttR2U-Net: A Fully Automated Model for MRI Nasopharyngeal Carcinoma Segmentation Based on Spatial Attention and Residual Recurrent Convolution. Front Oncol. 2021; 11: 816672, doi: 10.3389/fonc.2021.816672, indexed in Pubmed: 35155206.
32. Liu Yi, Han G, Liu X. Lightweight Compound Scaling Network for Nasopharyngeal Carcinoma Segmentation from MR Images. Sensors (Basel). 2022; 22(15), doi: 10.3390/s22155875, indexed in Pubmed: 35957432.
33. Ye Y, Cai Z, Huang B, et al. Fully-Automated Segmentation of Nasopharyngeal Carcinoma on Dual-Sequence MRI Using Convolutional Neural Networks. Front Oncol. 2020; 10: 166, doi: 10.3389/fonc.2020.00166, indexed in Pubmed: 32154168.
34. Wong LM, Ai QiY, Mo FKF, et al. Convolutional neural network in nasopharyngeal carcinoma: how good is automatic delineation for primary tumor on a non-contrast-enhanced fat-suppressed T2-weighted MRI? Jpn J Radiol. 2021; 39(6): 571–579, doi: 10.1007/s11604-021-01092-x, indexed in Pubmed: 33544302.
35. Qi Y, Li J, Chen H, et al. Computer-aided diagnosis and regional segmentation of nasopharyngeal carcinoma based on multi-modality medical images. Int J Comput Assist Radiol Surg. 2021; 16(6): 871–882, doi: 10.1007/s11548-021-02351-y, indexed in Pubmed: 33782844.
36. Yang B, Chen X, Li J, et al. A feasible method to evaluate deformable image registration with deep learning-based segmentation. Phys Med. 2022; 95: 50–56, doi: 10.1016/j.ejmp.2022.01.006, indexed in Pubmed: 35091332.
37. Wong ML. Applications of Deep Learning in MRI of Nasopharyngeal Carcinoma. The Chinese University of Hong Kong, Hong Kong 2021.
38. Velker VM, Rodrigues GB, Dinniwell R, et al. Creation of RTOG compliant patient CT-atlases for automated atlas based contouring of local regional breast and high-risk prostate cancers. Radiat Oncol. 2013; 8: 188, doi: 10.1186/1748-717X-8-188, indexed in Pubmed: 23885662.
39. Nguyen D, Long T, Jia X, et al. A feasibility study for predicting optimal radiation therapy dose distributions of prostate cancer patients from

patient anatomy using deep learning. Sci Rep. 2019; 9(1): 1076, doi: 10.1038/s41598-018-37741-x, indexed in Pubmed: 30705354.
40. Zhu N, Liu C, Forsyth B, et al. Segmentation with Residual Attention U-Net and an Edge-Enhancement Approach Preserves Cell Shape Features. Annu Int Conf IEEE Eng Med Biol Soc. 2022; 2022: 2115–2118, doi: 10.1109/EMBC48229.2022.9871026, indexed in Pubmed: 36085725.
41. Kundu S, Karale V, Ghorai G, et al. Nested U-Net for Segmentation of Red Lesions in Retinal Fundus Images and Sub-image Classification for Removal of False Positives. J Digit Imaging. 2022; 35(5): 1111–1119, doi: 10.1007/s10278-022-00629-4, indexed in Pubmed: 35474556.
42. Chen W, Zheng R, Baade PD, et al. Cancer statistics in China, 2015. CA Cancer J Clin. 2016; 66(2): 115–132, doi: 10.3322/caac.21338, indexed in Pubmed: 26808342.
43. Spicer GJ, Kazim M, Glass LR, et al. Accuracy of MRI in defining tumor-free margin in optic nerve glioma surgery. Ophthalmic Plast Reconstr Surg. 2013; 29(4): 277–280, doi: 10.1097/IOP.0b013e318291658e, indexed in Pubmed: 23715516.
44. Pasquini L, Napolitano A, Visconti E, et al. Gadolinium-Based Contrast Agent-Related Toxicities. CNS Drugs. 2018; 32(3): 229–240, doi: 10.1007/s40263-018-0500-1, indexed in Pubmed: 29508245.

Supplementary material

Table S1. PRISIMA 2020 checklist (based on: Page MJ, McKenzie JE, Bossuyt PM, et al. The PRISMA 2020 statement: an updated guideline for reporting systematic reviews. BMJ. 2021; 372: n71)

Section and topic	Item #	Checklist item	Location where item is reported
TITLE			
Title	1	Identify the report as a systematic review	Page 1
ABSTRACT			
Abstract	2	See the PRISMA 2020 for Abstracts checklist	Page 2, P1
INTRODUCTION			
Rationale	3	Describe the rationale for the review in the context of existing knowledge	Page 3, P4, 5, 6
Objectives	4	Provide an explicit statement of the objective(s) or question(s) the review addresses	Page 3, P7
METHODS			
Eligibility criteria	5	Specify the inclusion and exclusion criteria for the review and how studies were grouped for the syntheses	Page 4, P4
Information sources	6	Specify all databases, registers, websites, organizations, reference lists and other sources searched or consulted to identify studies. Specify the date when each source was last searched or consulted	Page 4, P2
Search strategy	7	Present the full search strategies for all databases, registers and websites, including any filters and limits used	Page 4, P1
Selection process	8	Specify the methods used to decide whether a study met the inclusion criteria of the review, including how many reviewers screened each record and each report retrieved, whether they worked independently, and if applicable, details of automation tools used in the process	N/R
Data collection process	9	Specify the methods used to collect data from reports, including how many reviewers collected data from each report, whether they worked independently, any processes for obtaining or confirming data from study investigators, and if applicable, details of automation tools used in the process	Page 4, P1
Data items	10a	List and define all outcomes for which data were sought. Specify whether all results that were compatible with each outcome domain in each study were sought (e.g. for all measures, time points, analyses), and if not, the methods used to decide which results to collect	Page 4, P6
	10b	List and define all other variables for which data were sought (e.g. participant and intervention characteristics, funding sources). Describe any assumptions made about any missing or unclear information	Page 4, P6
Study risk of bias assessment	11	Specify the methods used to assess the risk of bias in the included studies, including details of the tool(s) used, how many reviewers assessed each study and whether they worked independently, and if applicable, details of automation tools used in the process	Page 4, P5
Effect measures	12	Specify for each outcome the effect measure(s) (e.g. risk ratio, mean difference) used in the synthesis or presentation of results	Page 4, P6
Synthesis methods	13a	Describe the processes used to decide which studies were eligible for each synthesis (e.g. tabulating the study intervention characteristics and comparing against the planned groups for each synthesis (item #5)	Page 5, P1
	13b	Describe any methods required to prepare the data for presentation or synthesis, such as handling of missing summary statistics, or data conversions	Page 5, P1
	13c	Describe any methods used to tabulate or visually display results of individual studies and syntheses	Page 5, P1
	13d	Describe any methods used to synthesize results and provide a rationale for the choice(s). If meta-analysis was performed, describe the model(s), method(s) to identify the presence and extent of statistical heterogeneity, and software package(s) used	Page 5, P1
	13e	Describe any methods used to explore possible causes of heterogeneity among study results (e.g. subgroup analysis, meta-regression)	Page 5, P1
	13f	Describe any sensitivity analyses conducted to assess the robustness of the synthesized results	Page 5, P1

→

Table S1 cont. PRISIMA 2020 checklist (based on: Page MJ, McKenzie JE, Bossuyt PM, et al. The PRISMA 2020 statement: an updated guideline for reporting systematic reviews. BMJ. 2021; 372: n71)

Section and Topic	Item #	Checklist item	Location where item is reported
Reporting bias assessment	14	Describe any methods used to assess risk of bias due to missing results in a synthesis (arising from reporting biases)	Page 4, P5
Certainty assessment	15	Describe any methods used to assess certainty (or confidence) in the body of evidence for an outcome	Page 5, P1
RESULTS			
Study selection	16a	Describe the results of the search and selection process, from the number of records identified in the search to the number of studies included in the review, ideally using a flow diagram	Page 6, P3
	16b	Cite studies that might appear to meet the inclusion criteria, but which were excluded, and explain why they were excluded	Page 6, P4, Fig 1
Study characteristics	17	Cite each included study and present its characteristics	Page 6, P2-6
Risk of bias in studies	18	Present assessments of risk of bias for each included study	Page 6, P1, Fig 2
Results of individual studies	19	For all outcomes, present, for each study: (a) summary statistics for each group (where appropriate) and (b) an effect estimate and its precision (e.g. confidence/credible interval), ideally using structured tables or plots	Page 10–13
Results of syntheses	20a	For each synthesis, briefly summarize the characteristics and risk of bias among contributing studies	Page 6, P1
	20b	Present results of all statistical syntheses conducted. If meta-analysis was done, present for each the summary estimate and its precision (e.g. confidence/credible interval) and measures of statistical heterogeneity. If comparing groups, describe the direction of the effect	Page 10–13
	20c	Present results of all investigations of possible causes of heterogeneity among study results	Page 10–13
	20d	Present results of all sensitivity analyses conducted to assess the robustness of the synthesized results	Page 10–13
Reporting biases	21	Present assessments of risk of bias due to missing results (arising from reporting biases) for each synthesis assessed	Page 6, 14
Certainty of evidence	22	Present assessments of certainty (or confidence) in the body of evidence for each outcome assessed	Page 10–13
DISCUSSION			
Discussion	23a	Provide a general interpretation of the results in the context of other evidence	Page 15, P6
	23b	Discuss any limitations of the evidence included in the review	Page 16, P5
	23c	Discuss any limitations of the review processes used	Page 16, P5
	23d	Discuss implications of the results for practice, policy, and future research	Page 16, P3
OTHER INFORMATION			
Registration and protocol	24a	Provide registration information for the review, including register name and registration number, or state that the review was not registered	Page 3, P8
	24b	Indicate where the review protocol can be accessed, or state that a protocol was not prepared	Page 3, P8
	24c	Describe and explain any amendments to information provided at registration or in the protocol	Page 3, P8
Support	25	Describe sources of financial or non-financial support for the review, and the role of the funders or sponsors in the review	Page 16, P6
Competing interests	26	Declare any competing interests of review authors	Page 16, P7
Availability of data, code, and other materials	27	Report which of the following are publicly available and where they can be found: template data collection forms; data extracted from included studies; data used for all analyses; analytic code; any other materials used in the review	N/R

Emilia Babula[1, 2*], Aleksandra Sikora[1, 2*], Paweł Sobczuk[1], Piotr Rutkowski[1]

[1]Department of Soft Tissue/Bone Sarcoma and Melanoma, Maria Skłodowska-Curie National Research Institute of Oncology, Warsaw, Poland
[2]Faculty of Medicine, Medical University of Warsaw, Poland
*Contributed equally

Ripretinib in the treatment of patients with advanced gastrointestinal stromal tumors (GIST)

Address for correspondence:
Paweł Sobczuk, MD PhD
Department of Soft Tissue/Bone Sarcoma and Melanoma, Maria Skłodowska-Curie National Research Institute of Oncology
ul. Roentgena 5, 02–781 Warsaw, Poland
phone: +48 225462031
e-mail: pawel.sobczuk@nio.gov.pl

Oncology in Clinical Practice
DOI: 10.5603/ocp.96771
Copyright © 2024 Via Medica
ISSN 2450–1654
e-ISSN 2450–6478

ABSTRACT

Gastrointestinal stromal tumors (GISTs) are relatively rare in the population (0.4 to 2 cases per 100 000 per year) and account for approximately 1–2% of gastrointestinal cancers. According to the latest 2020 World Health Organization (WHO) classification of sarcomas, all GISTs are malignant, regardless of their size or mitotic index. In the systemic treatment of GIST, KIT tyrosine kinase receptor and platelet-derived growth factor receptor (PDGFRA) inhibitors, such as imatinib, sunitinib, or regorafenib, are used. The effectiveness of imatinib is significantly reduced in the case of secondary mutations in the *KIT* gene. The latest drug from the group of KIT inhibitors, ripretinib, was the first to show efficacy against most mutations associated with resistance, as well as in wild-type GIST, in which mutations in KIT and PDGFRA are not found. Analysis of the INVICTUS study showed a beneficial effect of ripretinib at the recommended dose of 150 mg/day on progression-free survival (PFS) in patients with advanced or metastatic GIST previously treated with at least three other inhibitors. However, the preliminary results of the phase III INTRIGUE study did not show an improvement in PFS in patients receiving ripretinib compared to sunitinib in the second-line therapy of GIST patients. Ripretinib has a favorable and acceptable safety profile and is recommended for treating patients with advanced GIST in the fourth line of treatment. In this article, we summarize the most essential data on the efficacy and safety of ripretinib in treating GIST patients and the recommendations for its use.
Keywords: GIST, KIT, PDGFRA, ripretinib, tyrosine kinase inhibitor

Oncol Clin Pract 2024; 20, 1:40–51

Introduction

Gastrointestinal stromal tumors (GISTs) are among the most common mesenchymal tumors developing in the digestive tract [1, 2]. Compared to other tumors in this localization, they are very rare. The incidence is estimated as from 0.4 to 2 cases per 100 000 people per year, 1–2% of all gastrointestinal cancers [3]. They can develop at any age, with the peak incidence at 65 years of age and similar frequency in women and men [4, 5]. The most common primary location of GIST is the stomach (60–65%) and the small intestine (20–25%); to a lesser extent, the large intestine (6%), esophagus (0.7%), and other locations (5.5%) [4, 6, 7]. Symptoms of gastrointestinal stromal tumors are not specific and depend on the tumor's location, stage of advancement, and its size. The most common symptoms are chronic bleeding from the gastrointestinal tract, anemia, bloating, abdominal pain, and an early feeling of satiety [8].

Gastrointestinal stromal tumors is most often caused by an activating somatic mutation in the genes of the tyrosine kinase receptor (*KIT*) (Tab. 1) or the

Received: 31.07.2023 Accepted: 20.09.2023 Early publication date: 20.10.2023

This article is available in open access under Creative Common Attribution-Non-Commercial-No Derivatives 4.0 International (CC BY-NC-ND 4.0) license, allowing to download articles and share them with others as long as they credit the authors and the publisher, but without permission to change them in any way or use them commercially.

Table 1. Molecular classification of gastrointestinal stromal tumors (GISTs)

Mutation	Estimated frequency [%]	Most common location	Characteristics
***KIT*-mutated (approximately 80%)**			
Exon 9 (or exon 8)	5–10	Small intestine, stomach, colon, rectum	Lower sensitivity to imatinib at a dose of 400 mg/d. Sensitivity to sunitinib, regorafenib, avapritinib, ripretinib
Exon 11 (deletions, including del. 557-558, missense mutations, insertions, other)	60–70	Stomach, small intestine, colon, rectum	Responds best to imatinib; sensitive to sunitinib, regorafenib, avapritinib, ripretinib. Present in familial GISTs
Exon 13 (K542E)	< 1		Clinical response to imatinib only in some patients. Less sensitive to sunitinib. Sensitive to regorafenib, avapritinib, ripretinib. Present in familial GISTs
Exon 17 (D820Y, N822K, Y823D)	1		Not sensitive to imatinib. Sensitive to avapritinib and ripretinib, some to sunitinib and regorafenib. Present in familial GISTs
***PDGFRA*-mutated (approximately 15%)**			
Exon 12 (e.g. V561D)	< 1	Stomach	Observed response to imatinib except — D842V mutation (insensitive). D842V mutation highly sensitive to avapritinib
Exon 14 (N659K)	< 1		
Exon 18 (e.g. D842V)	10–15		
***KIT* and *PDGFRA* wild-type, *SDH*-competent**			
NF1 mutation	1–2	Small intestine	Indolent course, associated with type I neurofibromatosis. Possibly insensitive to available KIT inhibitors
BRAF mutation	< 1	Small intestine, stomach	Possibly insensitive to available KIT inhibitors. Ripretinib inhibits BRAF *in vitro*
HRAS, *NRAS,* or *KRAS* mutation	Very rare	Unknown	Insensitive to KIT inhibitors
Translocations (fusions of *FGFR1, NTRK3 RTK,* or other)	Very rare	Small intestine, colon, rectum	Insensitive to KIT inhibitors. Sensitive to NTRK inhibitors (for *NTRK* rearrangements)
***KIT* and *PDGFRA* wild-type, *SDH*-deficient**			
SDHA, SDHB, SDHC, or *SDHD* mutation (including Carney--Stratakis Syndrome)	Approximately 3	Stomach, small intesitne (less often)	Epithelial cells. Common in pediatric and young adult GISTs. Often metastases to lymph nodes, indolent course. Insensitive to imatinib, better response to sunitinib
Lack of SDHB expression (including Carney's triad)	< 1	Stomach	

platelet-derived growth factor alpha (*PDGFRA*) genes, which leads to disruption of the process of replacing old cells with new ones and causes their excessive proliferation and formation of a neoplastic lesion [9]. *KIT, PDGFRA*, and *PDGFRB* belong to the same family of type III tyrosine kinase receptors, and their mutations are mutually exclusive [7, 10, 11]. Both KIT and PDGFRA are structurally and functionally homologous. Both consist of an extracellular domain, a transmembrane domain, a transmembrane fragment, and a cytoplasmic kinase domain. For KIT, the stem cell factor (SCF) is the activating ligand, while for PDGFRA, it is the platelet-derived growth factor (PDGFA) [2]. Gastrointestinal stromal tumors probably originate from precursors of Cajal cells that express KIT (CD117) and are located in the muscular layer of the gastrointestinal tract and are responsible for intestinal peristaltic movement [9].

In most cases (85%), the mutation associated with GIST is known [2]. The ratio of the frequency of key mutations, along with their typical location and characteristics, is presented in Table 1 [7, 12]. From 70 to 80% of patients have activating mutations in the *KIT* proto-oncogene (CD117), leading to constitutive activation of KIT, with the largest number (60–70%) of mutations affecting the paramembrane domain

encoded by exon 11 [13], followed by the extracellular domain encoded by exon 9 (7–10%) [14]. Exon 11 mutations are most often deletions in the reading frame, insertions, substitutions, missense mutations, or their combinations [7, 15]. The kinase domain of *KIT* with exon 9 mutation is essentially the same as in wild-type KIT, which is essential in sensitivity to inhibition [7]. Mutations in exon 13 within the activation loop and exon 17 are sporadic. These mutations occur in tumors arising in the small and large intestines, rarely observed in gastric GISTs, and their gene expression profile differs from tumors with the *KIT* exon 11 mutation [16]. Mutations associated with *KIT* lead to the arrest of intracellular pathways, i.e., MAPK (RAF, MEK, and MAPK), PI3K-AKT, and STAT3, which regulate gene expression, cell division, differentiation, motility, and apoptosis [7, 17].

Further 10–15% of GIST cases involve mutations in the *PDGFRA* gene [18]. From 10 to 15% of patients with no detectable *KIT* or *PDGFRA* mutations are classified as "wild-type" GIST [18]. Most new cases of GIST are spontaneous, and only 5% are associated with genetic syndromes such as neurofibromatosis type 1 (NF1), succinate dehydrogenase (SDH) enzyme deficiency; Carney's triad, primary familial GIST syndrome; and Carney-Stratakis syndrome [19].

The most effective and, indeed, the only method that can ensure a complete cure of primary and localized GISTs is surgical resection of the tumor [20]. In the case of inoperable tumors, neoadjuvant treatment with imatinib can reduce the tumor mass [11, 21].

Imatinib is also used as an adjuvant treatment in patients after complete resection of the primary GIST with a high risk of recurrence [22–24]. It is not used for wild-type or *PDGFRA-D842V* mutant GISTs or for *NF1*-associated GISTs without SDH expression, as well as for *BRAF* mutations or *NTRK* rearrangements [5].

In the case of unresectable and metastatic GISTs, systemic treatment with kinase inhibitors is the standard. In the first-line treatment, international guidelines recommend the use of imatinib, which, after observation for more than 4 years, showed an approximately 4-fold increase (from 12–15 months to approximately 5 years) in median overall survival (mOS) in the group of patients with advanced GIST. Imatinib therapy for inoperable or metastatic GISTs rarely gives a complete response — it is found only in about 5–7% of patients [11]. About half are partial remissions, and in 36%, the disease is stabilized. From 10 to 15% of cases, correctly qualified for treatment (GIST CD117+), are characterized by primary and early resistance to treatment observed during the first 6 months of treatment [25]. On the other hand, in about 40–50% of patients, secondary resistance and disease progression are observed within 2–3 years of imatinib treatment [11, 26]. Imatinib is most effective in treating GIST with primary mutations, including *KIT* mutations within exon 11 (intracellular paramembrane domain) (Fig. 1). In the case of the presence of *KIT* exon 9 mutations, which are less sensitive to imatinib, according to the meta-analysis of the studies EORTC 62005 and SWOG S0033/CALGB 15105, a higher starting dose of imatinib (800 mg/day) should be used as opposed to the standard dose of 400 mg/day [11, 27]. The second line of treatment is sunitinib [median progression-free survival (PFS) 6–8 months] [11], and the third line is regorafenib (median PFS 4.4–4.8 months) [28], which are also KIT inhibitors [29].

For the *PDGFRA-D842V* mutation, insensitive to imatinib regardless of the dose, treatment with avapritinib is indicated [30], which in the phase I NAVIGATOR clinical trial achieved a response rate of 91%, with median PFS (mPFS) of 34 months and an estimated 3-year overall survival (OS) rate of 71% [31].

Disease progression during treatment with kinase inhibitors is most often due to new secondary mutations in *KIT* or *PDGFRA*, which are located mainly in the *KIT* ATP binding domain (exons 13 and 14) or the activation loop (exons 17 and 18) and, in the case of *PDGFRA,* in the ATP binding domain (exons 13, 14, 15) [32]. Recent studies show that ripretinib is advantageous in treating secondary mutations, as it inhibits other kinases, such as PDGFRB, TIE2, VEGFR2, and BRAF *in vitro* (Fig. 1) [33–35].

Mechanism of action, pharmacokinetics, and pharmacodynamics of ripretinib

Ripretinib is a new inhibitor of tyrosine kinases, particularly KIT kinase, which has found its application in treating unresectable and resistant forms of GISTs [33, 36]. Unlike its predecessors — imatinib, sunitinib, and regorafenib — it has the broadest spectrum of activity [35]. Ripretinib, as the first of the KIT inhibitors, is applicable in inhibiting all tested *KIT* and *PDGFRA* mutations, except for the D842V mutation, but also in wild-type GISTs. It inhibits other kinases such as PDGFRB, TIE2, VEGFR2, and BRAF *in vitro* [33–35].

All three currently used KIT inhibitors — imatinib, sunitinib, and regorafenib — bind to the inactive conformation of KIT or PDGFRA; therefore, they are classified as type II inhibitors [35, 37]. On the other hand, ripretinib, which belongs to the same group, exhibits exceptional activity in active KIT structures, which was

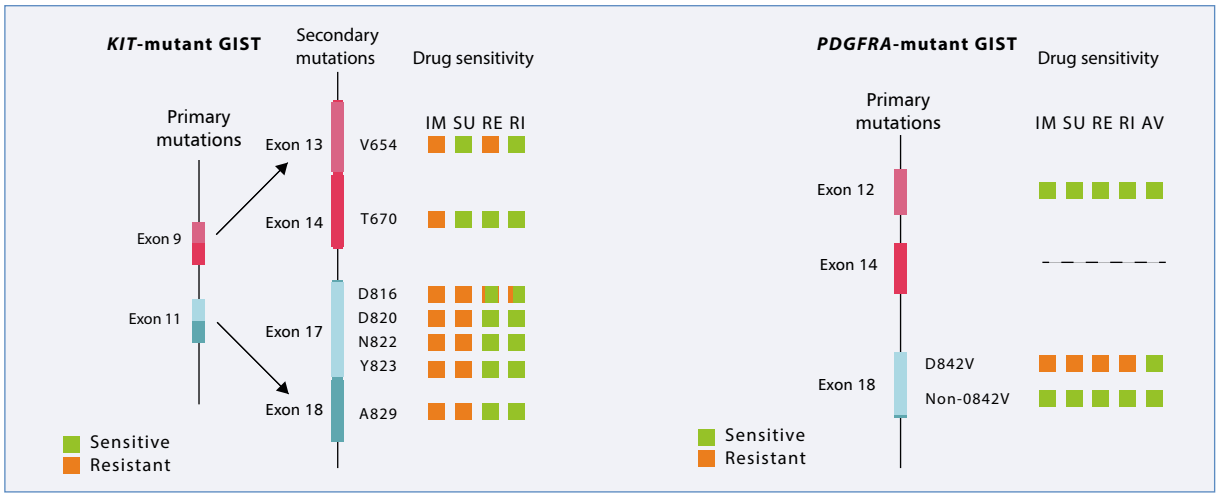

Figure 1. Comparison of the activities of kinase inhibitors used in the treatment of gastrointestinal stromal tumor (GIST) in relation to the most common primary and secondary mutations found in GISTs; AV — avapritinib; IM — imatinib; RE — regorafenib; RI — ripretinib; SU — sunitinib

previously attributed only to type I inhibitors [35]. For this reason, ripretinib can inhibit not only primary but also secondary mutations [35, 38]. Its innovative mechanism of action is based on the inhibition of two domains related to exon 11 and exon 9, regardless of the type of mutation, primary or secondary [39].

Ripretinib has a dual-pronged effect. It is an antagonist because it blocks the phosphorylation of the switch and the activation loop, preventing the transformation of KIT into the active form. At the same time, it plays a stabilizing role [34, 36]. In *in vitro* studies, ripretinib potently inhibited further tumor cell proliferation and KIT phosphorylation and induced apoptosis in all cell lines harboring mutations in *KIT* (exons 9, 11, 13, 14, 17, 18) and *PDGFRA* (exons 12, 14, 18). Therefore, it has a beneficial effect in the treatment of other myeloproliferative diseases, e.g., in mast cell leukemia (MCL) or systemic mastocytosis (SM), where KIT mutations can be detected in over 90% of cases [35, 40].

Preclinical studies aimed at determining ripretinib safety profile were conducted on research groups of mice [35], rats, and dogs. Common side effects observed in all groups included skin changes, hyperpigmentation, and an increase in the activity of liver enzymes [41]. In addition, vomiting and abnormal stools were observed in the group of tested dogs [41]. Studies in pregnant rats and rabbits have shown that ripretinib can be teratogenic and cause fetal harm or complete pregnancy loss. On this basis, women of childbearing age and their partners should use effective contraception during treatment with ripretinib and one week after its completion [42]. The effect of ripretinib on oral contraceptives has not been studied [35, 41].

Ripetinib is metabolized in hepatocytes by CYP3A, while excretion is renal. Co-administration of ripretinib with CYP3A inhibitors (ketoconazole, erythromycin, clarithromycin, itraconazole, ritonavir, posaconazole, voriconazole, and grapefruit juice) potentiates its effects and increases the risk of adverse reactions. At the same time, using ripretinib with strong CYP3A inducers reduces its anticancer effect [34]. Mild or moderate renal or hepatic impairment is not an indication for dose reduction [41]. In the INVICTUS study, of the 85 patients who received 150 mg daily ripretinib, 24% were aged 65–74, and only 9% were aged ≥ 75. This group was too small to determine significant clinical differences in the effect of the same dose in different age groups [42].

The half-life for ripretinib is four hours, and for its equally active metabolite DP-5439, 15.6 hours [34]. Ripretinib and DP-5439 are highly bound to plasma proteins (both human serum albumin (99.8% and 99.7%, respectively) and α-1-acid glycoprotein (99.4% and > 99.8%) [34], which is a contraindication to its use in patients with extreme renal or hepatic insufficiency. The elimination half-life of ripretinib and DP-5439 is 14.8 and 17.8 hours, respectively [34]. So far, studies on the presence of ripretinib in breast milk have not been conducted [42]. Due to the long half-life of ripretinib and its metabolites, breastfeeding is not recommended during and up to one week after treatment [43].

Efficacy of ripretinib in clinical trials

Phase I/II trials

The first open-label multicenter phase I clinical trial of ripretinib was conducted in 2015–2019 [44]. Two hundred fifty-eight adult patients were enrolled, including 184 patients with advanced GIST who were intolerant or had progressed to more than one line of systemic therapy. The main objective was to evaluate the safety, dose-limiting toxicity (DLT), maximum tolerated dose (MTD), and initial anticancer activity [44].

Patients in the dose escalation phase (n = 68) received ripretinib 20–200 mg twice daily or 100–250 mg once daily in repeated 28-day cycles until disease progression, unacceptable toxicity, or withdrawal of consent. Three dose-limiting adverse events were reported during the study — an asymptomatic grade 3 increase in lipase that occurred with 100 mg twice daily and 200 mg twice daily and an asymptomatic increase in creatine phosphokinase grade 4 with 150 mg once daily. An MTD could not be established, and the final determination of the recommended phase 2 dose (RP2D) of 150 mg/day was based on analysis of the safety profile, pharmacokinetics, and pharmacodynamics [44].

The study showed that ripretinib showed beneficial results already in earlier lines of treatment. For second-line patients, median PFS was 10.7 months [95% confidence interval (CI) 5.5–13.8]; in the third-line — 8.3 months (95% CI 5.5–11.1) and 5.5 months (95% CI 3.6–6.2) in the fourth and subsequent lines. The objective response rate (ORR) was 19.4%, 14.3%, and 7.2%, respectively [44].

The results of this study contributed to initiation of further studies on ripretinib in the treatment of advanced GISTs, including a phase III study (INVICTUS study, NCT03353753) and a study comparing ripretinib with sunitinib in the second-line treatment (INTRIGUE study, NCT03673501).

Phase III INVICTUS trial

The randomized phase III INVICTUS trial (NCT03353753) was a double-blind placebo-controlled trial [33]. The study aimed to test the efficacy and safety of ripretinib as a fourth-line therapy in GIST. The study enrolled 129 adult participants diagnosed with advanced GIST who were intolerant to or had failed prior treatment with at least three lines of anticancer therapy (including imatinib, sunitinib, and regorafenib).

Patients were randomized into two groups in a 2:1 ratio to receive either ripretinib (n = 85) or placebo (n = 44). Patients took 150 mg of ripretinib daily, and in case of adverse reactions, the dose was reduced to 100 mg and 50 mg. In patients with disease progression, the dose was escalated to 300 mg/day [42]. It has been shown that the use of ripretinib at a dose of 150 mg/day may correlate with the occurrence of cardiac dysfunction; therefore, it was recommended to assess ejection fraction before starting treatment and to monitor it during treatment [33].

The primary endpoint was PFS, and the secondary was ORR and OS. Median PFS in the blinded central assessment was 6.3 months (95% CI 4.6–8.1) for ripretinib versus 1.0 months (95% CI 0.9–1.7) for placebo [hazard ratio (HR) = 0.16; 95% CI 0.10–0.2] [33, 45]. For comparison, median PFS in clinical trials for sunitinib in the second line was 5.6 months, and for regorafenib in the third line — 4.8 months [28, 46]. Objective responses were found in 9.4% of patients treated with ripretinib. Long-term data from the INVICTUS study demonstrated that ripretinib showed a clinical improvement in overall survival (OS) from 6.3 months (95% CI 4.1–10.0) to 18.2 months (95% CI 13.1–30.7) (HR = 0.41; 95% CI 0.26–0.65) [45].

Interesting data are provided by the analysis of 29 patients receiving placebo who subsequently received ripretinib after progression. Clinical benefit in this group was already observed after one month of treatment, and two patients had a partial response to treatment. Median PFS in this group was 4.6 months [95% CI 1.8–not reached (NE)]. Median OS, calculated from the start of the study, was 11.6 months in the cross-over group (95% CI 6.3–NE) [47].

When assessing the impact of ripretinib on quality of life (QoL), the INVICTUS study (NCT03353753) showed that patients in the drug group rated their quality of life higher than patients in the placebo group. Self-assessment of health status using the VAS EQ-5D-5L questionnaire in patients receiving ripretinib showed an increasing trend, while it decreased in the placebo group [48]. Patients treated with ripretinib assessed their physical functioning as improving, while patients from the placebo group reported its deterioration [48, 49]. In summary, patients receiving ripretinib showed a statistically significant improvement in general health and QoL compared to patients receiving placebo, which showed that ripretinib, apart from favorable PFS and OS, also showed a favorable safety profile [48].

The risk of bias in the study was assessed as low. The study's limitations include the randomization process, as a result of which the compared groups were heterogeneous regarding age. In the placebo group, the percentage of patients aged ≥ 65 years was 50% while in the study

group, it was 33%. Patients aged ≥ 75 years also prevailed in the group treated with a placebo (22.7%) compared to the group treated with ripretinib (9.4%) [50].

Phase III INTRIGUE trial

The randomized multicenter open-label phase III trial INTRIGUE was completed in March 2022 [51]. The study aimed to compare the efficacy and safety profile of ripretinib with sunitinib in the second line of treatment in patients with advanced GISTs with disease progression on imatinib treatment. The study included 453 patients aged ≥ 18 years, assigned into two groups in a 1:1 ratio — 226 in the ripretinib group and 227 in the sunitinib group [52].

Inclusion criteria included confirmed *KIT*/*PDGFRA* mutation, disease progression or insensitivity to imatinib, and ECOG performance status ≤ 2. Ripretinib was used at a dose of 150 mg/day for 42 days, and sunitinib at 60 mg/day according to the schedule of 4 weeks of treatment and two weeks off [52].

The primary endpoint was PFS studied in two intention-to-treat (ITT) populations: patients with *KIT* exon 11 mutations and the entire study population. Secondary endpoints included ORR, OS, safety, and QoL.

Median PFS for ripretinib and sunitinib in the *KIT* exon 11 mutation group was 8.3 and 7.0 months, respectively (HR = 0.88; 95% CI 0.66–1.16; p = 0.36) and in the overall population 8.0 and 8.3 months, respectively (HR = 1.05; 95% CI 0.82–1.33; p = 0.72), which showed no benefit of ripretinib over sunitinib [51]. The ORR was higher for ripretinib than sunitinib in the *KIT* exon 11 ITT population (23.9% *vs*. 14.6%, p = 0.03) and the overall group (21.7% *vs*. 17.6%, p = 0.27). When comparing the safety profiles, ripretinib was associated with fewer grade 3-4 adverse events (41.3% *vs*. 65.6%, p < 0.0001) and better patient-reported tolerance [51].

The results showed that ripretinib was not superior to sunitinib in terms of PFS. However, it showed a more favorable safety profile and a higher response rate than sunitinib. The study's authors emphasize that a longer follow-up is indicated to make an adequate comparison of OS because median OS has not yet been reached [51].

An exploratory analysis of the effect of mutations found in circulating DNA (ctDNA) on treatment outcomes was also performed. Patients with exon 11 mutations in addition to exon 17 or 18 *KIT* mutations had longer PFS (14.2 *vs*. 1.5 months), OS (NE *vs*. 17.5 months), and higher ORR (44.4% *vs*. 0%) for ripretinib than sunitinib, while sunitinib was superior in PFS (4.0 *vs*. 15.0 months), OS (24.5 *vs*. NE month), and ORR (9.5% *vs*. 15.0%) for mutations in *KIT* exon 13 or 14 [53].

A QoL assessment using the European Organization for Research and Treatment of Cancer (EORTC) quality of life questionnaire QLQ-C30 showed that patients on sunitinib experienced greater impairment than patients on ripretinib (C7 D29: −22.7 *vs*. −8.7). In patients treated with sunitinib, side effects intensified with each subsequent day of the cycle, while in the case of ripretinib, side effects did not show cyclical variability [51]. The impact of skin lesions on patients' quality of life as measured by the Dermatology Life Quality Index was significantly lower for ripretinib than for sunitinib (C7 D29: 14.3% *vs*. 26.0%) [51].

Adverse events

Patients (n = 450) treated with ripretinib had similar drug-related adverse events in phase I–II and phase III studies. Most were grade 1 or 2 [33, 44, 51] (Tab. 2). The most common adverse event was alopecia (Tab. 2), which occurred in 62% of patients in the phase I–II study and 49% and 64.1% in the two phase III studies. Other common (> 20%) adverse events were fatigue, myalgia, constipation, nausea, palmar-plantar erythrodysesthesia syndrome, anorexia, and diarrhea.

In grades 3 and 4, most adverse events were associated with increased blood pressure (5.6% in phase I–II, 4%, and 8.5% in phase III studies) and increased lipase (17.6% in phase I–II and 5% in phase III of the study). Equally common (> 2%) were abdominal pain, fatigue, anemia, and hypophosphatemia [33, 44, 51].

A total of 20 (4.4%) patients discontinued treatment due to drug-related adverse events [33, 44, 51], namely: 5.6% in phase I–II, 5% in phase III INVICTUS, and 3.6% in the phase III INTRIGUE trial. One treatment-related death was reported in the phase III INVICTUS study (cause unknown; death during sleep) [33].

Different groups of patients, pharmacokinetics, and pharmacodynamics of individual KIT inhibitors prevent absolute comparison of their safety profile; however, it allows for visualing the type and frequency of their occurrence (Tab. 3 [28, 33, 52, 54–57]). When using ripretinib, the most common side effect is alopecia, for regorafenib and sunitinib — hand-foot syndrome, and for imatinib — edema [26, 33, 46, 58]. Moreover, it has been shown that sunitinib can cause leukopenia, neutropenia, lymphopenia, and thrombocytopenia [46, 58]. The majority of adverse events for all KIT inhibitors were in Grades 1–2 [28, 58]. In the INTRIGUE study comparing the safety profile of ripretinib to sunitinib in the second line of treatment, ripretinib was associated with fewer grade 3–4 adverse events (41.3% *vs*. 65.6 for sunitinib) and better self-measured tolerability outcomes [51].

Table 2. Comparison of the incidence of adverse events with ripretinib (150 mg) in clinical trials [33, 44, 51]

Adverse events	Phase I–II trials [44] (n = 142) No. (%)		Phase III INVICTUS trial [33] (n = 85), No. (%)		Phase III INTRIGUE trial [51] (n = 223) No. (%)		Overall n = 450 No. (%)	
	Grade 1–2	Grade 3–4	Grade 1–2	Grade 3–4	Grade 1–2	Grade 3–4	Grade 1–2	Grade 3–4
Alopecia	88 (62.0)	–	42 (49.0)	–	143 (64.1)	–	273 (60,7)	–
Fatigue	74 (52.1)	4 (2.8)	20.0 (24)	2 (2.0)	84 (37.3)	7 (3.1)	178 (39.6)	13 (2.9)
Myalgia	69 (48.6)	0	23 (27.0)	1 (1.0)	81 (36.3)	4 (1.8)	173 (38.4)	5 (1.1)
Nausea	63 (44.4)	2 (1.4)	21 (25.1)	1 (1.0)	53 (23.8)	2 (0.9)	137 (30.4)	5 (1.1)
Hand-foot syndrome	61 (43.0)	1 (0.7)	18 (21.0)	–	59 (26.5)	3 (1.3)	138 (30.7)	4 (0.9)
Constipation	56 (39.4)	0	13 (15.0)	0	78 (35.0)	1 (0.4)	147 (32.7)	1 (0.2)
Lack of appetite	46 (32.4)	2 (1.4)	12 (14.0)	1 (1.0)	60 (26.9)	2 (0.9)	118 (26.2)	5 (1.1)
Diarrhea	44 (31.0)	3 (2.1)	17 (20.0)	1 (1.0)	42 (18.8)	2 (0.9)	103 (22.9)	6 (1.3)
Stomach pain	29 (20.4)	13 (9.2)	–	–	58 (26.0)	6 (2.7)	84 (18.7)	19 (4.2)
Muscle cramps	42 (29.6)	0	10 (12.0)	–	–	–	52 (11.6)	–
Lipase elevation	14 (9.9)	25 (17.6)	4 (5.0)	4 (5.0)	–	–	18 (4)	29 (6.4)
Body weight loss	39 (27.5)	0	13 (15.0)	–	–	–	52 (11.6)	–
Vomiting	37 (26.1)	1 (0.7)	–	–	–	–	37 (8.2)	1 (0.2)
Headache	36 (25.4)	1 (0.7)	–	–	–	–	36 (8)	1 (0.2)
Arthritis	32 (22.5)	0	10 (12.0)	–	–	–	42 (9.3)	–
Dry skin	32 (22.5)	0	–	–	–	–	32 (7.1)	–
Hypertension	24 (16.9)	8 (5.6)	4 (5.0)	3 (4.0)	59 (26.5)	19 (8.5)	87 (19.3)	30 (6.7)
Anemia	19 (13.4)	10 (7.0)	2 (2.0)	1 (1.0)	–	–	21 (4.7)	11 (2.4)
Back pain	27 (19.0)	2 (1.4)	–	–	–	–	27 (6)	2 (0.4)
Dyspnea	25 (17.6)	3 (2.1)	–	–	–	–	25 (5.6)	3 (0.7)
Cough	25 (17.6)	0	–	–	–	–	25 (5.6)	–
Vertigo	25 (17.6)	0	–	–	–	–	25 (5.6)	–
Hypophosphatemia	17 (12.0)	7 (4.9)	3 (4.0)	2 (2.0)	–	–	20 (4.4)	9 (2)
Rash	23 (16.2)	0	–	–	–	–	23 (5.1)	–

Real-world evidence

The results of the INVICTUS study are confirmed by data from clinical pratice. Administration of ripretinib to 22 patients from Taiwan and Hong Kong diagnosed with advanced unresectable or metastatic GIST showed efficacy similar to that obtained in the INVICTUS study. The final survival analysis included 20 patients treated with ripretinib at 150 mg daily [59]. The observation period was one year, and the median observation period after treatment with ripretinib was 10.4 months [59]. Median PFS was 6.1 months, and median OS was not reached [59]. The safety profile of ripretinib was comparable to the INVICTUS study, and the most common adverse event reported by patients was alopecia, which was observed in 55% of patients [59]. The study also showed that an albumin level below 3.5 was an independent adverse prognostic factor for PFS [59].

Similar results were also obtained in a single-arm phase II study (NCT04282980) in the Chinese population. The final analysis included 38 patients diagnosed with advanced GIST who underwent therapy with at least three kinase inhibitors [60]. Median PFS was 7.2 months (90% CI 2.9–7.3), and the ORR was 18.4% (95% CI 7.7–34.3) [60]. The majority of adverse events that occurred in 37 (94.9%) patients were Grade 1-2, reflecting the well-tolerated treatment in the INVICTUS study. The most common side effect was alopecia, which occurred in 17 patients (43.6%) [60].

Table 3. Comparison of the incidence of the most common adverse reactions by KIT inhibitor in phase III clinical trials [28, 33, 52, 54–57]

Adverse event	Imatinib 400 mg n = 428 [54, 55] No. (%)		Imatinib 800 mg n = 472 [56]		Sunitinib n = 228 [57] No. (%)		Regorafenib n = 132 [28] No. (%)		Ripretinib n = 308 [33, 52] No. (%)	
	Overall	Grade 3–4	Overall	Grade 3–4	Overall	Grade 3–4	Overall	Grade 3–4	Overall	Grade 3–4
Hand–foot syndrome	–	–	–	–	24 (10.5)	8 (3.5)	56 (42.42)	20 (15.2)	77 (25.0)	3 (1.0)
Edema	274 (64.0)	7 (1.6)	412 (87.3)	43 (9.1)	–	–	–	–	–	–
Nausea	156 (36.4)	9 (2.1)	286 (60.6)	15 (3.2)	63 (27.6)	3 (1.3)	16 (12.1)	1 (0.8)	75 (24.4)	3 (1.0)
Diarrhea	151 (35.3)	12 (2.8)	268 (56.8)	25 (5.3)	77 (33.8)	8 (3.5)	40 (30.3)	5 (3.8)	60 (19.5)	3 (1.0)
Myalgia	–	–	–	–	–	–	14 (10.6)	1 (0.8)	105 (34.1)	5 (1.6)
Fatigue	178 (41.6)	8 (1.9)	374 (79.2)	51 (10.8)	85 (37.3)	18 (7.9)	39 (29.6)	2 (1.5)	106 (34.4)	9 (2.9)
Dermatitis, rash	101 (23.6)	11 (2.6)	220 (46.6)	25 (5.3)	36 (15.8)	2 (0.9)	18 (13.6)	2 (1.5)	–	–
Stomach pain	109 (25.5)	14 (3.3)	–	–	–	–	–	–	–	–
Alopecia	–	–	–	–	–	–	24 (18.2)	2 (1.5)	185 (60.1)	–
Hypertension	–	–	–	–	27 (11.8)	9 (3.9)	49 (37.1)	23 (17.4)	66 (21.4)	22 (7.1)
Stomatitis	–	–	–	–	36 (15.8)	1 (0.4)	38 (28.8)	2 (1.5)	–	–
Skin discoloration	–	–	–	–	62 (27.2)	0 (0.0)	–	–	–	–
Constipation	–	–	87 (18.4)	7 (1.5)	–	–	–	–	91 (29.5)	1 (0.3)
Lack of appetite	–	–	–	–	46 (20.2)	0 (0.0)	–	–	73 (23.7)	3 (1.0)
Vomiting	78 (18.22)	8 (1.9)	180 (38.1)	13 (2.8)	39 (17.1)	1 (0.4)	–	–	–	–
Anemia	–	–	461 (97.7)	79 (16.7)	133 (58.3)	9 (3.9)	–	–	–	–
Fever	–	–	81 (17.2)	6 (1.3)	–	–	–	–	–	–

In both studies, in case of disease progression, patients had the option of increasing the dose of ripretinib to 300 mg daily [59, 60].

In a retrospective study conducted in Great Britain on a group of 45 patients, after 21.5 months of observation, ripretinib at a dose of 150 mg/day achieved mPFS of 7.4 months (95% CI 5.6–10.0) [61]. In the case of 23 patients with disease progression after receiving the 300 mg dose, mPFS was further 5.9 months (95% CI 3.5–9.2) [61]. Overall, PFS and OS were 12.2 (95% CI 7.9–17.6) and 14.0 (95% CI 9.9–NA) months, respectively. There was no relationship between the number of previous lines of treatment and survival after ripretinib initiation. Primary mutation in *KIT* exon 11 was associated with a better prognosis [61].

Ripretinib in clinical practice guidelines

According to the latest Polish [Polish Society of Clinical Oncology (PTOK)] and international [European Society for Medical Oncology (ESMO), European Reference Network on Rare Adult Cancers (EURACAN), European Reference Network on GENetic TUmour RIsk Syndromes (GENTURIS), National Comprehensive Cancer Network (NCCN) 2022] guidelines, the standard in the treatment of advanced, inoperable, or metastatic GIST is the inclusion of KIT inhibitors. In the case of imatinib-sensitive GISTs, it is the first line of treatment at a dose of 400 mg/day. If *KIT* exon 9 mutation is present, an increased dose of imatinib of 800 mg/day can be considered, according to the

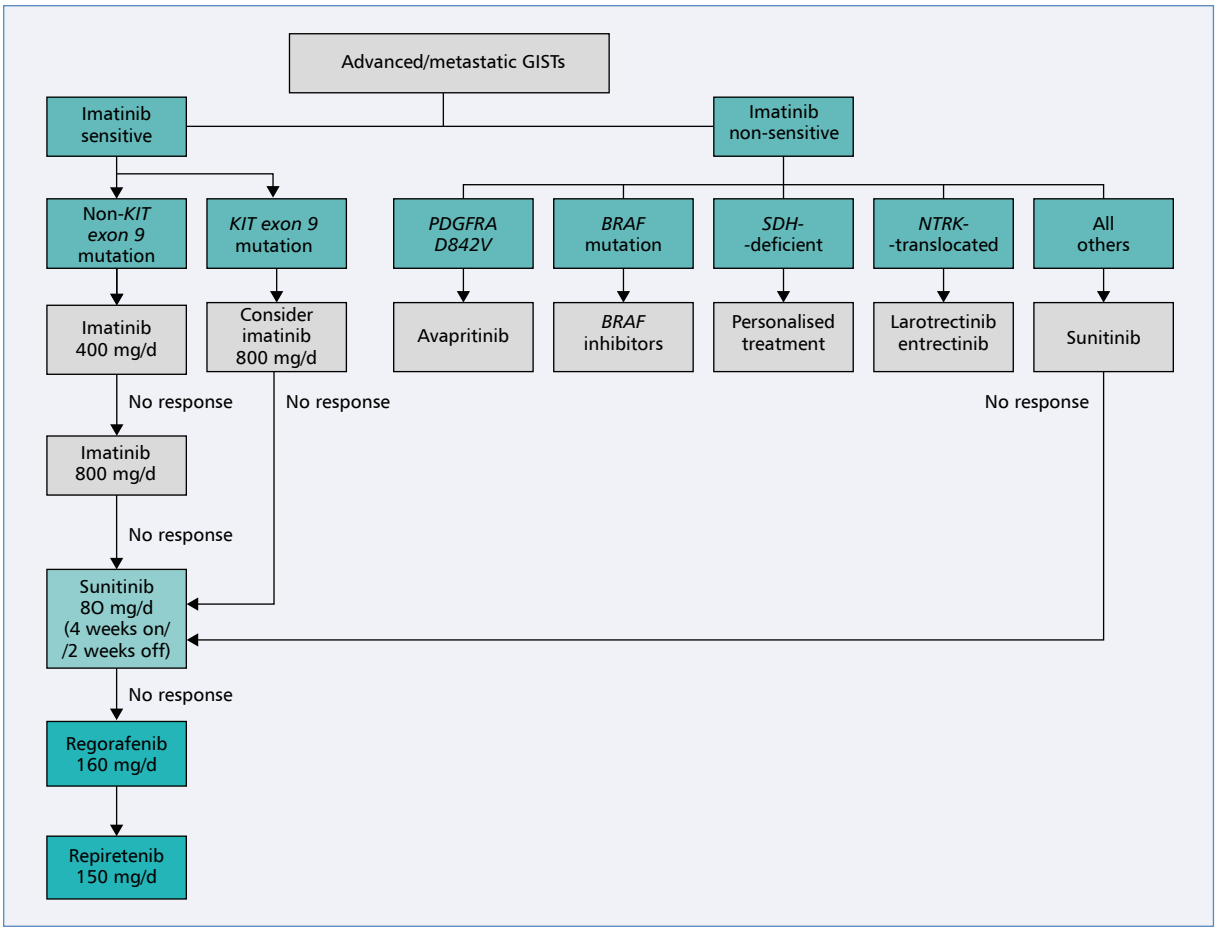

Figure 2. Treatment algorithm in advanced or metastatic gastrointestinal stromal tumors (GISTs) [5, 11]

scheme presented in Figure 2 [5, 11]. In patients with the *PDGFRA* D842V mutation, neoadjuvant treatment with avapritinib achieves a favorable result [5]. In the case of further progression of inoperable lesions, the remaining KIT inhibitors: sunitinib, regorafenib, and ripretinib, are recommended in the appropriate order, according to the scheme presented in Figure 2 [5].

According to the latest Polish and international guidelines (ESMO 2022 and NCCN 2022), ripretinib is the preferred option for fourth-line treatment in patients with inoperable, progressive, or metastatic GIST after treatment with imatinib, sunitinib, and regorafenib at a dose of 150 mg/day [5]. The guidelines also include increasing the dose of ripretinib to 150 mg twice daily as an option for patients whose disease has progressed while taking the drug at a dose of 150 mg/day [62, 63]. Further clinical trials are needed to confirm the efficacy of ripretinib in the treatment of GIST with *PDGFRA D842V* mutations. In the case of progression of GIST with the *PDGFRA D842V* mutation after the use of avapritinib or dasatinib, the guidelines allow the use of ripretinib at a dose of 150 mg/day as an option that may show a positive treatment effect [35]. It is also possible to consider increasing the dose to 150 mg twice daily [62].

Practical recommendations

Ripretinib is an oral-only drug. It should be taken at the same time every day, with or without food [5]. The tablets should not be divided, crushed, or chewed [41, 42]. The standard dose is 150 mg/day, as three 50 mg tablets taken together [5]. The recommended dose in patients with severe renal impairment has not been established, and clinical data on the use of ripretinib at creatinine clearance (CLcr) < 30 mL/min are limited [41]. Mild hepatic impairment is not an indication for dose modification. In patients with moderate or severe hepatic impairment, the overall effectiveness of treatment should be closely monitored; the recommended dose in this case is not known [41].

Table 4. Summary of clinical trial results with ripretinib in patients with advanced gastrointestinal stromal tumor (GIST) [33, 44, 51]

	Phase I–II trial [44] (n = 142)			Phase III INVICTUS trial [33] (n = 85)	Phase III INTRIGUE trial [51] (n = 223)	
Line of therapy	2	3	4	4	2	
Mutations	All patients			All patients	All patients	*KIT* exon 11
Median PFS [months] (95% CI)	10.7 (5.5–13.8)	8.3 (5.5–11.1)	5.5 (3.6–6.2)	6.3 (4.6–8.1)	8.0 (0.82–1.33)	8.3 (0.66–1.16)
Median OS [months] (95% CI)	Not reached			18.2 (13.1-30.7)	Not reached	
ORR [%] (95% CI)	19.4 (7.5–37.5)	14.3 (4.0–32.7)	7.2 (2.7–15.1)	9.4 (4.2–17.7)	21.7	23.9 (17.6–31.2)

CI — confidence interval; ORR — objective response rate; OS — overall survival; PFS — progression-free survival

Clinical trials have shown no clinically significant differences between elderly patients (> 65 years) and younger patients (age ≥ 18 years to ≤ 65). The drug's safety profile in children has not been studied [42].

Contraindications to the use of ripretinib include hypersensitivity to the active substance or any of the excipients listed in the list of excipients, i.e., crospovidone (E1202), hypromellose acetate succinate, lactose monohydrate, magnesium stearate (E470b), microcrystalline cellulose (E460), silica, colloidal hydrate (E551) [5, 41, 42].

Conclusions

The identification of activating mutations in the KIT gene and the confirmation of the effectiveness of imatinib, which was initially used in the treatment of chronic myeloid leukemias, was a breakthrough in the treatment of GISTs. However, longer-term follow-up showed the presence of primary or secondary resistance to imatinib treatment and, thus, the need for new therapeutic options. In the following years, sunitinib, sorafenib, and regorafenib were added to the standard set of drugs for GIST patients, and the latest molecule that is used in this indication is ripretinib. The studies conducted so far indicate the activity of this drug in a particular group of patients, and it allows them to achieve median PFS of over 6 months in the 4th line of treatment and over 8 months in the second line of treatment (Tab. 4 [33, 44, 51]). The higher efficacy of ripretinib compared to sunitinib in the second line of treatment has not been demonstrated; therefore, according to the national and international guidelines, it can be used only in the fourth line after prior treatment with imatinib, sunitinib, and regorafenib. Treatment tolerance is satisfactory and allows for maintaining a good quality of life. Further studies and analyses are underway to identify the subgroups of patients in whom the drug is most effective.

Article Information and Declarations

Author contributions

E.B.: literature review, preparation of the original version of the manuscript, preparation of figures; A.S.: literature review, preparation of the original version of the manuscript, preparation of figures; P.S.: preparation of the work concept, literature review; preparation of the final version of the manuscript, supervision of the team; P.R.: preparation of the final version of the manuscript, supervision of the team.

All authors approved the final version of the manuscript.

Funding

None.

Acknowledgments

None.

Conflict of interest

E.B., A.S. declare no conflict of interest.

P.S. received travel grants from BMS, MSD, and Novartis; speakers' honoraria from Sandoz, BMS, and Gilead, Advisory Board fees from Sandoz; is the holder of Celon Pharma shares.

P.R. received speakers' honoraria from Astra Zeneca, Merck, MSD, BMS, Novartis, Pierre Fabre, and Sanofi; remuneration for participation in the Advisory Board of Blueprint Medicines, BMS, Merck, MSD, Philogen, Pierre Fabre, and Sanofi; research funding from BMS and Pfizer.

Supplementary material

None.

References

1. Kelly CM, Gutierrez Sainz L, Chi P. The management of metastatic GIST: current standard and investigational therapeutics. J Hematol Oncol. 2021; 14(1): 2, doi: 10.1186/s13045-020-01026-6, indexed in Pubmed: 33402214.
2. Corless CL, Barnett CM, Heinrich MC. Gastrointestinal stromal tumours: origin and molecular oncology. Nat Rev Cancer. 2011; 11(12): 865–878, doi: 10.1038/nrc3143, indexed in Pubmed: 22089421.
3. Cassier PA, Ducimetière F, Lurkin A, et al. A prospective epidemiological study of new incident GISTs during two consecutive years in Rhône Alpes region: incidence and molecular distribution of GIST in a European region. Br J Cancer. 2010; 103(2): 165–170, doi: 10.1038/sj.bjc.6605743, indexed in Pubmed: 20588273.
4. Søreide K, Sandvik OM, Søreide JA, et al. Global epidemiology of gastrointestinal stromal tumours (GIST): A systematic review of population-based cohort studies. Cancer Epidemiol. 2016; 40: 39–46, doi: 10.1016/j.canep.2015.10.031, indexed in Pubmed: 26618334.
5. Casali PG, Blay JY, Abecassis N, et al. Gastrointestinal stromal tumours: ESMO–EURACAN–GENTURIS Clinical Practice Guidelines for diagnosis, treatment and follow-up. Ann Oncol. 2022; 33(1): 20–33, doi: 10.1016/j.annonc.2021.09.005, indexed in Pubmed: 34560242.
6. Miettinen M, Lasota J. Gastrointestinal stromal tumors: review on morphology, molecular pathology, prognosis, and differential diagnosis. Arch Pathol Lab Med. 2006; 130(10): 1466–1478, doi: 10.5858/2006-130-1466-GSTROM, indexed in Pubmed: 17090188.
7. Blay JY, Kang YK, Nishida T, et al. Gastrointestinal stromal tumours. Nat Rev Dis Primers. 2021; 7(1): 22, doi: 10.1038/s41572-021-00254-5, indexed in Pubmed: 33737510.
8. Nishida T, Blay JY, Hirota S, et al. The standard diagnosis, treatment, and follow-up of gastrointestinal stromal tumors based on guidelines. Gastric Cancer. 2016; 19(1): 3–14, doi: 10.1007/s10120-015-0526-8, indexed in Pubmed: 26276366.
9. Fletcher CDM, Berman JJ, Corless C, et al. Diagnosis of gastrointestinal stromal tumors: a consensus approach. Int J Surg Pathol. 2002; 10(2): 81–89, doi: 10.1177/106689690201000201, indexed in Pubmed: 12075401.
10. Hanks SK, Quinn AM, Hunter T. The protein kinase family: conserved features and deduced phylogeny of the catalytic domains. Science. 1988; 241(4861): 42–52, doi: 10.1126/science.3291115, indexed in Pubmed: 3291115.
11. Rutkowski P, Koseła-Paterczyk H, Kozak K, et al. Postępowanie diagnostyczno-terapeutyczne u chorych na mięsaki tkanek miękkich u dorosłych — zalecenia ekspertów. Onkol Prakt Klin Edu. 2023; 9(3): 149–180.
12. Klug LR, Khosroyani HM, Kent JD, et al. New treatment strategies for advanced-stage gastrointestinal stromal tumours. Nat Rev Clin Oncol. 2022; 19(5): 328–341, doi: 10.1038/s41571-022-00606-4, indexed in Pubmed: 35217782.
13. Singer S, Rubin BP, Lux ML, et al. Prognostic value of KIT mutation type, mitotic activity, and histologic subtype in gastrointestinal stromal tumors. J Clin Oncol. 2002; 20(18): 3898–3905, doi: 10.1200/JCO.2002.03.095, indexed in Pubmed: 12228211.
14. Roberts KG, Odell AF, Byrnes EM, et al. Resistance to c-KIT kinase inhibitors conferred by V654A mutation. Mol Cancer Ther. 2007; 6(3): 1159–1166, doi: 10.1158/1535-7163.MCT-06-0641, indexed in Pubmed: 17363509.
15. Mol CD, Dougan DR, Schneider TR, et al. Structural basis for the autoinhibition and STI-571 inhibition of c-Kit tyrosine kinase. J Biol Chem. 2004; 279(30): 31655–31663, doi: 10.1074/jbc.M403319200, indexed in Pubmed: 15123710.
16. Kang DY, Park CK, Choi JS, et al. Multiple gastrointestinal stromal tumors: Clinicopathologic and genetic analysis of 12 patients. Am J Surg Pathol. 2007; 31(2): 224–232, doi: 10.1097/01.pas.0000213318.66800.94, indexed in Pubmed: 17255767.
17. Duensing A, Medeiros F, McConarty B, et al. Mechanisms of oncogenic KIT signal transduction in primary gastrointestinal stromal tumors (GISTs). Oncogene. 2004; 23(22): 3999–4006, doi: 10.1038/sj.onc.1207525, indexed in Pubmed: 15007386.
18. Debiec-Rychter M, Sciot R, Le Cesne A, et al. EORTC Soft Tissue and Bone Sarcoma Group, Italian Sarcoma Group, Australasian GastroIntestinal Trials Group. KIT mutations and dose selection for imatinib in patients with advanced gastrointestinal stromal tumours. Eur J Cancer. 2006; 42(8): 1093–1103, doi: 10.1016/j.ejca.2006.01.030, indexed in Pubmed: 16624552.
19. Vanden Bempt I, Vander Borght S, Sciot R, et al. Comprehensive targeted next-generation sequencing approach in the molecular diagnosis of gastrointestinal stromal tumor. Genes Chromosomes Cancer. 2021; 60(4): 239–249, doi: 10.1002/gcc.22923, indexed in Pubmed: 33258138.
20. Burch J, Ahmad I. Gastrointestinal Stromal Cancer. In: StatPearls 2022. StatPearls Publishing LLC, Treasure Island (FL) 2022.
21. Rutkowski P, Gronchi A, Hohenberger P, et al. Neoadjuvant imatinib in locally advanced gastrointestinal stromal tumors (GIST): the EORTC STBSG experience. Ann Surg Oncol. 2013; 20(9): 2937–2943, doi: 10.1245/s10434-013-3013-7, indexed in Pubmed: 23760587.
22. Joensuu H, Eriksson M, Sundby Hall K, et al. Adjuvant Imatinib for High-Risk GI Stromal Tumor: Analysis of a Randomized Trial. J Clin Oncol. 2016; 34(3): 244–250, doi: 10.1200/JCO.2015.62.9170, indexed in Pubmed: 26527782.
23. Joensuu H, Eriksson M, Sundby Hall K, et al. One vs three years of adjuvant imatinib for operable gastrointestinal stromal tumor: a randomized trial. JAMA. 2012; 307(12): 1265–1272, doi: 10.1001/jama.2012.347, indexed in Pubmed: 22453568.
24. Joensuu H, Wardelmann E, Sihto H, et al. Effect of KIT and PDGFRA Mutations on Survival in Patients With Gastrointestinal Stromal Tumors Treated With Adjuvant Imatinib: An Exploratory Analysis of a Randomized Clinical Trial. JAMA Oncol. 2017; 3(5): 602–609, doi: 10.1001/jamaoncol.2016.5751, indexed in Pubmed: 28334365.
25. Blanke CD, Demetri GD, von Mehren M, et al. Long-term results from a randomized phase II trial of standard- versus higher-dose imatinib mesylate for patients with unresectable or metastatic gastrointestinal stromal tumors expressing KIT. J Clin Oncol. 2008; 26(4): 620–625, doi: 10.1200/JCO.2007.13.4403, indexed in Pubmed: 18235121.
26. Demetri GD, von Mehren M, Blanke CD, et al. Efficacy and safety of imatinib mesylate in advanced gastrointestinal stromal tumors. N Engl J Med. 2002; 347(7): 472–480, doi: 10.1056/NEJMoa020461, indexed in Pubmed: 12181401.
27. Gastrointestinal Stromal Tumor Meta-Analysis Group (MetaGIST). Comparison of two doses of imatinib for the treatment of unresectable or metastatic gastrointestinal stromal tumors: a meta-analysis of 1,640 patients. J Clin Oncol. 2010; 28(7): 1247–1253, doi: 10.1200/JCO.2009.24.2099, indexed in Pubmed: 20124181.
28. Demetri GD, Reichardt P, Kang YK, et al. GRID study investigators. Efficacy and safety of regorafenib for advanced gastrointestinal stromal tumours after failure of imatinib and sunitinib (GRID): an international, multicentre, randomised, placebo-controlled, phase 3 trial. Lancet. 2013; 381(9863): 295–302, doi: 10.1016/S0140-6736(12)61857-1, indexed in Pubmed: 23177515.
29. Mazzocca A, Napolitano A, Silletta M, et al. New frontiers in the medical management of gastrointestinal stromal tumours. Ther Adv Med Oncol. 2019; 11: 1758835919841946, doi: 10.1177/1758835919841946, indexed in Pubmed: 31205499.
30. Heinrich MC, Jones RL, von Mehren M, et al. Avapritinib in advanced PDGFRA D842V-mutant gastrointestinal stromal tumour (NAVIGATOR): a multicentre, open-label, phase 1 trial. Lancet Oncol. 2020; 21(7): 935–946, doi: 10.1016/S1470-2045(20)30269-2, indexed in Pubmed: 32615108.
31. Jones R, Serrano C, Mehren Mv, et al. Avapritinib in unresectable or metastatic PDGFRA D842V-mutant gastrointestinal stromal tumours: Long-term efficacy and safety data from the NAVIGATOR phase I trial. Eur J Cancer. 2021; 145: 132–142, doi: 10.1016/j.ejca.2020.12.008.
32. Grunewald S, Klug LR, Mühlenberg T, et al. Resistance to Avapritinib in PDGFRA-Driven GIST Is Caused by Secondary Mutations in the PDGFRA Kinase Domain. Cancer Discov. 2021; 11(1): 108–125, doi: 10.1158/2159-8290.CD-20-0487, indexed in Pubmed: 32972961.
33. Blay JY, Serrano C, Heinrich MC, et al. Ripretinib in patients with advanced gastrointestinal stromal tumours (INVICTUS): a double-blind, randomised, placebo-controlled, phase 3 trial. Lancet Oncol. 2020; 21(7): 923–934, doi: 10.1016/S1470-2045(20)30168-6, indexed in Pubmed: 32511981.
34. Dhillon S. Ripretinib: First Approval. Drugs. 2020; 80(11): 1133–1138, doi: 10.1007/s40265-020-01348-2, indexed in Pubmed: 32578014.
35. Smith BD, Kaufman MD, Lu WP, et al. Ripretinib (DCC-2618) Is a Switch Control Kinase Inhibitor of a Broad Spectrum of Oncogenic and Drug-Resistant KIT and PDGFRA Variants. Cancer Cell. 2019; 35(5): 738–751.e9, doi: 10.1016/j.ccell.2019.04.006, indexed in Pubmed: 31085175.
36. Mohammadi M, Gelderblom H. Systemic therapy of advanced/metastatic gastrointestinal stromal tumors: an update on progress beyond imatinib, sunitinib, and regorafenib. Expert Opin Investig Drugs. 2021;

30(2): 143–152, doi: 10.1080/13543784.2021.1857363, indexed in Pubmed: 33252274.
37. DiNitto JP, Deshmukh GD, Zhang Y, et al. Function of activation loop tyrosine phosphorylation in the mechanism of c-Kit auto-activation and its implication in sunitinib resistance. J Biochem. 2010; 147(4): 601–609, doi: 10.1093/jb/mvq015, indexed in Pubmed: 20147452.
38. Lostes-Bardaji MJ, García-Illescas D, Valverde C, et al. Ripretinib in gastrointestinal stromal tumor: the long-awaited step forward. Ther Adv Med Oncol. 2021; 13: 1758835920986498, doi: 10.1177/1758835920986498, indexed in Pubmed: 33473249.
39. Pilco-Janeta DF, García-Valverde A, Gomez-Peregrina D, et al. Emerging drugs for the treatment of gastrointestinal stromal tumors. Expert Opin Emerg Drugs. 2021; 26(1): 53–62, doi: 10.1080/14728214.2021.1896704, indexed in Pubmed: 33645383.
40. Arock M, Sotlar K, Akin C, et al. KIT mutation analysis in mast cell neoplasms: recommendations of the European Competence Network on Mastocytosis. Leukemia. 2015; 29(6): 1223–1232, doi: 10.1038/leu.2015.24, indexed in Pubmed: 25650093.
41. EMA. Quinlock Charakterystyka Produktu Leczniczego.
42. Pharmaceuticals., D., QINLOCK™ (ripretinib) tablets: US prescribing information 2020.
43. Ripretinib, in Drugs and Lactation Database (LactMed). 2006, National Library of Medicine (US): Bethesda (MD).
44. Janku F, Abdul Razak AR, Chi P, et al. Switch Control Inhibition of KIT and PDGFRA in Patients With Advanced Gastrointestinal Stromal Tumor: A Phase I Study of Ripretinib. J Clin Oncol. 2020; 38(28): 3294––3303, doi: 10.1200/JCO.20.00522, indexed in Pubmed: 32804590.
45. Mehren Mv, Heinrich MC, George S, et al. 1540P Ripretinib as ≥4th-line treatment in patients with advanced gastrointestinal stromal tumor: Long-term update from the phase III INVICTUS study. Annals of Oncology. 2021; 32: S1120–S1121, doi: 10.1016/j.annonc.2021.08.870.
46. Demetri GD, van Oosterom AT, Garrett CR, et al. Efficacy and safety of sunitinib in patients with advanced gastrointestinal stromal tumour after failure of imatinib: a randomised controlled trial. Lancet. 2006; 368(9544): 1329–1338, doi: 10.1016/S0140-6736(06)69446-4, indexed in Pubmed: 17046465.
47. Serrano C, Heinrich M, George S, et al. O-13 Efficacy and safety of ripretinib as ≥4th-line therapy for patients with gastrointestinal stromal tumor following crossover from placebo: Analyses from INVICTUS. Ann Oncol. 2020; 31: 236, doi: 10.1016/j.annonc.2020.04.066.
48. Heinrich M, George S, Zalcberg J, et al. Quality of life (QoL) and self-reported function with ripretinib in ≥4th-line therapy for patients with gastrointestinal stromal tumors (GIST): Analyses from INVICTUS. J Clin Oncol. 2020; 38(15_suppl): 11535–11535, doi: 10.1200/jco.2020.38.15_suppl.11535.
49. Schöffski P, George S, Heinrich MC, et al. Patient-reported outcomes in individuals with advanced gastrointestinal stromal tumor treated with ripretinib in the fourth-line setting: analysis from the phase 3 INVICTUS trial. BMC Cancer. 2022; 22(1): 1302, doi: 10.1186/s12885-022-10379-9, indexed in Pubmed: 36514034.
50. Załącznik do Raportu oceny technologii o wysokiej innowacyjności w ramach Funduszu Medycznego za rok 2022, nr 18: Qinlock (ripretynib) we wskazaniu: w leczeniu dorosłych pacjentów z zaawansowanym nowotworem podścieliskowym przewodu pokarmowego (GIST), którzy byli wcześniej leczeni trzema lub więcej inhibitorami kinazy, w tym imatynibem. Opracowanie analityczne 18.02.2022.
51. Bauer S, Jones RL, Blay JY, et al. Ripretinib Versus Sunitinib in Patients With Advanced Gastrointestinal Stromal Tumor After Treatment With Imatinib (INTRIGUE): A Randomized, Open-Label, Phase III Trial. J Clin Oncol. 2022; 40(34): 3918–3928, doi: 10.1200/JCO.22.00294, indexed in Pubmed: 35947817.
52. Heinrich M, Jones R, Gelderblom H, et al. INTRIGUE: A phase III, randomized, open-label study to evaluate the efficacy and safety of ripretinib versus sunitinib in patients with advanced gastrointestinal stromal tumor previously treated with imatinib. J Clin Oncol. 2022; 40(36_suppl): 359881–359881, doi: 10.1200/jco.2022.40.36_suppl.359881.
53. Bauer S, Jones R, George S, et al. Mutational heterogeneity of imatinib resistance and efficacy of ripretinib vs sunitinib in patients with gastrointestinal stromal tumor: ctDNA analysis from INTRIGUE. J Clin Oncol. 2023; 41(36_suppl): 397784–397784, doi: 10.1200/jco.2023.41.36_suppl.397784.
54. Raut CP, Espat NJ, Maki RG, et al. Efficacy and Tolerability of 5-Year Adjuvant Imatinib Treatment for Patients With Resected Intermediate- or High-Risk Primary Gastrointestinal Stromal Tumor: The PERSIST-5 Clinical Trial. JAMA Oncol. 2018; 4(12): e184060, doi: 10.1001/jamaoncol.2018.4060, indexed in Pubmed: 30383140.
55. Dematteo RP, Ballman KV, Antonescu CR, et al. American College of Surgeons Oncology Group (ACOSOG) Intergroup Adjuvant GIST Study Team. Adjuvant imatinib mesylate after resection of localised, primary gastrointestinal stromal tumour: a randomised, double-blind, placebo-controlled trial. Lancet. 2009; 373(9669): 1097–1104, doi: 10.1016/S0140-6736(09)60500-6, indexed in Pubmed: 19303137.
56. Verweij J, Casali PG, Zalcberg J, et al. Progression-free survival in gastrointestinal stromal tumours with high-dose imatinib: randomised trial. Lancet. 2004; 364(9440): 1127–1134, doi: 10.1016/S0140-6736(04)17098-0, indexed in Pubmed: 15451219.
57. Demetri GD, Garrett CR, Schöffski P, et al. Complete longitudinal analyses of the randomized, placebo-controlled, phase III trial of sunitinib in patients with gastrointestinal stromal tumor following imatinib failure. Clin Cancer Res. 2012; 18(11): 3170–3179, doi: 10.1158/1078-0432.CCR-11-3005, indexed in Pubmed: 22661587.
58. Zalcberg JR. Ripretinib for the treatment of advanced gastrointestinal stromal tumor. Therap Adv Gastroenterol. 2021; 14: 17562848211008177, doi: 10.1177/17562848211008177, indexed in Pubmed: 33948116.
59. Lin LC, Huang WK, Yen CC, et al. Compassionate Use of Ripretinib for Patients With Metastatic Gastrointestinal Stromal Tumors: Taiwan and Hong Kong Experience. Front Oncol. 2022; 12: 883399, doi: 10.3389/fonc.2022.883399, indexed in Pubmed: 35847924.
60. Li J, Cai S, Zhou Y, et al. Efficacy and Safety of Ripretinib in Chinese Patients with Advanced Gastrointestinal Stromal Tumors as a Fourth- or Later-Line Therapy: A Multicenter, Single-Arm, Open-Label Phase II Study. Clin Cancer Res. 2022; 28(16): 3425–3432, doi: 10.1158/1078-0432.CCR-22-0196, indexed in Pubmed: 35686969.
61. Napolitano A, Lim SY, Lopez LFF, et al. 80P Expanded access program use of ripretinib in advanced GIST patients in the United Kingdom. ESMO Open. 2023; 8(1): 101117, doi: 10.1016/j.esmoop.2023.101117.
62. von Mehren M, Kane JM, Riedel RF, et al. NCCN Guidelines® Insights: Gastrointestinal Stromal Tumors, Version 2.2022. J Natl Compr Canc Netw. 2022; 20(11): 1204–1214, doi: 10.6004/jnccn.2022.0058, indexed in Pubmed: 36351335.
63. Zalcberg JR, Heinrich MC, George S, et al. Clinical Benefit of Ripretinib Dose Escalation After Disease Progression in Advanced Gastrointestinal Stromal Tumor: An Analysis of the INVICTUS Study. Oncologist. 2021; 26(11): e2053–e2060, doi: 10.1002/onco.13917, indexed in Pubmed: 34313371.

Aleksandra Piórek, Adam Płużański, Kinga Winiarczyk, Sylwia Tabor, Magdalena Knetki-Wróblewska, Dariusz Mirosław Kowalski, Maciej Krzakowski

Department of Lung Cancer and Thoracic Tumors, Maria Sklodowska-Curie National Research Institute of Oncology, Warsaw, Poland

Tracheal cancers

Address for correspondence:
Aleksandra Piórek, MD PhD
Department of Lung Cancer and Thoracic Tumors, Maria Sklodowska-Curie National Research Institute of Oncology
ul. Roentgena 5, 02–781 Warsaw, Poland
e-mail: aleksandra.piorek@pib-nio.pl

Oncology in Clinical Practice
DOI: 10.5603/ocp.97601
Copyright © 2024 Via Medica
ISSN 2450–1654
e-ISSN 2450–6478

ABSTRACT

Primary tracheal tumors are very rare and the literature on this subject is limited. Due to their rarity and diversity, the provision of patient care in terms of optimal management poses a considerable challenge. There are no unequivocal guidelines concerning the treatment in patients with local or distant disease. The most common types of primary tracheal tumors are squamous cell carcinoma and adenoid cystic carcinoma. Squamous cell carcinoma of the trachea is 2–4 times more common in men than in women and develops primarily in the sixth and seventh decades of life. It is strongly associated with tobacco smoking. Adenoid cystic carcinoma of the trachea occurs with similar frequency in men and women, and is most common in the fourth and fifth decades of life. The etiology of this type is unknown, however it is not associated with tobacco smoking. Adenoid cystic carcinoma is characterized by submucosal and perineural spread. Treatment of patients with primary tracheal tumors requires a multidisciplinary approach. Optimal treatment of localized tumors is based on surgery or radiotherapy. If distant metastases are present the therapeutic palliative methods are: chemotherapy, palliative radiotherapy or palliative surgery. The prognosis of patients with primary tracheal tumors is determined by several factors. Histological diagnosis of adenoid cystic carcinoma, good performance status, and complete resection have been identified as favorable prognostic factors. Despite intensive treatment, the 5-year survival rate for primary tracheal tumors is not satisfactory.

Keywords: tracheal tumors, tracheal cancers, adenoid cystic carcinoma of the trachea, squamous cell carcinoma of the trachea, treatment
Oncol Clin Pract 2024; 20, 1: 52–59

Epidemiology

Primary tracheal tumors are rare. They account for 0.2% of all respiratory tract cancers and 0.02% to 0.04% of all malignant tumors [1]. The annual incidence is approximately 0.1 cases per 100,000 individuals. About 90% of primary tracheal tumors in adults are malignant. In comparison, malignant tumors account for 10–30% of cases in children [1]. Squamous cell carcinoma (SCC) and adenoid cystic carcinoma (ACC) both represent over two-thirds of primary tracheal tumors in adults [2]. In a large epidemiological study on primary tracheal tumors using data from the SEER (Surveillance, Epidemiology, and End Results) database, among 578 cases from 1973 to 2004, SCC was the dominant histological type (44.8%), followed by ACC (16.3%), unspecified or undifferentiated carcinoma (12.8%), small cell carcinoma (9.7%), adenocarcinoma (5.9%), large cell carcinoma (3.8%), and sarcoma (3.8%) [3].

Squamous cell carcinoma

Macroscopically, SCC typically appears as multiple and often ulcerating lesions growing into the lumen of the trachea. These lesions vary in the degree of cellular differentiation and may or may not exhibit keratinization [4]. Histologically, SCC of the lung and trachea are identical [5]. The tumor can affect any part of the trachea, and in one-third of patients at the time of diagnosis,

Received: 28.09.2023 Accepted: 02.10.2023 Early publication date: 25.10.2023

This article is available in open access under Creative Common Attribution-Non-Commercial-No Derivatives 4.0 International (CC BY-NC-ND 4.0) license, allowing to download articles and share them with others as long as they credit the authors and the publisher, but without permission to change them in any way or use them commercially.

there are metastatic lesions in the mediastinum or lungs [2]. It occurs 2 to 4 times more frequently in men than in women, primarily in the 6th and 7th decades of life [2, 5–7]. The etiopathogenesis is closely linked to tobacco smoking [5, 6]. In 30–40% of cases, SCC coexists with a metachronous or synchronous second primary tobacco-related tumor in the oral part of the throat, larynx, or lungs [2, 5].

Adenoid cystic carcinoma

Adenoid cystic carcinoma of the trachea is most commonly observed in the 4th and 5th decades of life [5–7]. It occurs 2 to 4 times more frequently in men than in women, primarily in the 6th and 7th decades of life [2, 5–7]. The etiology of the tumor is unknown, and unlike SCC, it is not associated with tobacco smoking [5, 6, 8].

This tumor originates from small salivary and serous glands present in the submucosal membrane of the trachea, and the morphological picture of ACC corresponds to primary salivary gland tumors [9]. Macroscopically, ACC often grows as an exophytic tumor, leading to the narrowing of the tracheal lumen [2]. The morphological picture is characteristic, with two types of cells: ductal cells with scant cytoplasm and hyperchromatic angular nuclei that stain positive for cytokeratin (CK7) and flattened myoepithelial cells that stain positive for myoepithelial markers (p63, SMA, calponin). The biphasic appearance highlighted by immunohistochemistry is crucial for differential diagnosis. Cells form cribriform, tubular, and solid patterns [10]. The percentage of solid areas determines the degree of histological differentiation. In cases of uncertainty, immunohistochemical staining with MYB antibody can be performed — a positive result indicates the MYB gene translocation characteristic of ACC, which can be confirmed by fluorescence in situ hybridization (FISH) [11, 12]. Submucosal and perineural spread characterize ACC [13]. At the time of diagnosis, regional lymph node metastases or distant metastases are present in only about 10% of patients [2]. Although the growth rate of ACC is often slow, in some cases, it may present a more aggressive course with a tendency for local invasion and metastasis. Furthermore, even after a very long disease-free period, local or systemic recurrences can occur [2, 5].

Other histological types

Primary tracheal tumors other than ACC and SCC are rare and histologically diverse. They are not easily classified and are usually reported together with ACC and SCC [3, 5, 14, 15]. In one of a few studies focusing on other histological types of tracheal tumors, 33 different histological diagnoses were made among 90 patients [16]. Diagnoses were divided into 5 groups, including benign tumors, carcinoids, other salivary gland-type tumors (including mucoepidermoid carcinoma; MEC), sarcomas, and non-squamous cell carcinomas. Malignant tracheal tumors were diagnosed in 62% of patients. The diagnoses involved 54 men and 36 women with an average age of 43 years (range 4–81 years). In another study, 23 different histological types of malignant tracheal tumors were presented with an analysis of the age at which peak incidence occurs among selected types [7]. In yet another study, among other malignant tracheal tumors, carcinoids, lymphomas, melanomas, MEC, non-squamous cell carcinomas, and sarcomas were distinguished [5].

Clinical presentation

Clinical symptoms of tracheal tumors can result from airway obstruction (shortness of breath, wheezing, stridor), irritation and ulceration of the mucous membrane (cough, hemoptysis), or direct invasion of neighboring structures (nerve paralysis, dysphagia). The disease is often diagnosed late due to the large functional reserves of the tracheal lumen. Initial symptoms only appear when the tracheal lumen is narrowed by 50–75%. Exertional dyspnea occurs when the tracheal lumen narrows to 8 mm (resting dyspnea at 5 mm) [2, 5]. The presented symptoms are nonspecific and can lead to a misdiagnosis of asthma, chronic obstructive pulmonary disease, or bronchitis. The most common symptom of tracheal SCC is hemoptysis. The occurrence of hemoptysis usually leads to early diagnosis of the tumor. However, hemoptysis is present in fewer than 25% of patients at early stage of the disease. The absence of symptoms often leads to a delay in diagnosis, sometimes by several months [2]. The development of hoarseness and dyspnea typically indicates advanced disease. Wheezing and stridor are the most common symptoms in the case of ACC.

Diagnosis

Conventional chest X-ray only detects abnormalities in 18–28% of patients, and it is not recommended for the diagnosis of tracheal tumors [9]. The standard imaging method for evaluating tracheal tumors and assessing their extent, including the involvement of adjacent and distant structures, is computed tomography (CT). Magnetic resonance imaging (MRI) may have an advantage in the case of ACC [2]. Most SCCs show high fluorodeoxyglucose uptake in positron emission tomography-computed tomography (PET-CT), but ACC exhibits variable uptake depending on the degree of differentiation [17].

Diagnosis is based primarily on bronchoscopic examination, which allows for precise localization of the lesion, assessment of the extent of the disease, and the collection of tissue samples for pathological examination [18].

Staging

Tracheal tumors, due to their rarity, are not included in the TNM classification system for malignant tumors. There are only proposals for classification, which have not been prospectively confirmed, describing the anatomical extent of the disease [2, 6, 14, 19–21]. Assessing the anatomical extent of the lesions can help decide on the choice and feasibility of a particular treatment method and may have prognostic value. In a study published in 2022, a collection of publications proposing a method for determining the stage of primary tracheal cancer was presented, and attempts were made to examine the prognostic significance of TNM in patients with primary tracheal tumors [22].

Treatment

Radical surgical treatment

Radical surgical treatment, if the extent of the disease allows, is the treatment of choice. The type of surgery depends on the location and size of the primary tumor as well as the involvement of adjacent structures [2]. Tracheal tumors are considered resectable if the affected tracheal segment can be safely removed and reconstructed with a primary anastomosis. This depends not only on the extent of the disease but also on the patient's age, body mass, neck mobility, and comorbidities [5]. Older patients with limited neck mobility may not be candidates for resections longer than 2–4 cm, while in younger and taller individuals, over 6 cm of the trachea can be removed [5, 23]. This assessment also depends on the operator's experience. Nowadays, precise preoperative planning and improved reconstruction techniques allow for the safe removal of even more than 50% of the tracheal length in selected cases [6]. Routine extensive lymphadenectomy is not recommended due to the risk of compromising blood flow to the remaining part of the trachea and hindered anastomotic healing [2, 5, 23]. Removal of clearly enlarged and altered lymph nodes is only recommended [24].

Tracheal SCC resection aims to achieve microscopically radical excision (R0) while preserving good postoperative function. This is achieved in approximately two-thirds of surgeries in large centers [25]. Intraoperative histological analysis using frozen section evaluation helps determine margin status and potentially increases the scope of the operation unless safe reconstruction limits have been reached, and additional resection is ruled out [5]. Non-radical resection is more common in ACC due to its characteristic growth pattern. This tumor spreads submucosally and along the course of nerve trunks beyond the visible tumor boundaries. Positive surgical margins are found in 40–50% of patients undergoing resection for ACC [25]. Most patients, after non-radical resections, receive adjuvant radiotherapy [5, 25].

Palliative surgical treatment

Palliative surgical treatment aims to restore the lumen of the narrowed part of the airways when radical treatment is not possible or serves as a bridge to radical treatment in patients with severe symptoms caused by airway obstruction. Restoration of the airway can be achieved through various endoscopic techniques, including mechanical endoscopic dilation, laser vaporization, electrocoagulation, cryotherapy, photodynamic therapy, or argon coagulation [2, 26]. In most cases, these methods provide improvement but often require repeated procedures and do not guarantee a permanent effect. In non-operative cases, airway patency improvement can be achieved using stents. Satisfactory palliative results can be achieved in 80–90% of properly selected patients [2]. However, literature reports indicate that despite efforts to improve the material used to create a functional scaffold, the limitation of the method is granulation within the tracheal lumen caused by the foreign body, which can lead to an increase in the length of the constriction. Other drawbacks include stent migration and the esophageal and vascular fistulas [5]. Self-expandable metal stents can be used in patients with an expected survival of 3–6 months [5]. They are not suitable for non-operative patients diagnosed with ACC. In these patients, long-term survival is observed despite advanced disease. Some authors prefer silicone stents in such cases. However, both techniques should be reserved for patients for whom future surgery is not planned [26].

Postoperative radiotherapy

The discussion regarding the use of adjuvant radiotherapy (RT) remains inconclusive. Postoperative RT is often used despite limited evidence of its effectiveness in all patients [7]. Treatment begins when the surgical anastomosis is fully healed. The effect of tracheal wall tension may persist for some time, and treatment typically starts around 2 months after surgery or later in cases where there are significant concerns about the risk of anastomotic leakage [5]. The standard total dose in adjuvant

treatment is 54–60 Gy in conventional fractionation (2 Gy per fraction) [2, 5]. In cases with larger residual tumor masses, the dose may be increased to 68–70 Gy (2 Gy per fraction) [2]. Postoperative RT planning should be based on the preoperative CT scan [27]. Patients who have undergone limited resection due to the length of the involved trachea and reconstructive possibilities are eligible for treatment [5]. In most studies, adjuvant RT is also recommended for microscopically incomplete resections although this is not based on prospective randomized studies. Fifty-nine percent of ACC patients treated at the Massachusetts General Hospital had "positive" surgical margins, compared to 18% of SCC patients [5]. Other factors considered in adjuvant RT include local tumor advancement, invasion beyond the lymph node capsule, and perineural or vascular invasion. In a retrospective "matched-pair" analysis conducted by Xie et al. [28] based on the SEER database, an attempt was made to determine the impact of RT on improving outcomes in patients with malignant primary tracheal tumors. Patients who received RT were matched to patients with similar demographic characteristics, tumor histology, disease extent, and surgical resection. RT improved survival, especially in patients diagnosed with SCC ($p < 0.0001$) and regional disease ($p = 0.030$). In a study by Wen et al. [21] based on data from 405 patients from the SEER database, nomograms predicting overall survival (OS) were created. Using the propensity score matching method, the authors found a favorable effect of adjuvant RT only in cases of SCC. It should be noted that the nomograms did not include surgical margin status. In their discussion, the authors pointed out the lack of this information in the SEER database. On the other hand, a retrospective analysis of patients treated at the MD Anderson Cancer Center did not show a statistically significant OS improvement after adjuvant RT [6].

In the case of tracheal ACC, therapeutic decisions are complicated by additional factors. This tumor exhibits low radiation sensitivity, but its specific growth pattern often results in "positive" margins. Additionally, late local recurrences of ACC are observed even after radical resections [29]. Available literature data are inconclusive — some centers recommend postoperative RT for all patients, while others use radiation therapy in cases with "positive" surgical margins or do not recommend adjuvant RT due to its lack of impact on overall survival [29].

The decision about postoperative RT should be made individually in each case.

Radical radiotherapy

The standard of care for patients with tracheal tumors should involve radical resection, which is applied to fewer than 25% of patients eligible for radical treatment [30]. For the remaining patients, radical radiotherapy is considered an alternative therapeutic option [31]. Indications for RT include locoregional disease, where radical surgical treatment is not feasible [25]. Radical RT is also used in patients who do not qualify for resection due to non-oncologic reasons or do not consent to surgery. Patients in good overall condition after a thorough assessment of the tumor extent are eligible for radiation therapy. The required dose to achieve local control is 70 Gy (35 fractions over 7 weeks) [5, 25]. RT should be planned using conformal techniques, preferably with intensity-modulated radiation therapy (IMRT) [27]. However, there are limited data on modern RT methods using precise radiation techniques, such as image-guided radiation therapy (IGRT) and IMRT, as well as proton therapy or carbon ion (C12) radiation [25, 32].

Intraluminal brachytherapy (8–15 Gy) has shown an impact on improving local tumor control when combined with external beam RT (60–68 Gy) in the radical intraluminal treatment [2]. Further research is needed to determine the maximum and optimal intraluminal brachytherapy dose as a method to increase the total dose in combination with external beam RT [2].

Palliative radiotherapy

Palliative radiation therapy is used to relieve symptoms caused by local tumor growth in patients who are not eligible for radical treatment. The most common indications include hemoptysis, pain, dyspnea, and cough. A good palliative effect can be achieved in 75% of treated patients. In the group treated with palliative intent at the Bydgoszcz Oncology Center, an improvement in presented symptoms was observed, which correlated with an objective response in the irradiated tumor area. The average response time was 12.5 months [33].

Radiochemotherapy

The combined radiochemotherapy (RCTH) approach is an established method for the radical treatment of many locally advanced cancers. The biological basis for combining both methods lies in increasing the effectiveness of local and regional cures while reducing the risk of distant metastases. Radiochemotherapy is also used as part of organ-sparing procedures (as an alternative to very extensive surgical procedures). Concurrent RCTH with cisplatin is the treatment of choice for patients with locally advanced head and neck cancers. Concurrent and sequential RCTH has been shown to be superior to standalone RT in the treatment of locally advanced lung cancers and is the standard of care in such cases. Data regarding the combination of chemotherapy (CTH) and RT for tracheal tumors are very limited. There are only individual case reports and retrospective studies involving very small groups of patients. Published studies have used RCTH

in both concurrent and sequential forms. Most studies focus on concurrent treatment, which includes CTH using carboplatin (AUC 2) and paclitaxel (50 mg/m^2) administered weekly, combined with conventional fractionated conformal RT to a total dose of 60–66 Gy [31, 34–36]. Other centers prefer cisplatin (80 mg/m^2 on days 1 and 28) with vinorelbine (12.5 mg/m^2 on days 1, 8, and 15) with concurrent RT with a dose of 60 Gy, followed by an additional 2 cycles of CTH [25]. Sequential treatment CTH regimens include carboplatin (AUC 5) and paclitaxel (175 mg/m^2) given every 21 days or the PELF regimen consisting of cisplatin, etoposide, leucovorin, and fluorouracil. In the PELF regimen, 2 cycles of induction CTH are administered, followed by 2 additional cycles with RT at a dose of 60 Gy in 30 fractions [31, 37]. Toxicity most commonly involves acute esophageal reactions.

Systemic treatment

The clinical course of ACC is characterized by relatively slow growth, and regional lymph node metastases are rare. In the early years of observation, local treatment is highly effective (with 5-year disease-free survival rates ranging from 50% to 75%). However, in subsequent years of observation, there is an increased number of patients with local recurrences or distant metastases. Approximately 10–15% of patients remain disease-free after 15 years of follow-up [38]. Distant metastases most commonly occur in the lungs [10, 39]. Patients with lung metastases tend to have a better prognosis than those with metastases in other organs [38]. Lung metastases typically grow expansively and often remain asymptomatic for many years [40]. Among a large group of patients (62) treated at the Mayo Clinic between 1972 and 2002, distant metastases were observed in 40.5% of cases [10]. Fifteen patients with ACC had distant metastases primarily to the lungs, brain, chest wall, and liver [10]. Advanced disease at diagnosis is described very rarely. In another study, non-operable patients accounted for 23% (8), with only 3 having stage IV disease at the outset [41]. In two other studies, patients at clinical stage IV at the time of diagnosis accounted for 8.3% (1) and 10% (3), respectively [11, 40]. Adenoid cystic carcinoma has limited chemosensitivity. There are limited data in the literature regarding systemic treatment for tumors located in the trachea. In the study mentioned above, attempts were made to use CTH in patients with stage IV disease [41]. The first patient received a regimen of gemcitabine and cisplatin, but the disease progressed due to the enlargement of the primary lesion and mediastinal lymph nodes after two cycles of treatment. The second patient received vinorelbine and cisplatin, which reduced symptoms and stabilized the disease on imaging studies. In patients who experienced disease progression during the observation period, only one showed a response to treatment with paclitaxel and cisplatin [41]. Another study described the effectiveness of combining carboplatin and paclitaxel, as well as one case of the effectiveness of uracil-tegafur and cisplatin in combination with RT [29, 34]. In two of the largest studies that evaluated systemic treatment in patients with ACC of the head and neck region, the limited role of CTH was confirmed, with a low frequency and short duration of responses. In patients with unresectable recurrences or ACC metastases, CTH may only be considered in the case of rapid progression; in patients with clinical symptoms, it can be considered after ruling out the possibility of using local treatment methods (palliative RT, resection of a single metastatic lesion). Monotherapy is preferred for its lower toxicity in the event of a decision to administer chemotherapy. Drugs that have shown objective responses include mitoxantrone, vinorelbine, and epirubicin [38, 42]. For head and neck ACC, research is ongoing into the use of systemic and targeted therapies [43–47]. New molecularly targeted drugs are being evaluated. In one study, whole-genome sequencing was used to better understand the genetic changes underlying metastatic ACC and identify potential therapeutic targets [43]. The analysis was based on material from five patients with ACC (including 2 cases of ACC originating in the trachea). The analysis revealed a small number of mutations, consistent with findings from other studies. Each patient had potential therapeutic targets identified. Based on the results, three patients received dedicated molecularly targeted treatment in phase I and II clinical trials. Two of them achieved disease stabilization. The identification of molecular targets in ACC may lead to potentially effective systemic treatment.

There are no established systemic treatment regimens for advanced SCC of the trachea. Only individual case reports, mainly concerning combination therapy, are available. In daily practice, regimens adapted from the treatment of squamous cell carcinomas of the head and neck, and lung are most commonly used. The most frequently cited combinations in the literature include platinum-based chemotherapy with paclitaxel or vinorelbine [25, 31, 35]. In one available case report, RT was combined with systemic treatment consisting of fluorouracil, leucovorin, oxaliplatin, and cetuximab, achieving complete regression [48].

Immune checkpoint blockade has become a therapeutic option for many patients with cancer. Immune checkpoint inhibitors have demonstrated effectiveness in some cancer types. The greater efficacy of immunotherapy refers to tobacco-related cancers, which may be related to the high number of somatic mutations observed in cancer cells, potentially carrying a high mutational load [49]. Tracheal SCC appears to be closely associated with tobacco smoking, in contrast to ACC. In one study, a retrospective review of medical records of

23 patients with primary tracheal tumors was conducted. Available paraffin blocks were immunohistochemically assessed to determine the expression of programmed death-ligand 1 (PD-L1). Among the cases identified were 14 (61%) ACC cases and 4 (17%) SCC cases. PD-L1 expression was observed in 3 (75%) SCC cases, while it was not observed in ACC cases. PD-L1 expression was significantly higher in SCC tumors than in salivary-type tumors ($p = 0.001$) [50]. Two case reports regarded immunotherapy for tracheal SCC. In the first case, recurrent tracheal SCC with PD-L1 expression of 95% was treated with pembrolizumab (200 mg every 3 weeks) for 11 months. Complete remission was achieved in the third month of treatment, with no treatment-related toxicities observed [51]. Another case involved treatment with nivolumab (3 mg/kg every 2 weeks). A follow-up bronchoscopy after 7 months of treatment showed complete regression. The patient experienced a significant improvement in overall condition, reduced dyspnea, and resolution of dysphagia. The patient reported only mild fatigue throughout the treatment period.

Summary

Primary tracheal tumors constitute a rare and relatively poorly understood group of cancers. Due to their rarity, diverse morphology, and clinical presentation, it is challenging to accurately predict the course of the disease. Current literature mainly consists of retrospective analyses and case series. However, in recent years, several larger studies and reviews have expanded our knowledge in this area. Over the past decade, there have been six original studies based on large population databases [3, 21, 24, 28, 52, 53] and ten studies that mostly obtained data from single institutions. These studies predominantly focused on the diagnosis of ACC in the Asian population and included patient groups ranging from 10 to 88 [11, 15, 32, 39–41, 54–57]. In 2019, the first systematic review was published, involving 342 articles and 733 patients with tracheal tumors [7]. In addition to case reports, five Polish original studies from 2022, 2016, 2010, 1998, and 1990 included patient groups of 89, 58, 50, 23, and 15, respectively [15, 20, 22, 33, 58].

Evaluating and comparing these results is challenging due to the rarity and diversity of tracheal tumors. Furthermore, there is a lack of clear criteria for classifying tumors as originating primarily in the trachea, especially in the case of SCC (primary or secondary to previously diagnosed head and neck or lung cancer). Adenoid cystic carcinoma is predominantly located in the trachea, likely due to the distribution of glandular cells in the bronchial tree (the presence of glandular cells decreases in the bronchial tree as the bronchi branch). The incidence of ACC arising in peripheral lung is very low [29]. Squamous cell carcinoma and other histological types are more challenging to diagnose, and careful comparison of radiological documentation with pathological reports is necessary to differentiate between metastatic and primary tracheal involvement. Additionally, some patients may present with 2 or 3 tobacco-related tumors. Clear treatment guidelines for primary tracheal tumors are still lacking. Prognosis for these tumors may depend on several factors. Positive prognostic factors include a histological diagnosis of ACC [3, 6, 14–16, 19–21, 33, 59–63], good overall patient condition [15, 20, 64–66], and radical surgical treatment [6, 7, 10, 14, 20, 40, 59, 62, 67]. Authors have also highlighted the significance of tumor stage and sex [22, 68].

Despite aggressive treatment approaches, reported 5-year survival rates are disappointing. Squamous cell carcinoma of the trachea, in particular, exhibits a very poor prognosis, with average survival rates of around 6 months and 5-year survival rates of approximately 10% [3, 14–16, 20, 62, 63]. However, some studies reported 5-year survival rates as high as 39% and 47% [59, 60]. In contrast, ACC generally has a much better prognosis, with 5-year survival rates ranging from 40.2% to 89.4% and 10-year rates between 29% and 62.3% [3, 15, 19–21, 59–61]. A meta-analysis confirmed significantly better survival for ACC compared to SCC (165 months *vs*. 14 months, respectively; $p < 0.001$) [7]. Despite ongoing improvements in RT and surgical techniques, there has been no significant breakthrough in improving the survival of patients with primary tracheal tumors. Given the rarity and complexity of this disease, patients should be treated in highly specialized centers experienced in managing these rare tumors. Collaboration within multidisciplinary teams, including surgical oncologists, clinical oncologists, radiation therapists, pathologists, and radiologists, is crucial. Additionally, efforts should be made to include patients with primary tracheal tumors in multicenter clinical trials, as their results may form the basis for developing standardized care protocols.

Article Information and Declarations

Author contributions

A.Piórek: writing — original draft preparation; A.Płużański, M.K.: supervision; all authors: conceptualization, writing — review and editing.
All authors have read and agreed to the published version of the manuscript.

Funding

None.

Acknowledgments
None.

Conflict of interest
Authors declare no conflict of interest.

Supplementary material
None.

References

1. Junker K. Pathology of tracheal tumors. Thorac Surg Clin. 2014; 24(1): 7–11, doi: 10.1016/j.thorsurg.2013.09.008, indexed in Pubmed: 24295655.
2. Macchiarini P. Primary tracheal tumours. Lancet Oncol. 2006; 7(1): 83–91, doi: 10.1016/S1470-2045(05)70541-6, indexed in Pubmed: 16389188.
3. Urdaneta AI, Yu JB, Wilson LD. Population based cancer registry analysis of primary tracheal carcinoma. Am J Clin Oncol. 2011; 34(1): 32–37, doi: 10.1097/COC.0b013e3181cae8ab, indexed in Pubmed: 20087156.
4. Honings J, Gaissert HA, Ruangchira-Urai R, et al. Pathologic characteristics of resected squamous cell carcinoma of the trachea: prognostic factors based on an analysis of 59 cases. Virchows Arch. 2009; 455(5): 423–429, doi: 10.1007/s00428-009-0843-6, indexed in Pubmed: 19838727.
5. Madariaga ML, Gaissert HA. Overview of malignant tracheal tumors. Ann Cardiothorac Surg. 2018; 7(2): 244–254, doi: 10.21037/acs.2018.03.04, indexed in Pubmed: 29707502.
6. Webb BD, Walsh GL, Roberts DB, et al. Primary tracheal malignant neoplasms: the University of Texas MD Anderson Cancer Center experience. J Am Coll Surg. 2006; 202(2): 237–246, doi: 10.1016/j.jamcollsurg.2005.09.016, indexed in Pubmed: 16427548.
7. Mallick S, Benson R, Giridhar P, et al. Demography, patterns of care and survival outcomes in patients with malignant tumors of trachea: A systematic review and individual patient data analysis of 733 patients. Lung Cancer. 2019; 132: 87–93, doi: 10.1016/j.lungcan.2019.04.017, indexed in Pubmed: 31097099.
8. Albers E, Lawrie T, Harrell JH, et al. Tracheobronchial adenoid cystic carcinoma: a clinicopathologic study of 14 cases. Chest. 2004; 125(3): 1160–1165, doi: 10.1378/chest.125.3.1160, indexed in Pubmed: 15006985.
9. Wu CC, Shepard JAO. Tracheal and airway neoplasms. Semin Roentgenol. 2013; 48(4): 354–364, doi: 10.1053/j.ro.2013.03.018, indexed in Pubmed: 24034267.
10. Molina JR, Aubry MC, Lewis JE, et al. Primary salivary gland-type lung cancer: spectrum of clinical presentation, histopathologic and prognostic factors. Cancer. 2007; 110(10): 2253–2259, doi: 10.1002/cncr.23048, indexed in Pubmed: 17918258.
11. Zhu F, Liu Z, Hou Y, et al. Primary salivary gland-type lung cancer: clinicopathological analysis of 88 cases from China. J Thorac Oncol. 2013; 8(12): 1578–1584, doi: 10.1097/JTO.0b013e3182a7d272, indexed in Pubmed: 24389442.
12. Togashi Y, Dobashi A, Sakata S, et al. MYB and MYBL1 in adenoid cystic carcinoma: diversity in the mode of genomic rearrangement and transcripts. Mod Pathol. 2018; 31(6): 934–946, doi: 10.1038/s41379-018-0008-8, indexed in Pubmed: 29410490.
13. Honings J, Gaissert HA, Weinberg AC, et al. Prognostic value of pathologic characteristics and resection margins in tracheal adenoid cystic carcinoma. Eur J Cardiothorac Surg. 2010; 37(6): 1438–1444, doi: 10.1016/j.ejcts.2010.01.005, indexed in Pubmed: 20356756.
14. Licht PB, Friis S, Pettersson G. Tracheal cancer in Denmark: a nationwide study. Eur J Cardiothorac Surg. 2001; 19(3): 339–345, doi: 10.1016/s1010-7940(01)00597-8, indexed in Pubmed: 11251276.
15. Napieralska A, Miszczyk L, Blamek S. Tracheal cancer - treatment results, prognostic factors and incidence of other neoplasms. Radiol Oncol. 2016; 50(4): 409–417, doi: 10.1515/raon-2016-0046, indexed in Pubmed: 27904449.
16. Yang KY, Chen YM, Huang MH, et al. Revisit of primary malignant neoplasms of the trachea: clinical characteristics and survival analysis. Jpn J Clin Oncol. 1997; 27(5): 305–309, doi: 10.1093/jjco/27.5.305, indexed in Pubmed: 9390206.
17. Park CM, Goo JMo, Lee HJu, et al. Tumors in the tracheobronchial tree: CT and FDG PET features. Radiographics. 2009; 29(1): 55–71, doi: 10.1148/rg.291085126, indexed in Pubmed: 19168836.
18. Gaissert HA, Mark EJ. Tracheobronchial gland tumors. Cancer Control. 2006; 13(4): 286–294, doi: 10.1177/107327480601300406, indexed in Pubmed: 17075566.
19. Bhattacharyya N. Contemporary staging and prognosis for primary tracheal malignancies: a population-based analysis. Otolaryngol Head Neck Surg. 2004; 131(5): 639–642, doi: 10.1016/j.otohns.2004.05.018, indexed in Pubmed: 15523440.
20. Hetnał M, Kielaszek-Ćmiel A, Wolanin M, et al. Tracheal cancer: Role of radiation therapy. Rep Pract Oncol Radiother. 2010; 15(5): 113–118, doi: 10.1016/j.rpor.2010.08.005, indexed in Pubmed: 24376936.
21. Wen J, Liu Di, Xu X, et al. Nomograms for predicting survival outcomes in patients with primary tracheal tumors: a large population-based analysis. Cancer Manag Res. 2018; 10: 6843–6856, doi: 10.2147/CMAR.S186546, indexed in Pubmed: 30588090.
22. Piórek A, Płużański A, Teterycz P, et al. Do We Need TNM for Tracheal Cancers? Analysis of a Large Retrospective Series of Tracheal Tumors. Cancers (Basel). 2022; 14(7), doi: 10.3390/cancers14071665, indexed in Pubmed: 35406437.
23. Rea F, Zuin A. Tracheal resection and reconstruction for malignant disease. J Thorac Dis. 2016; 8(Suppl 2): S148–152, doi: 10.3978/j.issn.2072-1439.2016.02.04, indexed in Pubmed: 26981265.
24. Wo Y, Li S, Wang Y, et al. Predictors of nodal metastasis and prognostic significance of lymph node ratio and total lymph node count in tracheobronchial adenoid cystic carcinoma. Cancer Manag Res. 2018; 10: 5919–5925, doi: 10.2147/CMAR.S182069, indexed in Pubmed: 30510459.
25. Behringer D, Könemann S, Hecker E. Treatment approaches to primary tracheal cancer. Thorac Surg Clin. 2014; 24(1): 73–76, doi: 10.1016/j.thorsurg.2013.10.002, indexed in Pubmed: 24295662.
26. W S, M W, M P. Management of laryngotracheal stenosis. Kardiochir Torakochirurgia Pol. 2009; 6: 157–165.
27. Pawlewicz K, Szutkowski Z, Kawecki A. Recurrence of adenoid cystic carcinoma of the trachea treated with radical radiotherapy: A case report. Oncol Lett. 2018; 15(3): 3890–3894, doi: 10.3892/ol.2018.7780, indexed in Pubmed: 29456738.
28. Xie L, Fan M, Sheets NC, et al. The use of radiation therapy appears to improve outcome in patients with malignant primary tracheal tumors: a SEER-based analysis. Int J Radiat Oncol Biol Phys. 2012; 84(2): 464–470, doi: 10.1016/j.ijrobp.2011.12.011, indexed in Pubmed: 22365629.
29. Shimizu J, Oda M, Matsumoto I, et al. Clinicopathological study of surgically treated cases of tracheobronchial adenoid cystic carcinoma. Gen Thorac Cardiovasc Surg. 2010; 58(2): 82–86, doi: 10.1007/s11748-009-0467-4, indexed in Pubmed: 20155344.
30. Honings J, Gaissert HA, Verhagen AdF, et al. Undertreatment of tracheal carcinoma: multidisciplinary audit of epidemiologic data. Ann Surg Oncol. 2009; 16(2): 246–253, doi: 10.1245/s10434-008-0241-3, indexed in Pubmed: 19037701.
31. Joshi N, Mallick S, Haresh KP, et al. Modern chemoradiation practices for malignant tumors of the trachea: An institutional experience. Indian J Cancer. 2014; 51(3): 241–244, doi: 10.4103/0019-509X.146743, indexed in Pubmed: 25494113.
32. Högerle BA, Lasitschka F, Muley T, et al. Primary adenoid cystic carcinoma of the trachea: clinical outcome of 38 patients after interdisciplinary treatment in a single institution. Radiat Oncol. 2019; 14(1): 117, doi: 10.1186/s13014-019-1323-z, indexed in Pubmed: 31272473.
33. Makarewicz R, Mross M. Radiation therapy alone in the treatment of tumours of the trachea. Lung Cancer. 1998; 20(3): 169–174, doi: 10.1016/s0169-5002(98)00018-x, indexed in Pubmed: 9733051.
34. Allen AM, Rabin MS, Reilly JJ, et al. Unresectable adenoid cystic carcinoma of the trachea treated with chemoradiation. J Clin Oncol. 2007; 25(34): 5521–5523, doi: 10.1200/JCO.2007.13.7273, indexed in Pubmed: 18048830.
35. Joshi NP, Haresh KP, Das P, et al. Unresectable basaloid squamous cell carcinoma of the trachea treated with concurrent chemoradiotherapy: a case report with review of literature. J Cancer Res Ther. 2010; 6(3): 321–323, doi: 10.4103/0973-1482.73341, indexed in Pubmed: 21119264.
36. Haddad RI, Posner MR, Busse PM, et al. Chemoradiotherapy for adenoid cystic carcinoma: preliminary results of an organ sparing approach. Am J Clin Oncol. 2006; 29(2): 153–157, doi: 10.1097/01.coc.0000203756.36866.17, indexed in Pubmed: 16601434.
37. Videtic GMM, Campbell C, Vincent MD. Primary chemoradiation as definitive treatment for unresectable cancer of the trachea. Can Respir J. 2003; 10(3): 143–144, doi: 10.1155/2003/382026, indexed in Pubmed: 12712222.
38. Papaspyrou G, Hoch S, Rinaldo A, et al. Chemotherapy and targeted therapy in adenoid cystic carcinoma of the head and neck: a review. Head Neck. 2011; 33(6): 905–911, doi: 10.1002/hed.21458, indexed in Pubmed: 20652885.
39. Yang H, Yao F, Tantai J, et al. Resected Tracheal Adenoid Cystic Carcinoma: Improvements in Outcome at a Single Institution. Ann Thorac

Surg. 2016; 101(1): 294–300, doi: 10.1016/j.athoracsur.2015.06.073, indexed in Pubmed: 26431923.
40. Lee JH, Jung EJ, Jeon K, et al. Treatment outcomes of patients with adenoid cystic carcinoma of the airway. Lung Cancer. 2011; 72(2): 244–249, doi: 10.1016/j.lungcan.2010.08.011, indexed in Pubmed: 20828861.
41. Hu MM, Hu Y, He JB, et al. Primary adenoid cystic carcinoma of the lung: Clinicopathological features, treatment and results. Oncol Lett. 2015; 9(3): 1475–1481, doi: 10.3892/ol.2015.2859, indexed in Pubmed: 25663934.
42. Laurie SA, Ho AL, Fury MG, et al. Systemic therapy in the management of metastatic or locally recurrent adenoid cystic carcinoma of the salivary glands: a systematic review. Lancet Oncol. 2011; 12(8): 815–824, doi: 10.1016/S1470-2045(10)70245-X, indexed in Pubmed: 21147032.
43. Chahal M, Pleasance E, Grewal J, et al. Personalized oncogenomic analysis of metastatic adenoid cystic carcinoma: using whole-genome sequencing to inform clinical decision-making. Cold Spring Harb Mol Case Stud. 2018; 4(2), doi: 10.1101/mcs.a002626, indexed in Pubmed: 29610392.
44. Wagner VP, Ferrarotto R, Vargas PA, et al. Drug-based therapy for advanced adenoid cystic carcinoma: Current landscape and challenges based on an overview of registered clinical trials. Crit Rev Oncol Hematol. 2023; 181: 103886, doi: 10.1016/j.critrevonc.2022.103886, indexed in Pubmed: 36427771.
45. Dewenter I, Otto S, Kakoschke TK, et al. Recent Advances, Systemic Therapy, and Molecular Targets in Adenoid Cystic Carcinoma of the Head and Neck. J Clin Med. 2023; 12(4), doi: 10.3390/jcm12041463, indexed in Pubmed: 36835997.
46. Kacew AJ, Hanna GJ. Systemic and Targeted Therapies in Adenoid Cystic Carcinoma. Curr Treat Options Oncol. 2023; 24(1): 45–60, doi: 10.1007/s11864-022-01043-2, indexed in Pubmed: 36637743.
47. Thierauf J, Ramamurthy N, Jo VY, et al. Clinically Integrated Molecular Diagnostics in Adenoid Cystic Carcinoma. Oncologist. 2019; 24(10): 1356–1367, doi: 10.1634/theoncologist.2018-0515, indexed in Pubmed: 30926674.
48. Papadopoulou A, Froudarakis M, Abatzoglou I, et al. Tracheal cancer treated with a short course of external and endoluminal radio-chemotherapy combined with cetuximab - a case report. J Contemp Brachytherapy. 2010; 2(4): 160–162, doi: 10.5114/jcb.2010.19496, indexed in Pubmed: 27853478.
49. Osho AA, Azzoli CJ, Pai S, et al. Successful Treatment of an Aggressive Tracheal Malignancy With Immunotherapy. Ann Thorac Surg. 2017; 103(2): e123–e125, doi: 10.1016/j.athoracsur.2016.08.021, indexed in Pubmed: 28109369.
50. Tapias LF, Shih A, Mino-Kenudson M, et al. Programmed death ligand 1 and CD8+ immune cell infiltrates in resected primary tracheal malignant neoplasms. Eur J Cardiothorac Surg. 2019; 55(4): 691–698, doi: 10.1093/ejcts/ezy370, indexed in Pubmed: 30418532.
51. Maller B, Kaszuba F, Tanvetyanon T. Complete Tumor Response of Tracheal Squamous Cell Carcinoma After Treatment With Pembrolizumab. Ann Thorac Surg. 2019; 107(4): e273–e274, doi: 10.1016/j.athoracsur.2018.08.067, indexed in Pubmed: 30326234.
52. Nouraei SM, Middleton SE, Nouraei SA, et al. Management and prognosis of primary tracheal cancer: a national analysis. Laryngoscope. 2014; 124(1): 145–150, doi: 10.1002/lary.24123, indexed in Pubmed: 23868448.
53. Benissan-Messan DZ, Merritt RE, Bazan JG, et al. National Utilization of Surgery and Outcomes for Primary Tracheal Cancer in the United States. Ann Thorac Surg. 2020; 110(3): 1012–1022, doi: 10.1016/j.athoracsur.2020.03.048, indexed in Pubmed: 32335015.
54. Huo Z, Meng Y, Wu H, et al. Adenoid cystic carcinoma of the tracheobronchial tree: clinicopathologic and immunohistochemical studies of 21 cases. Int J Clin Exp Pathol. 2014; 7(11): 7527–7535, indexed in Pubmed: 25550788.
55. Chen F, Huang M, Xu Y, et al. Primary tracheal adenoid cystic carcinoma: adjuvant treatment outcome. Int J Clin Oncol. 2015; 20(4): 686–692, doi: 10.1007/s10147-014-0771-6, indexed in Pubmed: 25412605.
56. Je HUk, Song SiY, Kim DK, et al. A 10-year clinical outcome of radiotherapy as an adjuvant or definitive treatment for primary tracheal adenoid cystic carcinoma. Radiat Oncol. 2017; 12(1): 196, doi: 10.1186/s13014-017-0933-6, indexed in Pubmed: 29202770.
57. Koul R, Alomrann R, Rathod S, et al. Clinical Characteristics and Prognosis of Primary Tracheal Cancer: A Single Institution Experience. Int J Hematol Oncol Stem Cell Res. 2018; 12: 298–302, doi: 10.18502/ijhoscr.v12i4.108.
58. Rosset A, Korzeniowski S. [Effectiveness of radiotherapy in patients with cancer of the trachea]. Nowotwory. 1990; 40(3): 207–213, indexed in Pubmed: 2123033.
59. Gaissert HA, Grillo HC, Shadmehr MB, et al. Long-term survival after resection of primary adenoid cystic and squamous cell carcinoma of the trachea and carina. Ann Thorac Surg. 2004; 78(6): 1889–96; discussion 1896, doi: 10.1016/j.athoracsur.2004.05.064, indexed in Pubmed: 15560996.
60. Regnard JF, Fourquier P, Levasseur P. Results and prognostic factors in resections of primary tracheal tumors: a multicenter retrospective study. The French Society of Cardiovascular Surgery. J Thorac Cardiovasc Surg. 1996; 111(4): 808–13; discussion 813, doi: 10.1016/s0022-5223(96)70341-0, indexed in Pubmed: 8614141.
61. Zhengjaiang L, Pingzhang T, Dechao Z, et al. Primary tracheal tumours: 21 years of experience at Peking Union Medical College, Beijing, China. J Laryngol Otol. 2008; 122(11): 1235–1240, doi: 10.1017/S0022215108001710, indexed in Pubmed: 18331654.
62. Honings J, van Dijck JA, Verhagen AdF, et al. Incidence and treatment of tracheal cancer: a nationwide study in the Netherlands. Ann Surg Oncol. 2007; 14(2): 968–976, doi: 10.1245/s10434-006-9229-z, indexed in Pubmed: 17139460.
63. Manninen MP, Pukander JS, Flander MK, et al. Treatment of primary tracheal carcinoma in Finland in 1967-1985. Acta Oncol. 1993; 32(3): 277–282, doi: 10.3109/02841869309093595, indexed in Pubmed: 8323765.
64. Chao MW, Smith JG, Laidlaw C, et al. Results of treating primary tumors of the trachea with radiotherapy. Int J Radiat Oncol Biol Phys. 1998; 41(4): 779–785, doi: 10.1016/s0360-3016(98)00120-5, indexed in Pubmed: 9652838.
65. Jeremic B, Shibamoto Y, Acimovic L, et al. Radiotherapy for primary squamous cell carcinoma of the trachea. Radiother Oncol. 1996; 41(2): 135–138, doi: 10.1016/s0167-8140(96)01797-5, indexed in Pubmed: 9004356.
66. Mornex F, Coquard R, Danhier S, et al. Role of radiation therapy in the treatment of primary tracheal carcinoma. Int J Radiat Oncol Biol Phys. 1998; 41(2): 299–305, doi: 10.1016/s0360-3016(98)00073-x, indexed in Pubmed: 9607345.
67. Agulnik M, Cohen EWE, Cohen RB, et al. Phase II study of lapatinib in recurrent or metastatic epidermal growth factor receptor and/or erbB2 expressing adenoid cystic carcinoma and non adenoid cystic carcinoma malignant tumors of the salivary glands. J Clin Oncol. 2007; 25(25): 3978–3984, doi: 10.1200/JCO.2007.11.8612, indexed in Pubmed: 17761983.
68. Piórek A, Płużański A, Kowalski D, et al. Prognostic significance of sex in patients with primary tracheal tumors – a retrospective, single-center study. Nowotwory. Journal of Oncology. 2022; 72(1): 11–15, doi: 10.5603/njo.a2021.0069.

VIA MEDICA

CASE REPORT

Kenneth Grenis Vargas Ponce[1], Claudia Meléndez Dávila[1], Juan Antonio Salas Lopez[1], Félix Llanos Tejada[1, 2]

[1]Pulmonary service, Hospital Nacional Dos de Mayo, Lima, Peru
[2]Facultad de Medicina, Instituto de Investigaciones en Ciencias Biomédicas — INICIB, Universidad Ricardo Palma, Lima, Peru

Pulmonary tuberculosis as a differential diagnosis of a pulmonary nodule: the great masquerader

Address for correspondence:
Dr. Félix Llanos Tejada
Facultad de Medicina, Instituto de Investigaciones en Ciencias Biomédicas — INICIB, Universidad Ricardo Palma, Av. Benavides 5500, Santiago de Surco, Lima 33, Peru
e-mail: neumofekollate@aol.com

Oncology in Clinical Practice
DOI: 10.5603/OCP.2023.0045
Copyright © 2024 Via Medica
ISSN 2450–1654
e-ISSN 2450–6478

ABSTRACT

Tuberculosis is known as one of "the great masqueraders" due to unusual and nonspecific symptoms it presents, which causes a challenge in diagnosis. There are rare radiological pulmonary patterns described in some case reports such as lung mass and bilateral pulmonary nodules similar to primary lung cancer or pulmonary metastases. We present a case of a 42-year-old man who was admitted to the emergency room due to pain and increased testicular volume. His chest tomography revealed a right lung mass and bilateral pulmonary nodules with a diffuse distribution. Therefore, based on clinical and radiological results, we suspected malignancy. His testicular fluid drainage resulted in a positive Ziehl Neelsen staining. The patient received anti-tuberculosis treatment for 1 month showing clinical and tomographic improvement.

Pulmonary tuberculosis can present unusual radiological patterns. Therefore, we suggest that it should be considered in the differential diagnosis of patients with clinical and radiological characteristics of metastatic or primary lung disease. Diagnosis should be aided by invasive interventions.

Keywords: lung mass, male genital tuberculosis, mimics, pulmonary nodule, pulmonary tuberculosis

Oncol Clin Pract 2024; 20, 1: 60–63

Introduction

Tuberculosis (TB) is a public health problem. The World Health Organization (WHO) reported that in 2018 around 10 million people became ill with TB and 1.2 million died, making TB the main cause of death by infection in the world [1]. In Peru, 42 940 TB cases were reported in 2019, which ranked TB eleventh among the causes of death in the general population [2]. Pulmonary TB (PTB) represents 70% of TB cases, from where it can spread to any other organ, with extrapulmonary form reported in 18% of cases. Genital TB is rare, and testicular TB is even rarer, comprising only 3% of genital TB [3, 4].

Pulmonary presentations of TB can be easily diagnosed, but sometimes they have unusual presentations. PTB is known as "a great masquerader" that causes difficulties in diagnosis. The radiological manifestations of PTB are well-known and documented; however, it can have atypical radiological patterns that can be confused with lung malignancies in 3.5% to 4.5% of cases [5].

We present a case of a patient with clinical and radiological evidence suggesting metastatic lung cancer and with the final diagnosis of pulmonary and testicular tuberculosis.

Case report

A 42-year-old male patient, with no pathological history of interest, was admitted to the Emergency Room of the "Dos de Mayo" National Hospital for worsening testicular pain, increased volume in the right testicle,

Received: 13.06.2023 Accepted: 16.07.2023 Early publication date: 28.08.2023

This article is available in open access under Creative Common Attribution-Non-Commercial-No Derivatives 4.0 International (CC BY-NC-ND 4.0) license, allowing to download articles and share them with others as long as they credit the authors and the publisher, but without permission to change them in any way or use them commercially.

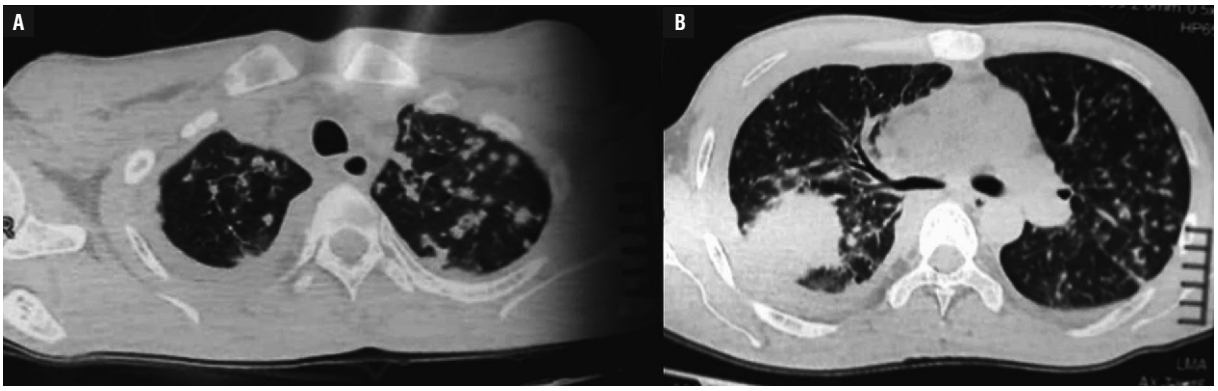

Figure 1. A. Chest computed tomography showing multiple bilateral diffuse pulmonary nodules; **B.** Lung mass with irregular borders in S6 and adjacent pleural effusion, in addition to the presence of nodules

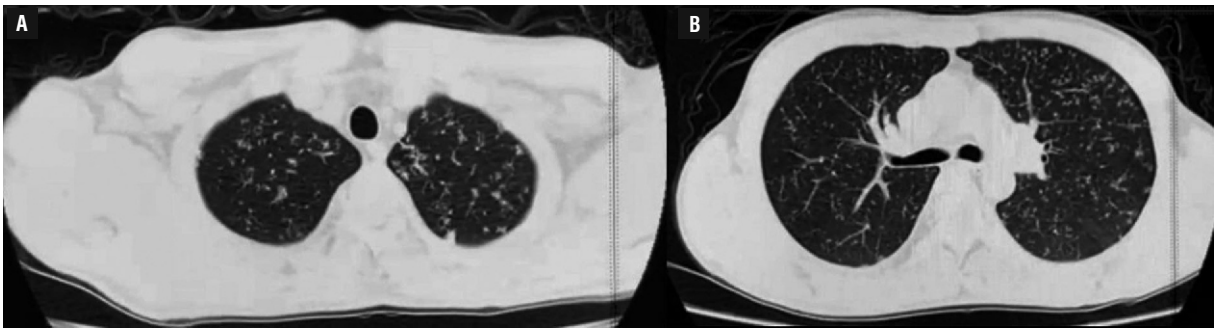

Figure 2A–B. Chest computed tomography performed after one month of treatment. Pictures A and B showing sections equivalent to Figure 1, where improvement of the lesions is observed

and weight loss. He was previously treated in a primary care center where levofloxacin was administered without achieving improvement.

The vital functions on admission were a heart rate of 78 beats per minute, respiratory rate of 20 breaths per minute, oxygen saturation of 92% (FiO_2 21%), and temperature of 37°C. The clinical examination found abolished vesicular murmur in the lower third of the right hemithorax, and, there was a palpable hard mass in the right testicle without signs of inflammation. The rest of the evaluation was normal.

Blood parameters showed normal white blood cell count (7080 cells/cm^3), mild anemia (hemoglobin of 9.50 mg/dL), normal serum creatinine levels (0.90 mg/dL), D-dimer of 11.28 mg/dL, lactate dehydrogenase (LDH) of 270 U/L, Alpha-fetoprotein level was 2.31 IU/mL and beta HCG was less than 2.30 mIU/mL. He tested negative for SARS-CoV-2, human immunodeficiency virus (HIV), and other tumor markers. Ultrasonography revealed the presence of a solid heterogeneous tumor measuring approximately 42 × 35 × 35 mm and signs of infiltration of the regional peritesticular layers, extending to the subcutaneous plane of the scrotum. A Doppler study showed little internal flow. Other findings included small cysts measuring less than 5 mm in both epididymis.

Chest computed tomography showed a defined mass with heterogeneous density, pleural effusion, multiple nodules in the right lung, a slight left pleural effusion, and nodules in the left lung as well (Fig. 1). During hospitalization, diagnostic thoracentesis was performed that evidenced a predominantly mononuclear exudate, LDH of 320 U/L, adenosine deaminase (ADA) value was 59.47 U/L, and cell block preparation and Pap smear were both negative for neoplasia.

Additionally, testicular fluid drainage was performed, obtaining a positive Ziehl Neelsen staining (paucibacillary tuberculosis), for which an anti-tuberculosis treatment regime with first-line drugs was started with isoniazid (H) 300 mg/d, rifampicin (R) 600 mg/d, ethambutol (E) 1200 mg/d, and pyrazinamide (Z) 1500 mg/d. Afterward, the patient was discharged. After one month of treatment, he was reevaluated and showed clinical and tomographic improvement (Fig. 2).

Discussion

The clinical presentation of pulmonary tuberculosis is easy to diagnose; however, its radiological presentation often simulates other diseases. In this situation, it is necessary to consider other diagnoses and perform invasive procedures to confirm a diagnosis.

The PTB symptoms are often nonspecific, or patients can be asymptomatic in up to 5% of cases. Moreover, symptoms such as cough, hemoptysis, and weight loss can resemble the symptoms of lung cancer [6].

In the presented case, the patient did not report any respiratory symptoms, only weight loss and increased volume at the right scrotal area, which at first supported the diagnosis of malignancy. Isolated cases of testicular tuberculosis have been reported, whose most frequent presentation is painless scrotal edema, with or without discharge, and the palpation of a hard mass that can be often confused with testicular cancer. Thus, finding a hard testicular mass in patients over 60 years can arise testicular cancer suspicion. Nevertheless, in patients between 20 and 40 years of age, testicular tuberculosis as a differential diagnosis should be considered [7, 8].

The common radiological manifestations of PTB are well described in the literature; however, there are unusual patterns that can delay diagnosis and treatment. In areas where tuberculosis is endemic, we suggest that it should be considered in the differential diagnosis of malignancy [4]. Unusual manifestations of PTB occur in up to 6% of cases, and they are characterized by the presence of a solitary nodule that simulates lung cancer [5]. This is called pseudotumoral pulmonary tuberculosis because a small proportion of benign lung masses may present spiculated margins, while about 20% of primary lung cancers can show well-defined margins. In some cases, the diagnosis was based on a therapeutic test showing a spectacular tomographic improvement after receiving anti-tuberculosis treatment [5, 9].

There is a variety of causes associated with bilateral pulmonary nodules, the most frequent being metastatic, as reported in a review in patients aged from 30 to 55 years, where 67% of the pulmonary nodules were metastases frequently secondary to testicular carcinoma [10]. However, another reported unusual PTB manifestation is the presence of multiple bilateral nodules. Despite suggested parameters to differentiate multiple pulmonary nodules related to TB from metastatic ones, they are not definitive [11–13]. In those cases, pulmonary tuberculosis should be considered in the differential diagnosis of multiple pulmonary nodules, which makes performing invasive interventions necessary.

Another tomographic finding described in this case was the presence of pleural effusion. This entity can be seen in 15% of patients with neoplastic diseases and 40% of cases of extrapulmonary TB. Malignancy and tuberculosis are the two main causes of exudative pleural effusion, representing approximately 50% of all exudates [14]. Both entities have similar biochemical profiles, and it can be difficult to distinguish between them. It has been mentioned that a high level of ADA in the pleural fluid can be useful for differential diagnosis, with sensitivity of 92% and specificity of 90% for tuberculous pleurisy. By contrast, elevated levels of LDH in the pleural fluid of over 722 U/L are more common for malignant etiology [15]. In the reported case, there were elevated levels of ADA concordant with TB, whereas LDH levels were not as high as described in the cases of neoplastic etiology; thus, these results supported the diagnosis of pleural tuberculosis.

Conclusions

Pulmonary tuberculosis is one of "the great masqueraders", and it can present unusual radiological patterns. We suggest that it should be considered in the differential diagnosis of patients with clinical and radiological suspicion of metastatic or primary lung neoplasia and that diagnosis should be assisted by invasive procedures.

Article Information and Declarations

Ethics statement
Patient informed consent.

Author contributions
All authors have contributed to the conception and realization of the report.

Funding
None.

Acknowledgments
To the pulmonology service of the Dos de Mayo National Hospital.

Conflict of interest
None.

Supplementary material
None.

References

1. OMS. Tuberculosis [Internet]. https://www.who.int/westernpacific/health-topics/tuberculosis (02.07.2020).
2. REUNIS: Repositorio Único Nacional de Información en Salud - Ministerio de Salud [Internet]. http://www.minsa.gob.pe/reunis/index.asp?op=5 (02.07.2020).

3. Ketata W, Rekik WK, Ayadi H, et al. Les tuberculoses extrapulmonaires. Revue de Pneumologie Clinique. 2015; 71(2-3): 83–92, doi: 10.1016/j.pneumo.2014.04.001.
4. Villena-suarez JR, Vicente W, Taxa L, et al. Tuberculosis that mimics cancer: cases referred to the National Institute of Neoplastic Diseases, Lima-Peru. Rev Perú Med Exp Salud publica. 2018; 35(1): 77–83.
5. Afriyie-Mensah JS, Awindaogo FR, Asomani SK. Pseudotumour presentation of pulmonary tuberculosis. Ghana Med J. 2020; 54(2): 126–130, doi: 10.4314/gmj.v54i2.12, indexed in Pubmed: 33536684.
6. Lang S, Sun J, Wang X, et al. Asymptomatic pulmonary tuberculosis mimicking lung cancer on imaging: A retrospective study. Exp Ther Med. 2017; 14(3): 2180–2188, doi: 10.3892/etm.2017.4737, indexed in Pubmed: 28962139.
7. Shugaba AI, Rabiu AM, Uzokwe C, et al. Tuberculosis of the testis: a case report. Clin Med Insights Case Rep. 2012; 5: 169–172, doi: 10.4137/CCRep.S9451, indexed in Pubmed: 23300353.
8. Das A, Batabyal S, Bhattacharjee S, et al. A rare case of isolated testicular tuberculosis and review of literature. J Family Med Prim Care. 2016; 5(2): 468–470, doi: 10.4103/2249-4863.192334, indexed in Pubmed: 27843865.
9. Agarwal R, Srinivas R, Aggarwal AN. Parenchymal pseudotumoral tuberculosis: case series and systematic review of literature. Respir Med. 2008; 102(3): 382–389, doi: 10.1016/j.rmed.2007.10.017, indexed in Pubmed: 18060757.
10. Davis SD. CT evaluation for pulmonary metastases in patients with extrathoracic malignancy. Radiology. 1991; 180(1): 1–12, doi: 10.1148/radiology.180.1.2052672, indexed in Pubmed: 2052672.
11. Pilaniya V, Gera K, Kunal S, et al. Pulmonary tuberculosis masquerading as metastatic lung disease. Eur Respir Rev. 2016; 25(139): 97–98, doi: 10.1183/16000617.00002315, indexed in Pubmed: 26929427.
12. Ariyürek MO, Karçaaltincaba M, Demirkazik FB, et al. Bilateral multiple pulmonary tuberculous nodules mimicking metastatic disease. Eur J Radiol. 2002; 44(1): 33–36, doi: 10.1016/s0720-048x(01)00402-8, indexed in Pubmed: 12350408.
13. Nowakowska-Arendt A, Jagiełło G. Pulmonary tuberculosis mimicking numerous lung metastases — a case study. Med Res J. 2018; 3(1): 43–46, doi: 10.5603/mrj.2018.0008.
14. Shaw JA, Irusen EM, Diacon AH, et al. Pleural tuberculosis: A concise clinical review. Clin Respir J. 2018; 12(5): 1779–1786, doi: 10.1111/crj.12900, indexed in Pubmed: 29660258.
15. Darooei R, Sanadgol G, Gh-Nataj A, et al. Discriminating Tuberculous Pleural Effusion from Malignant Pleural Effusion Based on Routine Pleural Fluid Biomarkers, Using Mathematical Methods. Tanaffos. 2017; 16(2): 157–165, indexed in Pubmed: 29308081.

Chi Truong Nguyen[1], Ngoc Hieu Nguyen[2, 3], Van Nguyen Huong[4], Ngoc Tran Pham[1], Thai Chan Nguyen[1]

[1]Department Of General Surgery, Quang Ngai Provincial General Hospital, Quang Ngai, Vietnam
[2]Faculty of Environmental and Natural Sciences, Duy Tan University, Da Nang, Vietnam
[3]Institute for Research and Training in Medicine, Biology and Pharmacy, Duy Tan University, Da Nang, Vietnam
[4]Medical Laboratory Technology, Nguyen Tat Thanh University, Ho Chi Minh, Vietnam

A rare case report on bilateral scrotal lipoma — the largest tumor in Vietnam

Address for correspondence:
Master Ngoc Hieu Nguyen
Faculty of Environmental and Natural Sciences, Duy Tan University, Da Nang, 550000, Vietnam;
Institute for Research and Training in Medicine, Biology and Pharmacy, Duy Tan University, Da Nang, 550000, Vietnam
e-mail: nguyenngochieu10@dtu.edu.vn

Oncology in Clinical Practice
DOI: 10.5603/ocp.96055
Copyright © 2024 Via Medica
ISSN 2450–1654
e-ISSN 2450–6478

ABSTRACT

Scrotal lipoma is benign and still, one of the rarest cancers, with very few cases previously reported in the world. The exact pathogenesis of lipomas remains unknown. Scrotal lipomas can be classified into three categories based on their origins: scrotal lipoma, spermatic cord and tunica vaginalis tumor, and primary scrotal lipoma. The disease may be misdiagnosed or diagnosed inaccurately. We present a case of a 46-year-old male with a giant bilateral scrotal lipoma presenting as scrotal swelling and discomfort, which was first diagnosed as an inguinal hernia. Computed tomography, ultrasound, and fine needle aspiration were performed and aroused a suspicion of lipoma. An operation was performed, and the tumor was completely excised and histologically confirmed as a lipoma. To our knowledge, this is the largest scrotal tumor reported in Vietnam, which led to not only diagnostic but also treatment challenges. Therefore, it is significant to report similar cases that can help clinicians diagnose and handle such tumors in a timely manner.

Keywords: liposarcoma, inguinal hernia, scrotal lipoma, tumor

Oncol Clin Pract 2024; 20, 1: 64–67

Introduction

Lipomas are one of the most common benign mesenchymal tumors, and they vary in size. When the diameter of a lipoma is at least 10 cm, it is considered a giant lipoma [1]. A giant scrotal lipoma is a rare manifestation so making a correct diagnosis is challenging [2, 3]. Radiological examination has an important role in preoperative diagnosis and surgical planning [4]. Surgical resection is the best treatment of scrotal lipoma and postoperative pathologic diagnosis is necessary [5, 6]. Here, we report a rare case of a 46-year-old male patient with a giant lipoma in the bilateral scrotum measuring 30 × 10 cm.

Case presentation

A 46-year-old male presented with a rapid scrotal enlargement over a period of 3 months. Earlier, the patient's clinical presentation appeared to a bilateral inguinal hernia. At that time, he refused any treatment. However, in the following 3 months, both sides of his scrotum rapidly enlarged. The patient reported no associated symptoms. He had no history of surgery, scrotal trauma, tuberculosis, or other relevant diseases and denied any family history.

On examination, double 30 × 10 cm, slightly moveable, solid masses were palpated in the scrotum. They were painless, lobulated, and had no skin changes or

Received: 15.06.2023 Accepted: 14.08.2023 Early publication date: 31.08.2023

This article is available in open access under Creative Common Attribution-Non-Commercial-No Derivatives 4.0 International (CC BY-NC-ND 4.0) license, allowing to download articles and share them with others as long as they credit the authors and the publisher, but without permission to change them in any way or use them commercially.

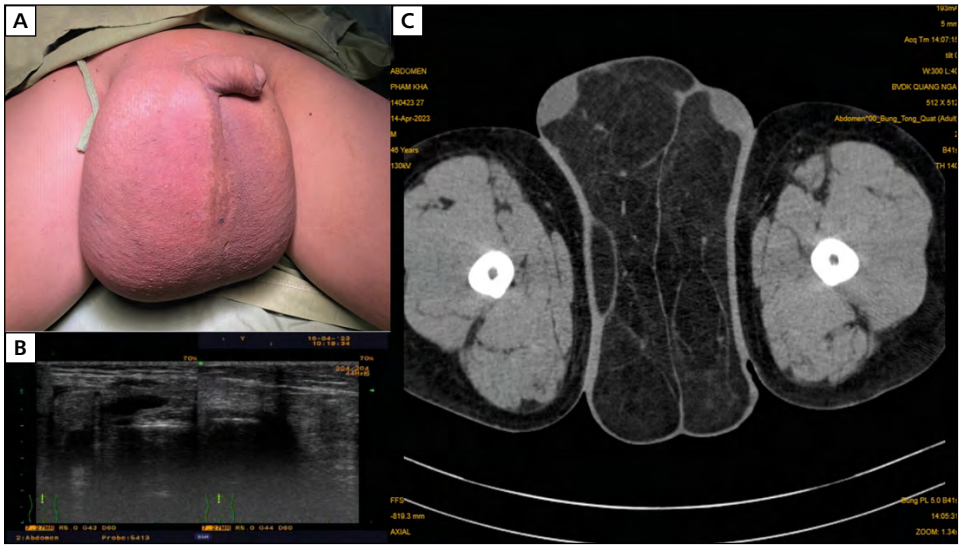

Figure 1. Clinical aspect, ultrasound and computed tomography (CT) images of the tumor; **A.** Visible scrotal mass; **B.** Ultrasonography showed a slightly higher echogenic mass; **C.** CT scan revealed multilobulated fatty mass in the scrotum

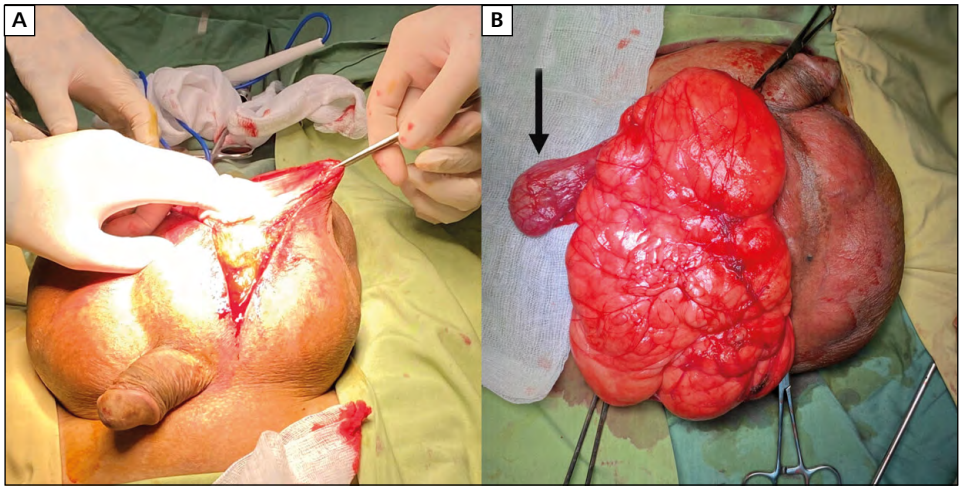

Figure 2. Scrotal exposure and operative picture; **A.** Longitudinal incision on the right hemiscrotum; **B.** Multilobulated fatty lipomas that squeezed the testis; black arrow — right testis

negative light transmission test. No testes and spermatic cords were palpated (Fig. 1A).

Complete blood count (CBC), human chorionic gonadotropin (HCG), and alpha-fetoprotein were normal. A scrotal ultrasound examination revealed a giant extra-testicular homogenous echotexture of fat (Fig. 1B). Computed tomography showed a multilobulated fatty mass in the scrotum suggestive of a lipoma (Fig. 1C). A fine needle aspiration (FNA) was performed and showed mature adipocytes.

The patient was counseled and subsequently underwent open lipoma excision under endotracheal anesthesia. Longitudinal incisions on the right and left hemiscrotum were made to expose the tumors (Fig. 2A). The multilobulated fatty lipomas that squeezed the bilateral testes and spermatic cord were isolated and excised (Fig. 2B). Excess skin was removed. Wounds were closed in layers with 2.0 vicryl sutures, and skin was closed with 3.0 vicryl sutures. The patient recovered well without complications and was discharged from the hospital one week later.

The postoperative excised mass was sent for testing. Macroscopic examination reported two light yellow defined tumors with slight fibrous capsules. The measurements were 33 × 12 × 4 cm and 9 × 28 × 4 cm and weighed 2300 g (Fig. 3A). Microscopically, the tumor was composed of matured adipocytes of typically uniform size arranged in lobules separated by fibrous

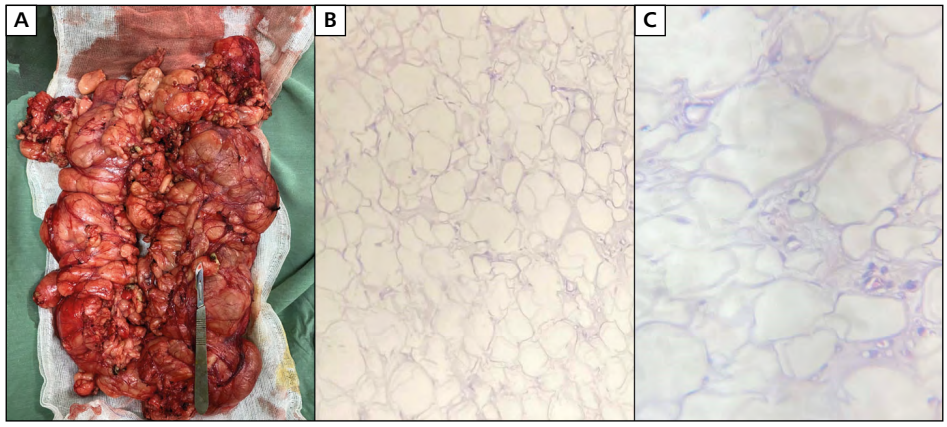

Figure 3. Pathological examination; **A.** Macroscopic examination; **B.** Matured adipocytes arranged in lobules surrounded by fibrous membranes (HE-stained section); **C.** Matured adipocytes

membranes (Fig. 3B, 3C). Based on pathologic and immunohistochemistry results, the tumor was diagnosed as a giant bilateral scrotal lipoma (Fig. 4).

Discussion

Lipomas are mesenchymal tumors that are composed of fat tissue [7]. They are typically painless, mobile, and palpable under the skin. They can arise in any part of the body, but the scrotum is still a rare location, especially a giant scrotal lipoma. The exact pathogenesis of lipoma remains unknown. Nonetheless, trauma and cytogenetic mutations have been hypothesized as causes [7–9]. Approximately, 55–75% of solitary lipomas have cytogenetic abnormalities involving *HMGA2* gene rearrangements [10].

Diagnosis of scrotal lipoma can be difficult because of similar clinical presentations with such conditions as hydrocele, varicocele, or inguinoscrotal hernia [11]. Liposarcoma should be considered in patients with rapidly growing or giant tumors [12]. A giant lipoma is defined as a lesion that measures at least 10 cm in one dimension or weighs a minimum of 1000 g [1]. Early diagnosis and treatment can significantly improve the prognosis.

Histopathology is the gold standard for diagnosing lipoma, and consequently excised mass should be well examined by a pathologist. Lipomas are composed of adipose and are surrounded by a thin, fibrous capsule that is not attached to the underlying muscle fascia [7]. In their atypical form, they present a diagnostic challenge. Genetic testing to rule out liposarcoma after tumor resection should be performed. Surgical excision has been the mainstay treatment for scrotal lipoma. However, reduction surgery may be chosen in difficult cases or to alleviate the patient's symptoms. Guidelines do not recommend prolonged follow-up given the rarity of the disease [13]. However, long-term follow-up is necessary in the case of reductive surgery or suspicion that a lipoma can recur.

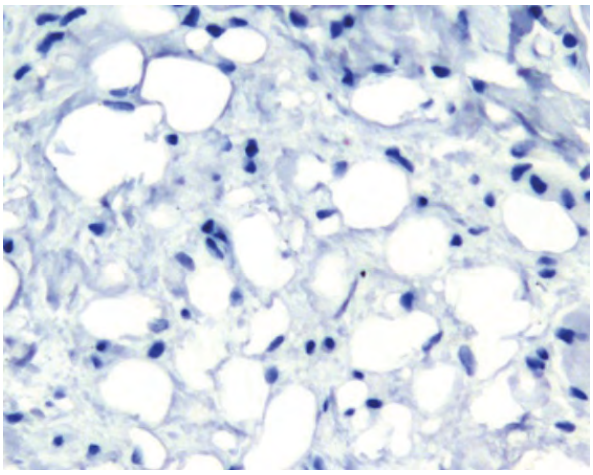

Figure 4. CDK4 immunohistochemistry staining. CDK4 is positive in the majority of lipomas

The scrotal lipoma in our patient extended superiorly into the inguinal canal, inferiorly to the perineum and external anal sphincter muscle, so a long longitudinal incision was made to expose the tumor better. The tumor grew rapidly (over 30 cm in 3 months), so liposarcoma was suspected. Postoperatively, a pathologic examination revealed a typical lipoma. The patient was discharged one week after the operation and followed up in an outpatient clinic.

Conclusions

Scrotal lipoma is uncommon, and it may look like an inguinal hernia. Whenever lipoma is diagnosed, entry excision should be performed and sent for

histopathological examination to rule out atypical features or malignancy. Lipoma patients can relapse even after several years.

Article Information and Declarations

Ethics

The authors are accountable for all aspects of the work in ensuring that questions related to the accuracy or integrity of any part of the work are appropriately investigated and resolved. All procedures performed in studies involving human participants were in accordance with the ethical standards of the Ethics committee on biomedical research, Quang Ngai provincial general hospital , Quang Ngai, Vietnam. Written informed consent was obtained from the patient.

Author contributions

C.T.N.: diagnose and surgery, writing original draft, writing-review and editing; N.H.N.: writing original draft, writing-review and editing; V.N.H.: writing-review and editing; N.T.P.: diagnose and surgery, writing original draft; T.C.N.: diagnose and surgery, writing original draft.

All authors have read and agreed to the published version of the manuscript.

Funding

None.

Acknowledgments

We thank the support of the Department of General Surgery, Quang Ngai provincial general hospital who also provided the data for our study.

Conflict of interest

The authors have declared that no competing interests exist.

Supplementary material

None.

References

1. Sanchez MR, Golomb FM, Moy JA, et al. Giant lipoma: case report and review of the literature. J Am Acad Dermatol. 1993; 28(2 Pt 1): 266–268, doi: 10.1016/s0190-9622(08)81151-6, indexed in Pubmed: 8432930.
2. Zheng W, Shi M, Li T, et al. Giant bilateral primary scrotal lipoma along with lipomas in multiple sites of the body: a case report and literature review. Transl Androl Urol. 2021; 10(2): 983–990, doi: 10.21037/tau-20-1073, indexed in Pubmed: 33718099.
3. Chen Yu, Li XN, Yi XL, et al. Giant bilateral scrotal lipoma with abnormal somatic fat distribution: A case report. World J Clin Cases. 2022; 10(29): 10803–10810, doi: 10.12998/wjcc.v10.i29.10803, indexed in Pubmed: 36312474.
4. Creta M, De Stefano G, Buonopane R, et al. Giant primary scrotal lipoma: A case report. Arch Ital Urol Androl. 2017; 89(3): 243–244, doi: 10.4081/aiua.2017.3.243, indexed in Pubmed: 28969412.
5. Wolfman DJ, Marko J, Gould CF, et al. Mesenchymal Extratesticular Tumors and Tumorlike Conditions: From the Radiologic Pathology Archives. Radiographics. 2015; 35(7): 1943–1954, doi: 10.1148/rg.2015150179, indexed in Pubmed: 26517315.
6. Kolb L, Yarrarapu SNS, Ameer MA, Rosario-Collazo JA. Lipoma. [Updated 2022 Sep 26]. In: StatPearls [Internet]. StatPearls Publishing, Treasure Island (FL) 2022.
7. World Health Organization. WHO Classification of Tumours of Soft Tissue and Bone. In: Fletcher JBEC, Hogendoorn PCW, Mertens F. ed. WHO Classification of Tumours Vol 5. 2013.
8. Aust MC, Spies M, Kall S, et al. Posttraumatic lipoma: fact or fiction? Skinmed. 2007; 6(6): 266–270, doi: 10.1111/j.1540--9740.2007.06361.x, indexed in Pubmed: 17975353.
9. Ligon AH, Moore SDP, Parisi MA, et al. Constitutional rearrangement of the architectural factor HMGA2: a novel human phenotype including overgrowth and lipomas. Am J Hum Genet. 2005; 76(2): 340–348, doi: 10.1086/427565, indexed in Pubmed: 15593017.
10. Dreux N, Marty M, Chibon F, et al. Value and limitation of immunohistochemical expression of HMGA2 in mesenchymal tumors: about a series of 1052 cases. Mod Pathol. 2010; 23(12): 1657–1666, doi: 10.1038/modpathol.2010.174, indexed in Pubmed: 20834238.
11. Ballas K, Kontoulis Th, Skouras Ch, et al. Unusual findings in inguinal hernia surgery: report of 6 rare cases. Hippokratia. 2009; 13(3): 169–171, indexed in Pubmed: 19918306.
12. Adair FE, Pack GT, Farrior JH. Lipomas. The American Journal of Cancer. 1932; 16(5): 1104–1120.
13. Ali SR, Bryce J, Kodra Y, et al. Recommendations for Improving the Quality of Rare Disease Registries. Int J Environ Res Public Health. 2018; 15(8), doi: 10.3390/ijerph15081644, indexed in Pubmed: 30081484.

Jolanta Dobrzańska, Paweł Potocki, Piotr J. Wysocki

Department of Oncology, Jagiellonian University Medical College, Cracow, Poland
Oncology Clinical Department, The University Hospital, Cracow, Poland

Do solitary pancreatic metastases of renal-cell carcinoma indicate an indolent disease with a strong indication for aggressive local treatment? A case report with literature review

Address for correspondence:
Jolanta Dobrzańska, MD
Department of Oncology,
Jagiellonian University Medical College
ul. Kopernika 50, 31–501 Cracow, Poland
e-mail: jdobrzanska@su.krakow.pl

Oncology in Clinical Practice
DOI: 10.5603/ocp.96762
Copyright © 2024 Via Medica
ISSN 2450–1654
e-ISSN 2450–6478

ABSTRACT

Renal-cell carcinoma (RCC) most often metastasizes to the lungs, liver, and brain. Metastases of RCC to the pancreas are very rare. In the last decade, only a few cases of metachronous metastasis of kidney cancer to the pancreas have been reported in the literature. This article presents a case report of a 75-year-old female patient with a 16-year history of treatment of clear-cell carcinoma of the kidney, in whom pancreatic metastases were detected twice. Renal-cell carcinoma may have an indolent course with late relapse or may show dissemination. It is important to establish new recommendations for long-term follow-up in patients after radical treatment.
Keywords: kidney cancer, metastasis, metastasectomy, pancreas

Oncol Clin Pract 2024; 20, 1: 68–70

Introduction

Renal-cell cancer of clear-cell phenotype (RCC), in the majority of patients (98%), accounts for 3.8% and 2.3% of malignant neoplasms in males and females, respectively. Over the last two decades, there has been a 2% yearly increase in the incidence of RCC [1]. Before the advent of antiangiogenic targeted therapies, median survival of metastatic RCC (mRCC) patients was approximately 10 months. Due to the availability of new generations of antiangiogenic agents and immune checkpoint inhibitors, median overall survival (OS) approaches 47 months [2]. According to the current guidelines, not all RCC patients diagnosed with distant metastases require immediate initiation of systemic treatment and may undergo long-term active surveillance. Additionally, in the case of asymptomatic, oligometastatic disease, local therapeutic approaches (metastasectomy or stereotactic radiotherapy) represent the treatment of choice [3, 4]. Some authors emphasize that complete resection of metastases in mRCC patients in combination with targeted therapy is correlated with longer OS compared to targeted therapy alone [5].

The most common sites of RCC's distant metastases (lungs, bones, liver, and brain) [6] are typical for the majority of other solid tumors. However, one of the unique metastatic sites of RCC is the pancreas. Pancreatic metastases are rare and can be detected in approximately 5% of mRCC patients at the time of systemic treatment initiation [7]. Compared to secondary deposits located in the liver or lungs that are amenable to local treatment, pancreatic metastases represent a significant

Received: 01.08.2023 Accepted: 10.08.2023 Early publication date: 31.08.2023

This article is available in open access under Creative Common Attribution-Non-Commercial-No Derivatives 4.0 International (CC BY-NC-ND 4.0) license, allowing to download articles and share them with others as long as they credit the authors and the publisher, but without permission to change them in any way or use them commercially.

clinical challenge for surgeons and radiation oncologists. Therefore, data on the clinical outcome of local treatment of pancreatic oligometastases in RCC patients is relatively scarce, with a few retrospective reports but without prospective studies.

Renal cancer recurrences after radical treatment may be late. The same is true for pancreatic metastases. Antonelli et al. reported on metachronous metastases to the pancreas that occurred 8–73 months after radical nephrectomy [8]. It should be emphasized that pancreatic metastases of renal cancer are most often oligometastatic. Therefore, aggressive surgery seems to be the best option to maximize the chance of a cure. The time of follow-up in RCC patients after initial surgery of primary tumor is a subject of controversy. According to some researchers, follow-up for over 5 years is ineffective, but on the other hand, the risk of late relapse of RCC may justify long-term follow-up. Therefore, in RCC patients, the benefits of long-term follow-up must be carefully balanced against the financial costs, exposure to radiation and contrast agents, and the psychological stress associated with awaiting results of follow-up tests.

Case report

A 59-year-old female patient with hypertension and mixed hyperlipidemia underwent a right nephrectomy in June 2006. The pathological report indicated Fuhrman II clear-cell RCC at stage T1aNxM0 [according to the 2002 Tumor, Node, Metastasis (TNM) classification]. Seven years later (August 2013), a CT scan showed a suspicious pancreatic lesion. A subsequent PET-CT scan confirmed the presence of a potentially metastatic lesion (20 × 18 mm) located in a distant part of the pancreas. Pancreatic tail resection with splenectomy was performed and histopathological examination revealed RCC metastasis. The patient was left in follow-up without any additional treatment. After another seven years (March 2020), a follow-up CT revealed a new solitary lesion (22 mm) located within the head of the pancreas, which again raised suspicion of RCC metastasis. The lesion was assumed resectable, and in April 2020, the patient underwent pancreatoduodenectomy. Histopathological examination confirmed radical resection of an RCC metastatic lesion (PAX8+ and CaIX+) not presenting signs of vascular invasion or lymph node metastases. The patient recovered quickly but required initiation of insulin therapy due to iatrogenic diabetes. One year later (August 2021), a follow-up CT revealed a solitary, ambiguous 3 mm lesion in segment 3 of the right lung and a subsequent CT (February 2022) detected three additional, ambiguous, small (3 mm) lesions in segments 3 and 9 of the right lung. All pulmonary lesions were considered too small for PET/CT verification. Due to the asymptomatic nature of the lesions, and slow dynamics, the patient was qualified for continuous active observation. Two months later (April 2022), the patient underwent an emergency appendectomy due to intestinal obstruction. The pathological report indicated adenocarcinoma G2 of the appendix (CK7+; CK20+; CDX2+; CL19+; AMACR+ pT4a L1V1 PnI1 R1). Genomic analysis of tumor samples revealed no *KRAS*, *NRAS*, *BRAF* mutations, or microsatellite instable (MSI). Subsequent colonoscopy revealed only a hyperplastic polyp but no other signs of active cancer. On a follow-up CT scan (June 2022), lung lesions remained stable, and no other signs indicating dissemination were detected. In July 2022, the patient underwent a planned right hemicolectomy that revealed lymph node metastases of colon adenocarcinoma (3 out of 12 nodes involved). The patient underwent adjuvant chemotherapy in the form of XELOX regimen (6 months). Follow-up PET/CT performed after chemotherapy (April 2023) confirmed no evidence of dissemination. The patient (ECOG = 0) remains in follow-up, has recovered from surgery and chemotherapy sequelae, and is asymptomatic except for iatrogenic diabetes requiring insulin treatment.

Discussion and conclusions

The course of renal-cell carcinoma is generally unpredictable. Although 85% of recurrences occur within 3 years after resection [9, 10], the disease may sometimes recur even decades after primary treatment [8, 11]. In the case of our patient, distant relapse in the form of pancreatic metastasis occurred 7 years after primary surgical treatment.

The late occurrence of RCC metastases is a well-known and favorable prognostic factor [9, 12]. The pancreas generally represents a rare location of neoplastic dissemination, but up to 5% of pancreatic tumors turn out to be metastatic. The majority of metastatic lesions within the pancreas originate from RCC [9, 10, 13]. In approximately 30% of patients with pancreatic RCC metastases, dissemination is multifocal; however, it is resectable in 80% of cases [13]. The high affinity of RCC cells to the pancreatic parenchyma is confirmed by reports of late metastases, which reappeared only in the residual pancreas [10, 14].

In our patient, the first metastatic lesion in the tail of the pancreas appeared 7 years after radical nephrectomy. Partial pancreatic resection was performed to minimize the adverse effects of pancreatomy, such as secondary diabetes and other metabolic or digestive disorders. The decision to perform pancreatic conserving

surgery benefited the patient since she remained in remission for the next 7 years, with good quality of life and no treatment sequelae.

Studies suggest that in the case of isolated pancreatic metastases, the most appropriate approach is local treatment (partial resection or complete pancreatoduodenectomy), which offers a chance for long-term overall survival or even a cure with 5-year OS ranging from 29 to 35% [7, 9, 14]. Although no randomized studies have been conducted to support the role of metastasectomy in treating oligometastatic RCC, observational studies strongly support this approach. The prognosis of patients after resection of isolated pancreatic RCC metastases is relatively good with the 5-year survival rates ranging from 43% to 75%, while in non-resected patients the 3- and 5-year survival rates are 21% and 0%, respectively [14]. The most important prognostic factor in the case of our patient was the radical resection of the oligometastatic disease because it significantly deferred the need for initiation of systemic treatment which up to now (17 years after primary surgery) has not been started yet. Current Polish guidelines on the treatment of RCC strongly recommend consideration of local treatment in oligometastatic patients and active surveillance in non-resectable mRCC patients not requiring immediate initiation of systemic treatment.

Optimal local treatment of our patient with pancreatic RCC metastases and withholding systemic palliative therapy have not impacted negatively her survival or quality of life. Moreover, a wise therapeutic decision allowed the patient to remain treatment-free and to undergo radical therapy for colon cancer, which required two surgical approaches and adjuvant chemotherapy. Such a complex therapy for another primary cancer would be impossible if the patient were treated simultaneously with palliative systemic treatment for RCC.

Article Information and Declarations

Ethics statement

Article have been conducted according to the principles stated in the Declaration of Helsinki.

Author contributions

J.D.: conception/design, collection and/or assembly of data, data analysis and interpretation, manuscript writing, final approval of manuscript.

P.P.: collection and/or assembly of data, data analysis and interpretation, manuscript writing, final approval of manuscript.

P.J.W.: data analysis and interpretation, manuscript writing, supervision, final approval of manuscript.

Funding

None.

Acknowledgments

We would like to thank the Patients and their Families for their trust and resilience. We also extend our thanks to the dedicated healthcare professionals.

Conflict of interest

The authors declare no conflict of interest.

Supplementary material

None.

References

1. Didkowska J, Wojciechowska U, Michałek I. Nowotwory Złośliwe W Polsce W 2019 Roku (Cancer in Poland in 2019). Krajowy Rejestr Nowotworów 2021.
2. Motzer RJ, Escudier B, McDermott DF, et al. Survival outcomes and independent response assessment with nivolumab plus ipilimumab versus sunitinib in patients with advanced renal cell carcinoma: 42-month follow-up of a randomized phase 3 clinical trial. J Immunother Cancer. 2020; 8(2), doi: 10.1136/jitc-2020-000891, indexed in Pubmed: 32661118.
3. Wysocki P, Chłosta P, Chrzan R, et al. Polish society of clinical oncology and polish urological association guidelines for the diagnosis and treatment of renal cell cancer. Oncology in Clinical Practice. 2021; 16(6): 301–330, doi: 10.5603/ocp.2020.0029.
4. Ljungberg B, Bensalah K, Canfield S, et al. EAU Guidelines on Renal Cell Carcinoma: 2014 Update. European Urology. 2015; 67(5): 913–924, doi: 10.1016/j.eururo.2015.01.005.
5. Li JR, Ou YC, Yang CK, et al. The Impact of Local Intervention Combined with Targeted Therapy on Metastatic Renal Cell Carcinoma. Anticancer Res. 2018; 38(9): 5339–5345, doi: 10.21873/anticanres.12861, indexed in Pubmed: 30194186.
6. Riihimäki M, Thomsen H, Sundquist K, et al. Clinical landscape of cancer metastases. Cancer Med. 2018; 7(11): 5534–5542, doi: 10.1002/cam4.1697, indexed in Pubmed: 30328287.
7. Dudani S, de Velasco G, Wells JC, et al. Evaluation of Clear Cell, Papillary, and Chromophobe Renal Cell Carcinoma Metastasis Sites and Association With Survival. JAMA Netw Open. 2021; 4(1): e2021869, doi: 10.1001/jamanetworkopen.2020.21869, indexed in Pubmed: 33475752.
8. Antonelli A, Arrighi N, Corti S, et al. Surgical treatment of atypical metastasis from renal cell carcinoma (RCC). BJU Int. 2012; 110(11 Pt B): E559–E563, doi: 10.1111/j.1464-410X.2012.11271.x, indexed in Pubmed: 22639956.
9. Ghavamian R, Klein KA, Stephens DH, et al. Renal cell carcinoma metastatic to the pancreas: clinical and radiological features. Mayo Clin Proc. 2000; 75(6): 581–585, doi: 10.4065/75.6.581, indexed in Pubmed: 10852418.
10. Kassabian A, Stein J, Jabbour N, et al. Renal cell carcinoma metastatic to the pancreas: a single-institution series and review of the literature. Urology. 2000; 56(2): 211–215, doi: 10.1016/s0090-4295(00)00639-7, indexed in Pubmed: 10925080.
11. Antonelli A, Cozzoli A, Simeone C, et al. Surgical treatment of adrenal metastasis from renal cell carcinoma: a single-centre experience of 45 patients. BJU Int. 2006; 97(3): 505–508, doi: 10.1111/j.1464-410X.2006.05934.x, indexed in Pubmed: 16469016.
12. Tanis PJ, van der Gaag NA, Busch ORC, et al. Systematic review of pancreatic surgery for metastatic renal cell carcinoma. Br J Surg. 2009; 96(6): 579–592, doi: 10.1002/bjs.6606, indexed in Pubmed: 19434703.
13. Wente MN, Kleeff J, Esposito I, et al. Renal cancer cell metastasis into the pancreas: a single-center experience and overview of the literature. Pancreas. 2005; 30(3): 218–222, doi: 10.1097/01.mpa.0000153337.58105.47, indexed in Pubmed: 15782097.
14. Sellner F, Tykalsky N, De Santis M, et al. Solitary and multiple isolated metastases of clear cell renal carcinoma to the pancreas: an indication for pancreatic surgery. Ann Surg Oncol. 2006; 13(1): 75–85, doi: 10.1245/ASO.2006.03.064, indexed in Pubmed: 16372157.

Maria Rozpłoch-Sapa[1], Patrycja Mrowczyk[1], Łukasz Kwinta[2], Mateusz Łobacz[3], Paweł M. Potocki[2]

[1]Student Research Group, Department of Oncology, Faculty of Medicine, Jagiellonian University Medical College, Kraków, Poland
[2]Department of Oncology, Faculty of Medicine, Jagiellonian University Medical College, Kraków, Poland
[3]Department of Oncology, University Hospital, Kraków, Poland

Low-grade serous ovarian cancer with *BRAF*^{V600E} mutation treated with metronomic chemotherapy — a case report and literature review

Address for correspondence:
Paweł M. Potocki, MD
Department of Oncology,
Faculty of Medicine, Jagiellonian University Medical College
ul. Kopernika 50, 31–501 Cracow, Poland
e-mail: pawel.potocki@uj.edu.pl

Oncology in Clinical Practice
DOI: 10.5603/ocp.96964
Copyright © 2024 Via Medica
ISSN 2450–1654
e-ISSN 2450–6478

ABSTRACT

Introduction. Ovarian cancer (OC) is the leading cause of cancer death worldwide. In Poland, it is the fourth leading cause of death from neoplasms in women. OC is a heterogeneous disease with low-grade cases characterized by a better prognosis, but poor chemosensitivity. Metronomic chemotherapy (MC) may be a beneficial approach.

Case presentation. We present a patient with low-grade serous ovarian cancer (LGSOC) with long-term disease control achieved with MC despite being resistant to standard-dose chemotherapy with paclitaxel and carboplatin. Overall survival (OS) of the patient was 65 months. MC was administered most of the time. The patient was treated with two metronomic regimens: topotecan plus cyclophosphamide and vinorelbine plus methotrexate, both in combination with hormone therapy. The cancer was found to harbor the *BRAF*^{V600E} mutation (v-raf murine sarcoma viral oncogene homolog B1, a valine-to-glutamic acid substitution at position 600), but that did not impact the treatment.

Conclusions. LGSOC has distinct features from high-grade serous ovarian cancer (HGSOC). MC may be a valuable option in LGSOC despite being understudied. The *BRAF*^{V600E} mutation occurs in 2–33% of low-grade serous ovarian tumors. It is a more common finding in LGSOC than in HGSOC. BRAF inhibition in OC may be a new therapeutic option. Some BRAF inhibitors have already been registered for solid tumors with this mutation.

Keywords: *BRAF*^{V600E} mutation, cyclophosphamide, ovarian cancer, low-dose metronomic chemotherapy, low-grade serous ovarian cancer, methotrexate, metronomic chemotherapy, topotecan, vinorelbine

Oncol Clin Pract 2024; 20 1: 71–76

Introduction

Ovarian cancer (OC) accounted for 313 959 new cases and 207 252 deaths worldwide in 2020 [1]. In Poland, the standardized incidence rate is 15 cases per 100 000 inhabitants, making OC the fifth most common cancer in Polish women [2]. The death rate has been declining in European countries [3]. In Polish women, OC is the fourth leading cause of cancer-related deaths [2]. OC is a very heterogeneous neoplasm [4]. Low-grade serous ovarian cancer (LGSOC) constitutes approximately 6% of ovarian neoplasms [5, 6] and has different biological characteristics [4], which results in distinct clinical management [7].

Received: 14.08.2023 Accepted: 17.08.2023 Early publication date: 08.09.2023

This article is available in open access under Creative Common Attribution-Non-Commercial-No Derivatives 4.0 International (CC BY-NC-ND 4.0) license, allowing to download articles and share them with others as long as they credit the authors and the publisher, but without permission to change them in any way or use them commercially.

Metronomic chemotherapy (MC) is an anticancer treatment based on the administration of cytotoxic agents more frequently and in lower doses compared to standard chemotherapy dosing. Metronomic administration uses different mechanisms of long-known chemotherapeutics. It is characterized by less toxicity than standard chemotherapy regimens. It is an option for patients with frailty syndrome and others who would not tolerate higher-dose chemotherapy [8, 9]. MC is especially useful in indolent cancers [10], including some cases of OC.

This case report presents a patient with LGSOC who was successfully treated with MC for several years.

Case report

A 57-year-old female was diagnosed with a borderline tumor (BT) of the left ovary in November 2005. Her family history was non-significant for cancer, and germline *BRCA* (breast cancer) mutations were excluded. The patient underwent hysterectomy and bilateral adnexectomy. No additional treatments were administered at that time.

The patient remained disease-free for a decade. In July 2016, cancer recurred in the pelvis and abdomen. The International Federation of Gynecology and Obstetrics (FIGO) system stage IV was established. The patient underwent an operation, during which cytoreduction was performed. The surgery was not radical due to massive dissemination. Postoperative histopathological examination revealed LGSOC. The histopathological samples from primary surgery were inaccessible; therefore, it was not possible to verify, considering the new criteria, whether the cancer initially diagnosed was, in fact, LGSOC.

In August 2016, adjuvant chemotherapy based on paclitaxel and carboplatin was initiated; chemotherapy was administered at three-week intervals. After 5 cycles, disease progression was diagnosed due to the appearance of a lesion in the vaginal fornix. In December 2016, hormone therapy (HT) with tamoxifen was started, but at that time the status of hormone receptors (HRs) was not determined.

In February 2017, symptoms of intermittent gastrointestinal obstruction developed due to infiltration of the intestinal loop by newly discovered epigastric implants. The level of CA-125 (cancer antigen 125) also increased. It was decided to discontinue tamoxifen and start next-line chemotherapy. Considering the patient's good general condition and lack of cancer symptoms, it was decided, in consultation with the patient, to use MC instead of standard-dose chemotherapy. In the opinion of the attending physician, the selected therapeutic option was optimal to achieve disease control and maintain the patient's high quality of life (QoL).

From February 2017 to June 2018, the patient was treated with oral topotecan in a metronomic manner (1 mg per day for three days and one day off) and cyclophosphamide (50 mg per day). From July 2017, due to episodes of neutropenia, the dose of topotecan was reduced (1 mg every other day). During further treatment, the dose of topotecan had to be increased again due to the increase in CA-125 (1 mg per day for two days and one day off), but it resulted in recurring episodes of leukopenia. The patient reported general weakness and abdominal pain during therapy. The overall tolerance to treatment was good. Radiological evaluation after 3 months of MC showed stable disease.

In May 2018, the status of HRs was determined in the second surgical sample. The expression of the estrogen receptor (ER) was 90%, and there was no expression of the progesterone or androgen receptors. Tamoxifen was added to the treatment due to the positive ER status, but increasing CA-125 levels were found, and it was replaced with letrozole. This combination of MC and HT was maintained until February 2019.

In February 2019, due to cancer progression, topotecan and cyclophosphamide were replaced with another metronomic combination: vinorelbine (50 mg three times a week) and methotrexate (5 mg twice a week). Letrozole was discontinued. Side effects included pain in the abdomen and spine, especially on days of methotrexate administration. In January 2020, tamoxifen was reintroduced. The patient remained in triple treatment (vinorelbine, methotrexate, tamoxifen) until October 2020. In October 2020, tamoxifen was replaced again with letrozole due to biochemical (CA-125) progression.

In December 2020, the patient participated in molecular screening as part of the RAGNAR clinical trial, evaluating erdafitinib therapy in advanced solid tumors with the activating mutation of the presence of the FGFR (fibroblast growth factor receptor) (NCT04083976). The patient was diagnosed with the $BRAF^{V600E}$ mutation, which made her ineligible for this clinical trial.

In April 2021, a decision was made to discontinue vinorelbine, methotrexate, and letrozole due to evident clinical, biochemical, and imaging progression as well as the lack of perspective for further benefit from this treatment. Pegylated liposomal doxorubicin administered at 2-week intervals was introduced. In June 2021 the regimen was intensified by adding oral cyclophosphamide daily. This treatment was terminated in August 2021 due to progression and poor tolerance. Carboplatin and paclitaxel administered at weekly intervals were introduced and maintained for 8 weeks. Meanwhile, an immunohistochemical test was also performed using available paraffin blocks from the second surgery: cancer cells expressed WT1 (Wilms tumor 1) and PAX8 (paired box 8), and the status of HER2 (human epidermal growth factor receptor 2) was negative (1+). The proliferative activity of Ki67 was 12%.

At the turn of October and November 2021, the patient suffered from COVID-19 pneumonitis and was, therefore, hospitalized in the infectious diseases ward. The SARS-CoV-2 infection was complicated by bacterial superinfection. Due to poor general condition, the patient was disqualified from anticancer treatment and refused further diagnostic and therapeutic procedures, except for analgesic treatment. The patient died in the second half of December 2021 at the age of 72, having lived 65 months since the diagnosis of metastatic cancer.

Discussion

This case report is notable for OS of the patient who was treated most of the time with MC. The patient lived for 65 months after the diagnosis of metastatic OC although survival from the first diagnosis was much longer.

There is controversy surrounding the natural history of low-grade and borderline ovarian tumors. Some authors believe that LGSOC is mainly a recurrent BT [7]. The presented case seems to follow this pattern although it must be noted that initial pathological samples were not available for re-verification after recurrence.

The patient's cancer had indolent biology, which partially explains long OS [11]. In the article by Gockley et al. [12], median OS for patients with low-grade stage IV OC was 55.2 months. In a study by di Lorenzo et al. [13], median OS of patients with low-grade OC who received suboptimal cytoreduction was 35.2 months, and the article by Grabowski et al. [14] reported OS of 35.0 months.

At the time of recurrence, the patient underwent cytoreductive surgery, followed by adjuvant chemotherapy with paclitaxel and carboplatin. This treatment is considered standard in this clinical setting [15–17]. However, the patient experienced progression on the first-line regimen. Primary platinum resistance is a recognized negative prognostic factor [18].

High chemoresistance is typical for tumors with a low histopathological grade [19]. In slow-proliferating tumors, cell division occurs less frequently than in tumors with a high proliferation rate. Chemotherapy administered according to the maximum-tolerated-dose paradigm targets mainly cells that are actively dividing and not cells in the G0 phase. This makes slow-proliferating tumors less susceptible to chemotherapy. The use of cytotoxic agents in maximal doses at longer intervals between treatment cycles allows for the regeneration of healthy body cells. In slow-proliferating cancers, the continuous use of lower doses of cytotoxic agents seems to be a more reasonable approach because it inhibits cell division as soon as it occurs [20].

In the case of the presented patient, MC was chosen as an appropriate treatment option for low-grade cancer. MC is defined as the continuous administration of cytotoxic agents in low doses. It differs in effect from standard chemotherapy regimens, in which maximal doses of drugs are used in a short period followed by a break to allow regeneration. Long-term disease control remains a priority in MC [21], while standard chemotherapy intends to obtain an objective response. This divergence in objectives is particularly visible in advanced OC, where MC is administered without interruptions, and standard chemotherapy after achieving remission is discontinued until the next recurrence. In highly differentiated OC, it seems more beneficial to use the cytostatic effect of the metronomic approach than the cytotoxic effect of the maximum dose approach [22]. In addition, antiangiogenic properties as well as immune system stimulation and impact on tumor microenvironment are also emphasized in MC [23]. Given all the potential advantages of MC, there is surprisingly little scientific research on this topic. The available evidence comes mainly from observational studies and the experience of individual cancer centers. The optimal drug combinations for MC remain largely unknown [24], and prospective randomized trials comparing MC with standard chemotherapy in OC are lacking.

The described patient received topotecan and cyclophosphamide as the first metronomic regimen. The only work that addresses this combination is a retrospective analysis by Wysocki et al. [25]. In that study, the objective response rate (ORR) was 27.2%, and the disease control rate (DCR) was 86.3%. Median progression-free survival (PFS) at 3, 6, and 12 months was 57.2%, 26.7%, and 11.3%, respectively, which is comparable to the results achieved by classical fractionation of topotecan. The biochemical response to MC was shown to be the most important predictor of improved PFS. The combination of topotecan and cyclophosphamide was well tolerated. No patient was forced to discontinue treatment due to toxicity. The most common adverse reaction was anemia. In addition to myelotoxicity, hepatic and renal damage (mainly low-grade) was also observed in patients [25]. The presented patient received daily oral topotecan, which is less toxic than when administered intravenously in cycles lasting several weeks despite the similar overall dose [26, 27].

As a second regimen of MC, the patient received methotrexate and vinorelbine; drugs with a different mechanism of action from topotecan and cyclophosphamide administered previously. There are no reports in the literature on the combined use of methotrexate and vinorelbine as MC in OC. However, both drugs are used in a metronomic manner.

Methotrexate has been reported in combination with cyclophosphamide as maintenance MC in advanced OC after achieving a complete response on a platinum-paclitaxel regimen. Compared to the untreated control group, patients receiving this maintenance MC benefitted from 2.5 months longer PFS [28]. The combination of methotrexate and cyclophosphamide as MC has also been described in several other cancers, including advanced breast cancer. The study by Lu et al. showed an ORR of 3.8%, but a DCR of 41.4% [29], which illustrates the mentioned-above clinical effect of MC, which is prioritizing disease control over eradication [30, 31].

In the literature, metronomic dosing vinorelbine is used most often in the treatment of non-small-cell lung cancer (NSCLC) and advanced breast cancer. As a drug that inhibits formation of microtubules and, at higher concentrations, also damages them, vinorelbine inhibits the transport of the ER complex and thus has the potential to be effective in ER-expressing OC, as in the described patient. Metronomic vinorelbine was compared in a phase II randomized trial with the best supportive care in patients with advanced NSCLC. The vinorelbine group had a significantly lower median progression follow-up rate ($p = 0.049$) and 1.5 month longer PFS. OS, ORR, and QoL were not significantly different between the two groups. The high percentage (25%) of discontinuation of treatment due to toxicity (mainly neutropenia) was surprising to researchers [32]. A 2020 meta-analysis evaluating metronomically administered vinorelbine in stage IIIB/IV NSCLC cancer showed an ORR and a DCR of 12% and 48%, respectively. Median PFS was 3.46 months and OS was 8.22 months. The most common serious adverse reaction was neutropenia. The conclusions emphasized that MC is a convenient and cost-effective form of treatment suitable for elderly patients with frailty syndrome [33].

Hormone therapy is not as effective in OC as in "classical" hormone-sensitive neoplasms, such as breast or prostate cancers. The literature indicates that the expression of female HRs in OC is a predictive factor for HT. It should be noted that LGSOC mostly has a high expression of HRs [34]. Randomized trials, which evaluated HT in OC as an alternative to chemotherapy or as a maintenance treatment, have not been positive so far [16]. Letrozole is currently being studied in low-grade ovarian tumors (NCT05601700). Combining HT with MC is justified because both forms of treatment have cytostatic properties, leading to a synergistic effect [35].

The *BRAF* mutation plays an important role in the carcinogenesis of melanoma, colorectal cancer, NSCLC, and other tumors [36]. The *BRAF* gene is a proto-oncogene that encodes a serine-threonine kinase that transmits a signal from the growth factor receptors. The activating mutation in this gene is responsible for strong stimulation of the mitogen-activated protein kinase (MAPK) pathway. This results in increased proliferation and angiogenesis, which are key elements of carcinogenesis. The reported frequency of *BRAF* mutations is highest in melanoma (50% of cases) with a much lower incidence in other malignancies, where it typically coexists with different driver alterations [37, 38]. The mutation rate in LGSOC varies from 2% to 33% [39]. The literature emphasizes that mutations in the MAPK pathway are rarer than in high-grade serous ovarian cancer [40]. Sometimes, paradoxically, it is also associated with a positive prognosis. In LGSOC, mutation has been shown to be associated with early disease diagnosis, no need for chemotherapy treatment, and longer OS [40]. Inhibition of BRAF in low-grade OC has been investigated in several trials. In cohort H of the NCI-MATCH study, sixteen different tumor types harboring the $BRAF^{V600E}$ mutation were treated with a combination of dabrafenib and trametinib. LGSOC was one of the most common histology types (5 cases). Four patients achieved a partial response, and one patient had stable disease [41]. ROAR was a similar study but did not include low-grade serous ovarian tumors [42]. The TAPUR study analyzed six patients with OC treated with a combination of vemurafenib and cobimetinib. Three had an objective response, and one had a complete response [43]. In June 2022, the Food and Drug Administration approved the combination of dabrafenib and trametinib for solid tumors with *BRAF* mutations based on the NCI-MATCH [41] and ROAR [42] studies. This means that if the patient was alive today, she could potentially be treated with dabrafenib and trametinib as tissue-agnostic targeted therapy.

Conclusions

The patient presented achieved satisfactory OS despite platinum resistance. Her 65-month OS exceeded OS medians in LGSOC reported in the literature. MC has promising activity and a manageable toxicity profile. It works well in slowly proliferating and relatively chemoresistant tumors, including LGSOC. MC has a synergistic effect with HT. Both methods could be combined. Metronomic regimens deserve evaluation in prospective trials. Currently, there is little high-quality evidence about MC. $BRAF^{V600E}$ constitutes a new molecular target in OC, especially in low-grade tumors. Some BRAF inhibitors have already been available as tumor-agnostic therapy. They potentially will support chemotherapy, including MC.

Article Information and Declarations

Ethics statement

Article have been conducted according to the principlesstated in the Declaration of Helsinki.

Author contributions

M.R.-S.: methodology, writing — original draft preparation; P.M.: methodology, writing — original draft preparation; Ł.K.: formal analysis, investigation, writing — review & editing; M.Ł.: investigation, writing — review & editing; P.M.P.: conceptualization, methodology, formal analysis, writing — original draft preparation, writing — review & editing, supervision.

Funding

This research received no external funding.

Acknowledgments

We would like to thank the Patient and her Family for their trust and strength; students of the Student Research Group, Oncology Department, Jagiellonian University Medical College for their unfading enthusiasm.

Conflict of interest

The authors declare no conflicts of interest.

Supplementary material

None.

References

1. Sung H, Ferlay J, Siegel RL, et al. Global Cancer Statistics 2020: GLOBOCAN Estimates of Incidence and Mortality Worldwide for 36 Cancers in 185 Countries. CA Cancer J Clin. 2021; 71(3): 209–249, doi: 10.3322/caac.21660, indexed in Pubmed: 33538338.
2. Didkowska J, Wojciechowska U, Olasek P. Nowotwory złośliwe w Polsce w 2019 roku (Cancer in Poland in 2019). Polish National Cancer Registry, Warsaw 2021.
3. Dalmartello M, La Vecchia C, Bertuccio P, et al. European cancer mortality predictions for the year 2022 with focus on ovarian cancer. Ann Oncol. 2022; 33(3): 330–339, doi: 10.1016/j.annonc.2021.12.007, indexed in Pubmed: 35090748.
4. Diaz-Padilla I, Malpica AL, Minig L, et al. Ovarian low-grade serous carcinoma: a comprehensive update. Gynecol Oncol. 2012; 126(2): 279–285, doi: 10.1016/j.ygyno.2012.04.029, indexed in Pubmed: 22555104.
5. Plaxe SC. Epidemiology of low-grade serous ovarian cancer. Am J Obstet Gynecol. 2008; 198(4): 459.e1–8; discussion 459.e8, doi: 10.1016/j.ajog.2008.01.035, indexed in Pubmed: 18395040.
6. Zwimpfer TA, Tal O, Geissler F, et al. Low grade serous ovarian cancer - A rare disease with increasing therapeutic options. Cancer Treat Rev. 2023; 112: 102497, doi: 10.1016/j.ctrv.2022.102497, indexed in Pubmed: 36525716.
7. Kaldawy A, Segev Y, Lavie O, et al. Low-grade serous ovarian cancer: A review. Gynecol Oncol. 2016; 143(2): 433–438, doi: 10.1016/j.ygyno.2016.08.320, indexed in Pubmed: 27581327.
8. Fontana A, Falcone A, Derosa L, et al. Metronomic chemotherapy for metastatic prostate cancer: a ‚young' concept for old patients? Drugs Aging. 2010; 27(9): 689–696, doi: 10.2165/11537480-000000000-00000, indexed in Pubmed: 20809660.
9. Lien K, Georgsdottir S, Sivanathan L, et al. Low-dose metronomic chemotherapy: a systematic literature analysis. Eur J Cancer. 2013; 49(16): 3387–3395, doi: 10.1016/j.ejca.2013.06.038, indexed in Pubmed: 23880474.
10. Montagna E, Cancello G, Bagnardi V, et al. Metronomic chemotherapy combined with bevacizumab and erlotinib in patients with metastatic HER2-negative breast cancer: clinical and biological activity. Clin Breast Cancer. 2012; 12(3): 207–214, doi: 10.1016/j.clbc.2012.03.008, indexed in Pubmed: 22520733.
11. Babaier A, Mal H, Alselwi W, et al. Low-Grade Serous Carcinoma of the Ovary: The Current Status. Diagnostics (Basel). 2022; 12(2), doi: 10.3390/diagnostics12020458, indexed in Pubmed: 35204549.
12. Gockley A, Melamed A, Bregar AJ, et al. Outcomes of Women With High-Grade and Low-Grade Advanced-Stage Serous Epithelial Ovarian Cancer. Obstet Gynecol. 2017; 129(3): 439–447, doi: 10.1097/AOG.0000000000001867, indexed in Pubmed: 28178043.
13. Di Lorenzo P, Conteduca V, Scarpi E, et al. Advanced low grade serous ovarian cancer: A retrospective analysis of surgical and chemotherapeutic management in two high volume oncological centers. Front Oncol. 2022; 12: 970918, doi: 10.3389/fonc.2022.970918, indexed in Pubmed: 36237308.
14. Grabowski JP, Harter P, Heitz F, et al. Operability and chemotherapy responsiveness in advanced low-grade serous ovarian cancer. An analysis of the AGO Study Group metadatabase. Gynecol Oncol. 2016; 140(3): 457–462, doi: 10.1016/j.ygyno.2016.01.022, indexed in Pubmed: 26807488.
15. Ozols RF, Bundy BN, Greer BE, et al. Gynecologic Oncology Group. Phase III trial of carboplatin and paclitaxel compared with cisplatin and paclitaxel in patients with optimally resected stage III ovarian cancer: a Gynecologic Oncology Group study. J Clin Oncol. 2003; 21(17): 3194–3200, doi: 10.1200/JCO.2003.02.153, indexed in Pubmed: 12860964.
16. Colombo N, Sessa C, du Bois A, et al. ESMO-ESGO Ovarian Cancer Consensus Conference Working Group. ESMO-ESGO consensus conference recommendations on ovarian cancer: pathology and molecular biology, early and advanced stages, borderline tumours and recurrent disease†. Ann Oncol. 2019; 30(5): 672–705, doi: 10.1093/annonc/mdz062, indexed in Pubmed: 31046081.
17. Basta A, Bidziński M, Bieńkiewicz A, et al. Recommendations of the Polish Gynecological Oncology Society for the diagnosis and treatment of ovarian cancer. Curr Gynecol Oncol. 2017; 15(1): 5–23, doi: 10.15557/cgo.2017.0001.
18. Kornafel J, Mądry R, Bidziński M. Nowotwory kobiecego układu płciowego. Zalecenia postępowania diagnostyczno-terapeutycznego w nowotworach złośliwych 2013 rok. Polskie Towarzystwo Onkologii Klinicznej, Gdańsk 2013.
19. Gershenson DM, Sun CC, Bodurka D, et al. Recurrent low-grade serous ovarian carcinoma is relatively chemoresistant. Gynecol Oncol. 2009; 114(1): 48–52, doi: 10.1016/j.ygyno.2009.03.001, indexed in Pubmed: 19361839.
20. Wysocki PJ, Lubas MT, Wysocka ML. Metronomic Chemotherapy in Prostate Cancer. J Clin Med. 2022; 11(10), doi: 10.3390/jcm11102853, indexed in Pubmed: 35628979.
21. Montagna E, Pagan E, Cancello G, et al. The prolonged clinical benefit with metronomic chemotherapy (VEX regimen) in metastatic breast cancer patients. Anticancer Drugs. 2022; 33(1): e628–e634, doi: 10.1097/CAD.0000000000001209, indexed in Pubmed: 34407044.
22. Emmenegger U, Chow A, Bocci G. The Biomodulatory Capacities of Low-Dose Metronomic Chemotherapy: Complex Modulation of the Tumor Microenvironment. Springer Netherlands, Dordrecht 2010.
23. Krajnak S, Battista MJ, Hasenburg A, et al. Metronomic Chemotherapy for Metastatic Breast Cancer. Oncol Res Treat. 2022; 45(1-2): 12–17, doi: 10.1159/000520236, indexed in Pubmed: 34794154.
24. Bocci G, Kerbel RS. Pharmacokinetics of metronomic chemotherapy: a neglected but crucial aspect. Nat Rev Clin Oncol. 2016; 13(11): 659–673, doi: 10.1038/nrclinonc.2016.64, indexed in Pubmed: 27184418.
25. Wysocki PJ, Łobacz M, Potocki P, et al. Metronomic Chemotherapy Based on Topotecan or Topotecan and Cyclophosphamide Combination (CyTo) in Advanced, Pretreated Ovarian Cancer. Cancers (Basel). 2023; 15(4), doi: 10.3390/cancers15041067, indexed in Pubmed: 36831410.
26. Gore M, Oza A, Rustin G, et al. A randomised trial of oral versus intravenous topotecan in patients with relapsed epithelial ovarian cancer. Eur J Cancer. 2002; 38(1): 57–63, doi: 10.1016/s0959-8049(01)00188-5, indexed in Pubmed: 11750840.
27. Tillmanns TD, Buller R, Stewart CF, et al. Daily oral topotecan: Utilization of a metronomic dosing schedule to treat recurrent or persistent solid tumors. J Clin Oncol. 2008; 26(15_suppl): 2571–2571, doi: 10.1200/jco.2008.26.15_suppl.2571.
28. El-Husseiny K, Motawei H, Ali MS. Continuous Low-Dose Oral Cyclophosphamide and Methotrexate as Maintenance Therapy in Patients With Advanced Ovarian Carcinoma After Complete Clinical Response to Platinum and Paclitaxel Chemotherapy. Int J Gynecol Cancer. 2016; 26(3): 437–442, doi: 10.1097/IGC.0000000000000647, indexed in Pubmed: 26825824.
29. Lu Q, Lee K, Xu F, et al. Metronomic chemotherapy of cyclophosphamide plus methotrexate for advanced breast cancer: Real-world data analyses and experience of one center. Cancer Commun (Lond). 2020; 40(5): 222–233, doi: 10.1002/cac2.12029, indexed in Pubmed: 32390331.
30. Malik PS, Raina V, André N. Metronomics as maintenance treatment in oncology: time for chemo-switch. Front Oncol. 2014; 4: 76, doi: 10.3389/fonc.2014.00076, indexed in Pubmed: 24782987.

31. Maiti R. Metronomic chemotherapy. J Pharmacol Pharmacother. 2014; 5(3): 186–192, doi: 10.4103/0976-500X.136098, indexed in Pubmed: 25210398.
32. Platania M, Pasini F, Porcu L, et al. Oral maintenance metronomic vinorelbine versus best supportive care in advanced non-small-cell lung cancer after platinum-based chemotherapy: The MA.NI.LA. multicenter, randomized, controlled, phase II trial. Lung Cancer. 2019; 132: 17–23, doi: 10.1016/j.lungcan.2019.04.001, indexed in Pubmed: 31097088.
33. Xu Ke, Liu T, Zhang J, et al. The efficacy and toxicity of metronomic oral vinorelbine monotherapy in patients with non-small cell lung cancer: a meta-analysis. Int J Clin Oncol. 2020; 25(9): 1624–1634, doi: 10.1007/s10147-020-01707-9, indexed in Pubmed: 32472208.
34. Llaurado Fernandez M, Dawson A, Kim H, et al. Hormone receptor expression and outcomes in low-grade serous ovarian carcinoma. Gynecol Oncol. 2020; 157(1): 12–20, doi: 10.1016/j.ygyno.2019.11.029, indexed in Pubmed: 31954537.
35. Licchetta A, Correale P, Migali C, et al. Oral metronomic chemo-hormonal-therapy of metastatic breast cancer with cyclophosphamide and megestrol acetate. J Chemother. 2010; 22(3): 201–204, doi: 10.1179/joc.2010.22.3.201, indexed in Pubmed: 20566427.
36. Pakneshan S, Salajegheh A, Smith RA, et al. Clinicopathological relevance of BRAF mutations in human cancer. Pathology. 2013; 45(4): 346–356, doi: 10.1097/PAT.0b013e328360b61d, indexed in Pubmed: 23594689.
37. Sumimoto H, Imabayashi F, Iwata T, et al. The BRAF-MAPK signaling pathway is essential for cancer-immune evasion in human melanoma cells. J Exp Med. 2006; 203(7): 1651–1656, doi: 10.1084/jem.20051848, indexed in Pubmed: 16801397.
38. Yi Q, Peng J, Xu Z, et al. Spectrum of BRAF Aberrations and Its Potential Clinical Implications: Insights From Integrative Pan-Cancer Analysis. Front Bioeng Biotechnol. 2022; 10: 806851, doi: 10.3389/fbioe.2022.806851, indexed in Pubmed: 35910024.
39. Moujaber T, Etemadmoghadam D, Kennedy CJ, et al. Australian Ovarian Cancer Study. Mutations in Low-Grade Serous Ovarian Cancer and Response to BRAF Inhibition. JCO Precis Oncol. 2018; 2: 1–14, doi: 10.1200/PO.17.00221, indexed in Pubmed: 35135122.
40. Grisham RN, Iyer G, Garg K, et al. BRAF mutation is associated with early stage disease and improved outcome in patients with low-grade serous ovarian cancer. Cancer. 2013; 119(3): 548–554, doi: 10.1002/cncr.27782, indexed in Pubmed: 22930283.
41. Salama AKS, Li S, Macrae ER, et al. Dabrafenib and Trametinib in Patients With Tumors With Mutations: Results of the NCI-MATCH Trial Subprotocol H. J Clin Oncol. 2020; 38(33): 3895–3904, doi: 10.1200/JCO.20.00762, indexed in Pubmed: 32758030.
42. Subbiah V, Kreitman RJ, Wainberg ZA, et al. Dabrafenib plus trametinib in BRAFV600E-mutated rare cancers: the phase 2 ROAR trial. Nat Med. 2023; 29(5): 1103–1112, doi: 10.1038/s41591-023-02321-8, indexed in Pubmed: 37059834.
43. Meric-Bernstam F, Rothe M, Garrett-Mayer E, et al. Cobimetinib plus vemurafenib (C+V) in patients (Pts) with solid tumors with BRAF V600E/d/k/R mutation: Results from the targeted agent and profiling utilization registry (TAPUR) study. J Clin Oncol. 2022; 40(16_suppl): 3008–3008, doi: 10.1200/jco.2022.40.16_suppl.3008.

In the article "Trastuzumab deruxtecan in the treatment of adult patients with HER2-positive breast cancer" (Kufel-Grabowska J. Oncol Clin Pract 2023; 19: 377–381) in page 380:

text provided	should be
Currently, the DESTINY-Breast09 study is ongoing, with previously untreated patients with advanced HER2-positive breast cancer randomly assigned to 3 arms: docetaxel in combination with pertuzumab and trastuzumab, T-DXd in combination with pertuzumab, and T-DXd.	The DESTINY-Breast09 study, which enrolled patients with advanced HER2-positive previously untreated breast cancer, is currently ongoing.

Online version at: https://journals.viamedica.pl/oncology_in_clinical_practice/article/view/97612 is correct.